

Pott's Puffy Tumour: A Rare But Sinister Cause of Periorbital Oedema In A Child

*Dr.Pummy Roy¹, Dr. Uma Shankar Singh², Dr Pankaj kumar³

Corresponding author: *Dr.Pummy Roy1

Introduction: Pott's puffy tumour (PPT), first described by Percival Pott in 1760, refers to a doughy, indolent swelling over the forehead caused by an underlying subperiosteal abscess of the frontal bone. Osteomyelitis of the frontal bone associated with subperiosteal abscess collection is termed Pott's puffy tumour. It typically affects adolescent male subjects with frontal sinusitis and presents to ENT or neurosurgeons. However, we describe an unusual case occurring in a 9-year-old child and presenting with periorbital oedema with frontal sinusitis.

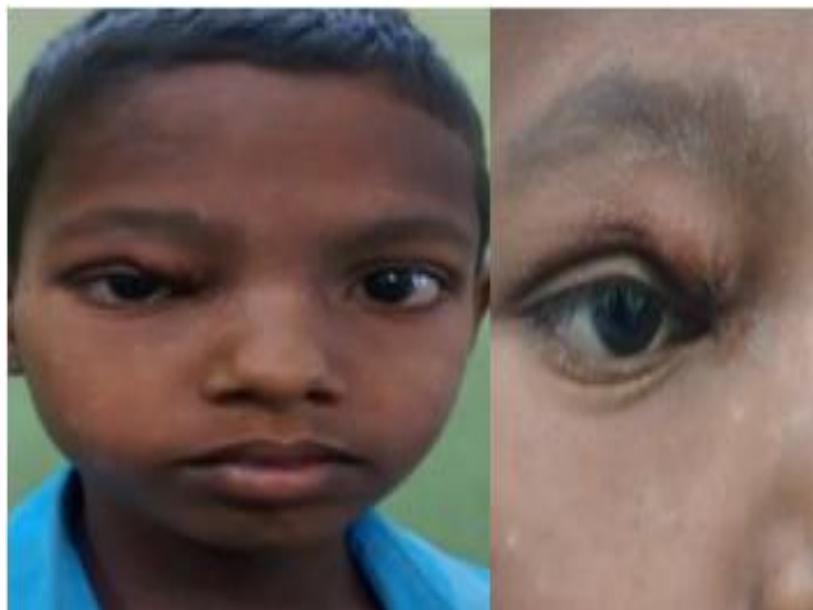Keywords: Pott's puffy tumour, frontal sinusitis, seizure

Date of Submission: 08-11-2017

Date of acceptance: 25-11-2017

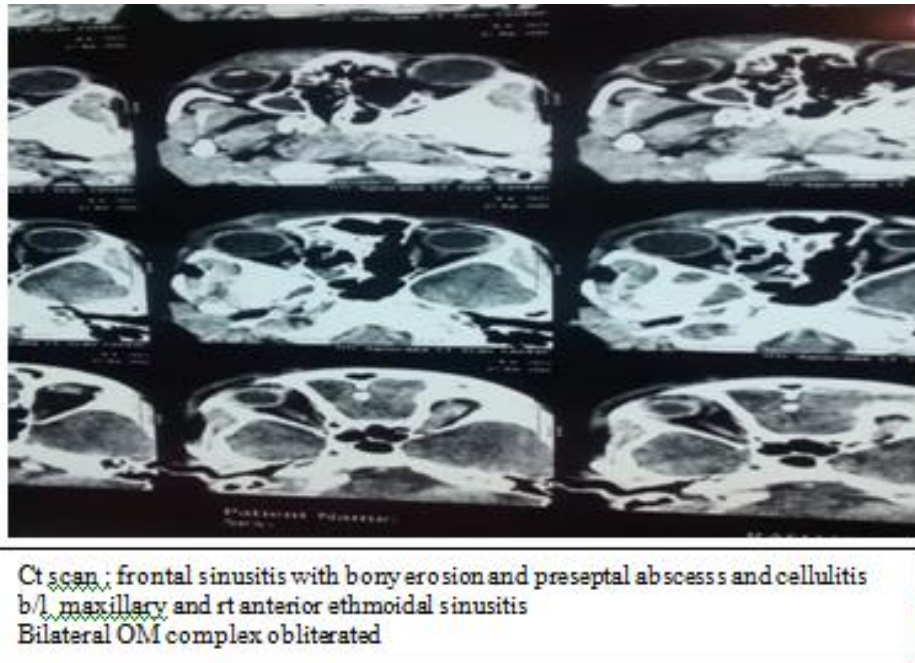
I. Case Report

A 9-year-old boy referred to us with a 3 month history of erythematous, tender, tense swelling of his right upper lid with discharging sinus, partly occluding the eye and extending above the brow medially. There was no history of trauma. This was associated with mild headaches, vomiting, and intermittent pyrexia, for which parents consulted local doctor and treated with a course of broad spectrum antibiotic, the swelling and discharge subside partially. Lastly he consulted neurosurgeon who referred the case to us. On physical examination, temperature was 37.6°C, and there was no pallor. There was a tender, soft to hard swelling (4cm x 4cm) in the right upper lid region with diffuse oedema and erythema involving the lid and suprabrow area. There were no focal neurologic deficits. Other wise right eye exam was normal. left eye examination was unremarkable.



Blood tests revealed a CRP=245, a raised white cell count and a mild hyponatraemia.

An unenhanced orbital/sinus CT confirmed ethmoido-maxillary sinusitis with bony erosion and preseptal abscess and cellulitis but no postseptal orbital involvement.



The patient was taken for exploration along with ENT surgeon. During surgery frontal sinus was opened through suprabrow incision and abscess was drained and a tract was found going down towards the lid over discharging area. With lid crease incision over the sinus the tract was traced till frontal sinus. Sinus was washed thoroughly with betadine and incisions were closed in layer. The patient was kept on parenteral, broad spectrum antibiotics (ceftriaxone 50mg/kg body weight daily, and metronidazole 7.5mg/kg body weight 8hourly) for 7 days then oral antibiotics for 1 month. Post-operative course was uneventful. He was discharged after 5 days. The antibiotics were continued orally for 4 weeks. He has remained well at 2 years of follow up. The pus was sent for c/s. Both aerobic and anaerobic culture of the pus was sterile

II. Discussion

Since 1768 when Percival Pott described Pott's puffy tumor (PPT) a number of cases have been reported in literature. Though uncommon, the advent of antibiotics has not eradicated the disease, but has significantly reduced the incidence of major neurologic complications. It affects all ages from 7 to 83 years, predominantly teenagers. It is noteworthy that children suffer an average of 6 to 8 cold episodes per year, and 0.5% - 5% of these are complicated by sinusitis.³ Thus it is in this age group that major complications of sinusitis become a serious concern.

PPT is thought to arise from the haematogenous spread of septic emboli through the valve less veins of the frontal sinus mucosa to the marrow of the frontal bone. It is associated with intracranial infection, both from direct and indirect spread, and carries significant mortality. Although less common in children due to late development of the frontal sinus, over 25 pediatric cases have nonetheless been reported in the non-ophthalmic literature. These often have occult sinusitis. Periorbital swelling is described in approximately 30% of PPT cases, caused by downward spread of fluid, suggesting that PPT should be considered in the differential of periorbital oedema, especially if extending above the brow PPT may follow trauma, but more commonly, it follows frontal sinusitis as in this patient. Infection extends from the frontal sinus through the frontal bone marrow cavity, causing osteomyelitis of the outer table, eroding it and causing subperiosteal abscess. The infection can also destroy the inner table resulting in an epidural abscess. Although the dura and arachnoid are relatively impermeable protective membranes, the infection can also spread to the subdural space causing subdural empyema or cerebritis,^{3, 4} which manifests with seizure and neurologic deficits.

The most common pathogens implicated in Pott's puffy tumour are non-enterococcal streptococci, staphylococcus, and anaerobes that colonize the upper respiratory tract. Gram-negative organisms are less frequently encountered. Cultures often reveal polymicrobial involvement. When intracranial complications occur, anaerobes such as fusibacterium, bacteroides, and anaerobic streptococci are the predominant pathogens. The presenting symptoms are commonly headache, periorbital swelling with erythema, photophobia, preserved but discomforting ocular motility, and fever.

Diagnosis should be suspected from clinical features of tender, fluctuant swelling over the frontal bone, but neuroimaging should be done to exclude intracranial complications.

Plain and contrast enhanced cranial CT scan is accepted as the most adequate study, but magnetic resonance imaging, technetium-99m scan, and gallium-67 scan are also useful. Radiographic appearance in chronic osteomyelitis is that of a moth eaten appearance avascular necrosis, and presence of radio-opaque sequestra. The abscess should be drained and sequestrectomy of affected bone is important; this may be done endoscopically.

Parenteral broad spectrum antibiotics are required and should be continued (orally) for 4 – 6 weeks to avoid recurrence. Anticonvulsants should be given in patients who have had a seizure and should be maintained for 12 – 18 months to avoid further seizures.

References

- [1]. Feder Jr HM, Cates KL, Cementina AM. Pott puffy tumor: a serious occult infection. *Pediatrics* 1987; **79**: 625–629. | [PubMed](#) |
- [2]. Bambakidis N, Cohen A. Intracranial complications of frontal sinusitis in children: Pott's puffy tumor revisited. *Pediatr Neurosurg* 2001; **35**: 82–89. |
- [3]. Gupta M, El-Hakim H, Bhargava R, Mehta V. Pott's puffy tumour in a pre-adolescent child: the youngest reported in the post-antibiotic era. *Int J Pediatr Otorhinolaryngol.* 2004; **68**(3): 373–378.
- [4]. Babu RP, Todor R, Kasoff SS. Pott's puffy tumour, the forgotten entity. Case report. *J Neurosurg.* 1996;84:110-112.
- [5]. Bagdatoglu C, Güleriyüz A, Ersöz G, Talas DÜ, Kandemir Ö, Köksel T. A Rare Clinical Entity: Pott's Puffy Tumor. *Pediatr Neurosurg.* 2001; 34:156-158. Doi:10.1159/000056011.
- [6]. Pender ES. Pott's puffy tumour: a complication of frontal sinusitis. *Pediatr Emerg Care.* 1990; 6:280-284.
- [7]. Khan MA. Pott's puffy tumor: a rare complication of mastoiditis. *Pediatr Neurosurg.* 2006; 42:125-128. Doi:10.1159/000090469.
- [8]. Verbon A, Husni RN, Gordon SM, Lavertu P, Keys TF. Pott's puffy tumor due to *Haemophilus influenzae*: case report and review. *Clin Infect Dis.* 1996;23:1305-1307.
- [9]. Wells RG, Landers AD. Radiologic evaluation of Pott's puffy tumour. *JAMA.* 1986; 255:1331-1333.
- [10]. Flamm ES. Percival Pott: an 18th century neurosurgeon. *J Neurosurg.* 1992;76:319-326.
- [11]. El-Silimy O. Combined endonasal and percutaneous endoscopic approach to Pott's puffy tumour. *Rhinology.* 1996;34:119-122.
- [12]. Adame N, Hedlund G, Byington C. Sinogenic intracranial Empyema in Children. *Pediatrics* 2005; **116**: 461–467.
- [13]. Younis RT, Anand VK, Davidson B. The role of computed tomography and magnetic resonance imaging in patients with sinusitis with complications. *Laryngoscope.* 2002; **112**(2): 224–229.

*Dr. Pummy Roy. "Pott's Puffy Tumour: A Rare But Sinister Cause of Periorbital Oedema In A Child." *IOSR Journal of Dental and Medical Sciences (IOSR-JDMS)* 16.11 (2017): 31-33