

## Can Early Medical Intervention Reduce the Patho-Physiological Complications Due to Foreign Bodies Impacted In Aerodigestive Tract? - A Prospective Clinical Study

Dr. P. Shimpi<sup>1</sup>, Dr. H. Sonawane<sup>2</sup>, \*Dr. A. Khare<sup>3</sup>

<sup>1</sup>(Assistant Professor, Physiology, Grant Govt. Medical College, Mumbai, India)

<sup>2</sup>(ENT Surgeon)

<sup>3</sup>(Assistant Professor, Physiology, B.J. Govt. Medical College, Pune, India)

Corresponding Author: \*Dr. A. Khare

### Abstract:

**Background:** The occurrence of foreign bodies in air and food passages is an emerging problem both in adults & children. It has got a lot of significance as such accidents continue to take formidable toll of lives every year. To manage and prevent this critical problem an appropriate survey of cases is necessary. Hence this study is taken up to highlight age incidence, sex relation, type and site of foreign body, clinical features, radiological findings, complications and management strategies used in patients of foreign body ingestion and inhalation.

**Methods:** A prospective clinical study of 50 cases of foreign bodies in aerodigestive tract was taken up over a period of one and half year. Careful history was taken from each patient. Appropriate examinations and radiological evaluation were performed. Details regarding age incidence of foreign bodies, sex relation, type and site of foreign bodies, clinical presentation, various investigations, modes of treatment given, post-operative complications were noted.

**Results:** Most patients were children below 10 years of age, males being more common. Coins and peanuts are commonest foreign bodies observed. The most frequent site of lodgement of a foreign body in the food passage was cricopharynx (34%) while in the air passage it was nose. Radiological investigations and rigid endoscopy proved to be valuable. Associated complications vanished off after removal of foreign body.

**Conclusions:** Early diagnosis, efficient and prompt treatment in all cases is mandatory, which will reduce the severity and number of complications drastically.

**Keywords:** Foreign Body, Aerodigestive tract

Date of Submission: 06-11-2017

Date of acceptance: 14-11-2017

### I. Introduction

The occurrence of foreign bodies in air and food passages is an emerging problem both in adults & children. They are mostly accidental. It has got lot of significance, as such accidents continue to take formidable toll of lives every year.<sup>[1,2]</sup> Because of the danger of complications, they have to be attended as emergencies.

Endoscopic removal of the foreign body under direct visualization of the concerned tract is the mainstay of treatment and cannot be substituted by any other method or modality of examination.<sup>[3]</sup> Modern techniques of endoscopic removal of bronchial foreign bodies developed from the advances made in the early part of 20<sup>th</sup> century by Chevalier Jackson, who reduced the mortality of removal of foreign bodies from 20% to approximately 2%. He achieved a 98% success rate for bronchoscopic removal of foreign bodies. Since then, improvement in the illumination coupled with advances in anaesthesia, have further reduced the mortality and greatly facilitated the task of endoscopist.<sup>[4]</sup> Development of fiberoptic flexible laryngobronchoscopes and oesophagoscopes, today permit removal of some of these foreign bodies under local anaesthesia as well.

The problem of dealing with its complications, also have been simplified with the advent of modern anaesthesia and illumination sources. Majority of the complications that occur due to foreign bodies in the aerodigestive tract are prevented by quick approach to the patient, efficient diagnosis by radiology, endoscopic techniques and proper antibiotic therapy.

To manage and prevent this critical problem an appropriate survey of cases such as prevalence rates, types of foreign bodies, demographic factors, complications etc is necessary. The gravity of the situation calls for extensive work and hence this study is taken up to highlight age incidence, sex relation, type and site of foreign body, clinical features, radiological findings, complications and management strategies used in patients of foreign body ingestion and inhalation

## II. Material And Methods

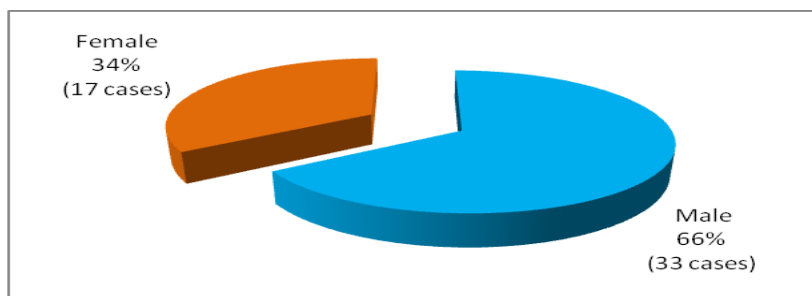
A prospective clinical study of cases of foreign bodies in aerodigestive tract was taken up over a period of one and half year. The study was approved by institutional ethics committee. 50 patients with foreign bodies in aerodigestive tract were included in the present study. Careful history was taken from each patient. Appropriate examinations were performed concerning the nose, oral cavity, pharynx and larynx, using a tongue depressor, nasal speculum, indirect laryngoscope or a flexible laryngoscope. Appropriate radiologic evaluation was performed including X-rays of neck, chest, abdomen (antero-posterior & lateral views) and CT scans were performed if needed. Details regarding age incidence of foreign bodies, sex relation, nature (type) of foreign bodies, site of lodgment, clinical presentation, various investigations, modes of treatment given and post-operative complications were noted. Patients whose foreign bodies were easily and safely removed were returned home with an uneventful post-procedure course on the same day & those who needed hospitalisation, were followed up from time to time till discharge to assess the improvement.

## III. Results

It was observed, that no age group was spared; youngest patient being 6 months old and the oldest being 65 years old. However, most patients were children below 10 years. In adults they were more common in age group of 31- 40 years. (Table 1)

**Table 1:** Age Incidence of Foreign bodies

Age in years	No.	%
Infants--10	28	56
11--20	6	12
21--30	4	8
31--40	5	10
41--50	3	6
51--60	2	4
61--70	2	4



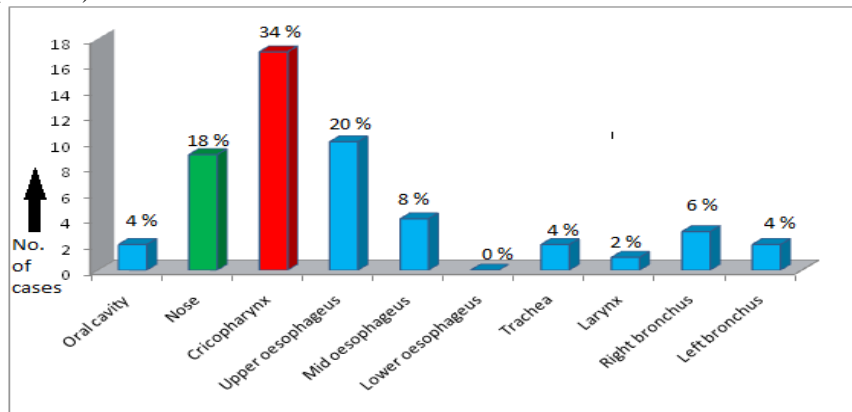
**Figure 1:** Sex relation of foreign bodies

In this study, males were seen to be more affected than females. Males comprised 66% of the total study group i.e. 33 patients; while the females contributed to 34% of the total study group i.e. 17 patients. A male: female ratio of 1.9:1 was noted. (Fig. 1)

**Table 2:** Nature (type) of foreign body

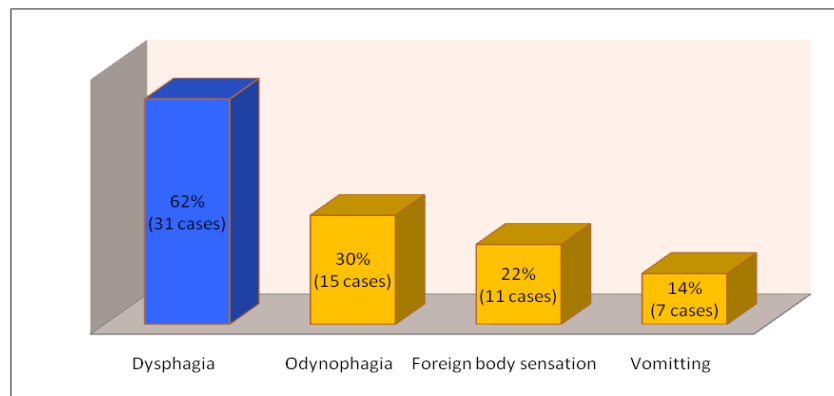
Nature/Type	No.	%
Coin	14	28
Chicken /Mutton bone	6	12
Fish bone	3	6
Peanuts	4	8
Dentures	3	6
Nails/Toy articles/battery	10	20
Others	10	20

Coins were the commonest foreign body in food passage (28%) and others (20%) were the commonest in air passage. (Table 2)



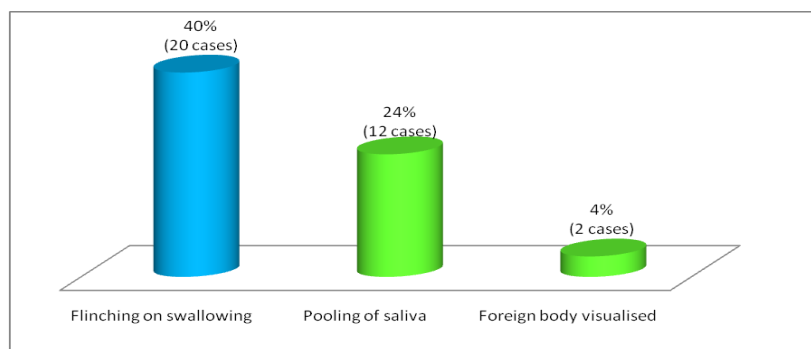
**Figure 2:** Site of lodgment

The most frequent site of lodgment of a foreign body in the food passage was cricopharynx (34%), while in the air passage it was nose (18%).(Fig. 2)



**Figure 3:** Symptoms of a foreign body in the food passages

In the food passages the most frequently observed symptom was dysphagia (62%) followed by odynophagia (30%) and Vomiting (14%). (Fig. 3) The most common sign was flinching on swallowing (40%) followed by pooling of saliva (24%). (Fig. 4)



**Figure 4:** Signs of a foreign body in the food passages

In the air passages the most frequently observed symptom was cough (14%) followed by dyspnoea (12%) and wheeze (12%). (Fig. 5) The most common sign was decreased air entry (10%). (Fig. 6) In our study of 50 cases, 48 patients were radiologically investigated. Of them, 36 (72%) cases showed evidence of foreign body, while in 12 (24%) cases foreign body could not be visualised. In 2 patients of foreign body in nose, the x-ray was performed after removal of foreign body. (Table 3)

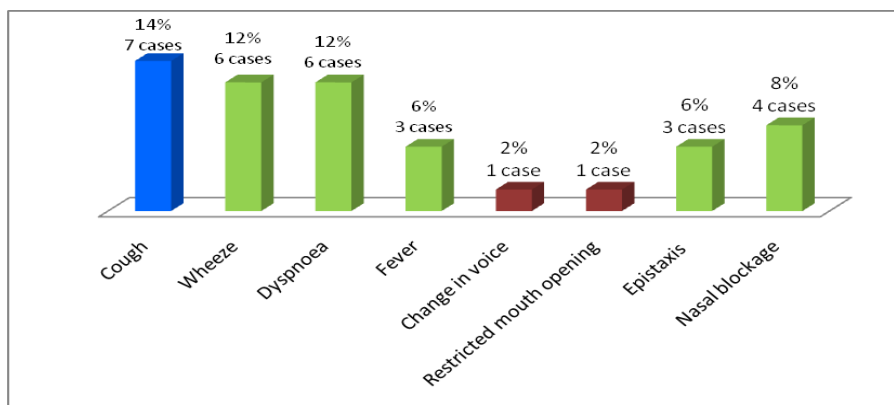


Figure 5: Symptoms of a foreign body in the air passage

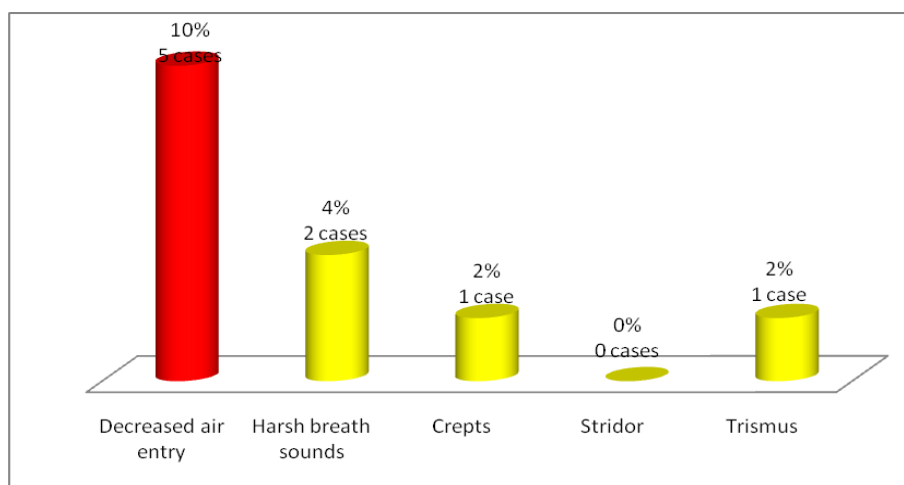


Figure 6: Signs of a foreign body in the air passage

Table 3: Radiological evaluation

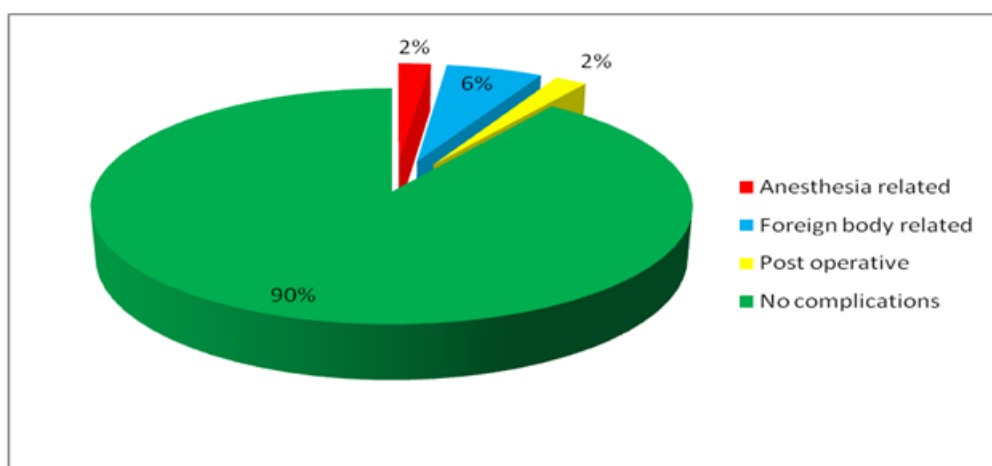
Parameter	No.	%
No. of cases radiologically evaluated	48	96
Plain x-ray soft tissue neck	36	72
Plain x-ray chest	41	82
Plain x-ray abdomen	31	62
X-ray PNS	7	14
CT-Neck	3	6
X-ray positive	36	72
X-ray negative	12	24

In our study, 36 patients underwent rigid endoscopy and removal of the foreign body with forceps under general anaesthesia. For one case of foreign body in larynx, tracheostomy was first performed and then the foreign body was removed by direct laryngoscopy. In one patient with dentures in oesophagus, the foreign body was broken down purposefully into two pieces, as en-block removal was not possible. All the foreign bodies in the oesophagus were removed by appropriate sized oesophagoscope and forceps.

For removal of foreign bodies in the bronchus, rigid ventilating bronchoscopes and forceps of various sizes were used under general anaesthesia. Removal of foreign bodies was easy. Some foreign bodies in the nose were removed on out-patient basis, while the remainder required removal under general anaesthesia with direct visualization with rigid Hopkins' endoscopes. Patients were advised a course of antibiotics, analgesics and anti-inflammatory drugs. Course of steroids was given where ever necessary. Patients were discharged after successful removal of foreign body, and after the effects of anaesthesia wore off (whenever applicable), with an advice to come for follow up after 7 to 10 days. In our study, 16% patients underwent bronchoscopy, while cricopharyngoscopy and oesophagoscopy were performed in 42% and 14% of patients respectively. (Table 4)

**Table 4:** Various management procedures performed in 50 cases under study

Procedure	No.	%
Oesophagoscopy	8	16
Cricopharyngoscopy	21	42
Bronchoscopy	7	14
Endoscopic removal of FB	6	12
OPD procedure	4	8
Other	4	8



**Figure 7:** Percentage of different complications as compared to uncomplicated cases.

There were five cases in which complications occurred. One was anaesthetic complication, one was post operative complication due to mucous plug, three were due to long standing nature of foreign body i.e. para-oesophageal abscess with oesophageal perforation, left lower lobe pneumonia and septal perforation. A child with a battery in right nostril suffered from intraoperative pulmonary oedema after foreign body removal, which was resolved after adequate medications. Another one year old child with cashew nut in trachea developed right upper lobe collapse, after removal of foreign body from trachea. This was probably due to mucus plug, which resolved completely after 24 hours. One female with history of fish bone ingestion 8 days back was referred to us from a private hospital. Emergency CT scan of the neck and thoracic region was done, which was suggestive of oesophageal perforation with para-oesophageal abscess formation. The fish bone was removed by oesophagoscopy and Ryle's tube was inserted and patient was kept nil by mouth for three days to prevent any gastric regurgitation. Feeding was started on fourth day after general surgery consultation. Ryle's tube was removed after 2 weeks. A 2 month child was presented to us with history of cough, fever and dyspnoea had left lower lobe pneumonia due to peanut in left bronchus, which was resolved after removal of foreign body. One child presented with a history of nasal blockage and a mass in the left nostril since one and half month. Nasal endoscopy was suggestive of foreign body (lithium battery) embedded in the nasal septum with septal perforation. (Fig. 7)

#### IV. Discussion

Patients with foreign bodies in the aerodigestive tract are an integral part of clinical practice. At best, foreign body accidents can be minimized, but they cannot be eradicated. The accident and its implications are unique to each patient and present a challenge to the otolaryngologist. If timely intervention and proper treatment are not instituted, each case may prove to be fatal. The earliest studies emphasize that the problem is prevalent among the young and elderly.<sup>[5]</sup> However, review of the latest literature points to the fact that, there appear to be some changes in the overall age composition of the people affected by foreign bodies. Present study shows that the problem affects children below 10 years more predominantly i.e. 28 (56%) patients. The most common age group in adults is 31-40 years, which comprises of 5 (10%) cases. This correlates with immaturity in children below 10 years, and busy life schedules in the 31-40 years age group people. The study performed by Hung et al<sup>[6]</sup> of 70 cases of foreign bodies in air and food passages showed 29 patients (41%) were below the 10 years of age and 7 patients (14%) were belonging to age group of 31-40 years.

In the study, males were seen to be more affected than females. The males comprised 66% of the total study group i.e. 33 patients while the females comprised 34% of the total study group i.e. 17 patients. A male: female ratio of 1.9:1 was noted in the study. A similar study performed by Hung et al<sup>6</sup> showed a sex ratio of

1.3:1, i.e. 40 males and 30 females (n = 70). In our series, organic foreign bodies constituted 32% (nuts, seeds, fish bone, chicken and mutton bone) and inorganic foreign bodies 68% of the total (coins, batteries, pearls, dentures, metal wires). In children coins, peanuts, pearls, buttons and batteries were frequent foreign bodies, while in adults chicken bones, fish bones, dentures and coins are common foreign bodies.

In contrast to other studies, where ingested bones were found to be the predominant foreign body, in our study, the highest incidence belongs to coins. In a review of 2394 cases of foreign bodies in the oesophagus by Nandi P and Ong GB,<sup>[7]</sup> 1825 were fish bones and chicken bones, while coins were 138 in number. Peanuts (8%) were the commonest inhaled foreign bodies, while coins (28%) were commonest swallowed foreign bodies. Yadav SPS et al<sup>[8]</sup>, in their study of 132 cases observed that peanut is the commonest foreign body in airways in children. This must be because of easy availability of peanuts and coins. It has been observed that in most of the patients, carelessness while feeding or eating food is the commonest cause for foreign body aspiration or ingestion. In children it is usually due to accidental aspiration, when objects are kept into the mouth playfully.<sup>[9]</sup> Hence, parents should be educated about not to give nuts to small children who cannot grind them into smaller pieces. Also, parents should keep close watch on objects with which children are playing. Due to smaller airways in children, cough reflex is poorly developed leading to high morbidity and mortality.<sup>[10]</sup>

In 90% of the cases, a positive history of aspiration was obtained. In most cases of inhaled foreign bodies, there was a definite history of paroxysmal coughing and in cases of ingestion, there was history of dysphagia. A triad of symptoms i.e. coughing, dyspnoea and wheeze was present in 40% of the patients with foreign body aspiration. Acute respiratory distress was fortunately an uncommon but most alarming presentation of inhaled foreign body. If there is a sudden change in the child's cry, i.e. cry becomes hoarse or stridorous, a laryngeal foreign body should be suspected. A unilateral expiratory wheeze or reduced air entry may indicate a foreign body in bronchus. If the foreign body is of vegetable origin, an intense inflammatory reaction of the bronchial mucosa occurs, ultimately with the production of granulation tissue. The presence of florid granulation tissue around the inhaled foreign body may produce hemoptysis. If the foreign body impaction occurs at the hypopharynx, patients usually presented with difficulty during swallowing. Children are usually brought with refusal of feeds and with dribbling of saliva. If the foreign body is in the oesophagus and does not completely fill the lumen, there may only be a dysphagia for solids. In case of foreign body in the nose, patients usually present with unilateral nasal obstruction and blood stained nasal discharge. Similar findings were observed in our study. A study conducted by Kamath P et al<sup>[11]</sup> showed that ronchi and dyspnoea are the common symptoms seen in tracheobronchial foreign bodies, while dysphagia is the common symptom seen in foreign bodies in the food passages.

X-ray examination of aerodigestive tract is an important investigation in the detection of foreign bodies. Anteroposterior and lateral views of chest in expiration and inspiration should be obtained. Computerised tomographic studies may help to show a foreign body not seen with conventional studies. Today, virtual bronchoscopy is available for high risk patients where foreign body is suspected in the airways.

In our study, 36 (72%) patients had positive radiological evidence of foreign bodies, while it was negative in 12 (24%) cases. Kamath P et al<sup>[11]</sup> observed x-ray positivity of 81.2% cases, while they were negative in 10% of cases. In our study, 4 (50%) cases having foreign bodies in tracheobronchial tree, the diagnosis was evident by radiological changes secondary to the obstructive changes produced by foreign body. Although radiographs may not confirm or rule out the presence of foreign body, the advantages of finding one on a radiograph far outweigh the disadvantages of missing one. They also give information regarding the condition of the cervical spine for rigid endoscopy.

In our study, in 1 case, foreign body (coin) was impacted in the larynx. Two cases of foreign bodies were encountered in the trachea, while 8 (16%) cases were encountered in the tracheobronchial tree. Of these 8 cases, 37% cases of foreign bodies were found in the right main bronchus and 25% in the left main bronchus. 9 (18%) out of 50 foreign bodies were lodged in the nose. In the study by Kim et al<sup>[12]</sup> of 202 cases of foreign bodies in the airway, 99 (50%) were in right main bronchus and 63 (32%) were in left main bronchus. This is because of anatomical peculiarity of right main bronchus which is more direct extension of trachea, has wider diameter and is shorter in length.

17 (34%) cases, out of 50 cases were encountered in cricopharynx, the most common site in the food passage in our study. Since, cricopharynx is the narrowest part of food passage and relatively weak peristalsis in the upper oesophagus makes this site especially vulnerable. In the study by Kamath P<sup>[11]</sup>, Nandi P and Ong GB<sup>[7]</sup> majority of foreign bodies were encountered in cervical oesophagus. Impacted foreign bodies in the nasal cavities, especially nearer to the choana were best removed under general anaesthesia. Foreign bodies like fish bones, which are usually impacted in the tonsil and at the base of tongue, were removed under good illumination. 2 (4%) of the oesophageal foreign bodies were found to be in the stomach, by the time we could take the patient for foreign body removal. One of them was referred to general surgery and other to gastro-enteric medicine speciality for endoscopic removal. Foreign bodies in the tracheobronchial tree were removed with rigid bronchoscope. The size of bronchoscope was chosen depending upon the age of the patient. After

removing the foreign body, the entire tracheobronchial tree was re-examined for any remains of foreign body or another foreign body. For one foreign body in larynx (coin), tracheostomy was first performed and then foreign body was retrieved by direct laryngoscopy.

Foreign bodies in the oesophagus were removed under general anaesthesia. For removal of sharp objects, utmost care was taken to prevent injury to mucosa of oesophagus. Large foreign bodies like denture in one case, have to be removed by breaking it into two pieces. All the cases in our study were managed with rigid endoscopy and forceps removal, except those in the tonsil and one which was impacted in cleft palate. Study by Kamath P et al<sup>11</sup> showed that rigid scopes are preferable for removal of foreign bodies in aerodigestive tract. Most authors recommend the same modality of treatment.<sup>[13,14]</sup>

In the present study, all the complications were resolved after removal of foreign body. Because of the risk of complications like formation of abscess, perforations & necrosis of blood vessels, respiratory distress, they have to be attended as emergencies. Thus to conclude, early diagnosis, efficient and prompt treatment in all cases is mandatory, which will reduce the severity and number of complications drastically.

### References

- [1]. Biswas B, Datta R. Retained oesophageal foreign bodies — report of three cases. *Indian J Otolaryngol Head Neck Surg.* 1999;51(Suppl 1):15–18.
- [2]. Murty PSN, Ingle VS, Ramakrishna S, Shah FA, Varghese P. Foreign bodies in the upper aero-digestive tract. *J Sci Res Med Sci.* 2001; 3(2): 117–120.
- [3]. Evans JNG: Foreign Bodies in the Larynx and Trachea. In: Scott Brown's Otolaryngology. Vol. 6. 6<sup>th</sup> Ed., 1997:438-48.
- [4]. Kaur K, Sonkhya N, Bapna AS. Foreign bodies in the tracheobronchial tree: A prospective study of fifty cases. *Indian Journal of Otolaryngology and Head and Neck Surgery.* 2002;54(1):30–34.
- [5]. Ikenberry SO, Jue TL, Anderson MA, Appalaneni V, Banerjee S, Menachem TB et al. Management of ingested foreign bodied and food impactions. *Gastrointest Endosc* 2011;73(6):1085-91.
- [6]. Hung W, Lin P. Foreign Bodies in the Air and Food Passages. *Archives of Otolaryngology.* 1953;63:603-612.
- [7]. Nandi P, Ong GB. Foreign Bodies in the Oesophagus: Review of 2394 cases. *British Journal of Surgery.* 1979;65:5-9.
- [8]. Yadav SPS, Singh J, Aggarwal N, Goel A. Airway foreign bodies in children: experience of 132 case. *Singapore Med J* 2007;48(9):850-853.
- [9]. Jackson C. Foreign Bodies in the Food and Air Passages. Jackson C., Jackson C.L., Editors: In diseases of the nose, throat and ear, 2nd edition, 1959: 842-855.
- [10]. Sersar SI, Rizk WH, Bilal M, El Diasty MM, Eltantawy TA, Addelhakam BB et al. Inhaled foreign bodies: presentation, management and value of history and plain chest radiography in delayed presentation. *Otolaryngol Head Neck Surg* 2006;134:92-99.
- [11]. Kamath P, Bhojwani KM, Prasannaraj T, Abhijith K. Foreign bodies in the aerodigestive tract – a clinical study of cases in the coastal belt of South India. *Am J Otolaryngol.* 2006;27(6):373-377.
- [12]. Kim IG, Brummitt WM, Humphry A et al: Foreign Bodies in the Airway - A Review of 202 cases. *Laryngoscope.* 1973;83:347-354.
- [13]. Hsu W, Sheen TS, Lin C, Tan C, Yeh T, Lee S. Clinical experiences of removing foreign bodies in the airway and esophagus with a rigid endoscope: a series of 3217 cases from 1970 to 1996. *Otolaryngol Head Neck Surg.* 2000;122(3):450-454.
- [14]. Ozguner IF, Buyukyavuz BI, Savas C, Yavuz MS, Okutan H. Clinical experience of removing aerodigestive tract foreign bodies with rigid endoscopy in children. *Pediatr Emerg Care.* 2004;20(10):671-673.

\*Dr. A. Khare. "Can Early Medical Intervention Reduce the Patho-Physiological Complications Due to Foreign Bodies Impacted In Aerodigestive Tract? - A Prospective Clinical Study." *IOSR Journal of Dental and Medical Sciences (IOSR-JDMS)* 16.11 (2017): 56-62