

Study of Pathological Lesions in Liver Autopsy

Dr. Venu anand¹, *Dr.S.Selvi²

¹(Associate Professor, Department of Pathology, Govt.Royapettah Hospital, Kilpauk Medical College, Chennai, Tamilnadu Dr. MGR Medical University)

²(Assistant Professor, Department of Pathology, Govt.Royapettah Hospital, Kilpauk Medical College, Chennai, Tamilnadu Dr. MGR Medical University)

*Corresponding Author : Dr.S.SELVI

Abstract: Liver is a site for plethora of disease among which many become symptomatic. However, some are diagnosed only on autopsy examination. Our aim is to correlate gross and histopathological examination of 109 liver autopsy specimens.

Method: 109 cases of liver autopsy specimens who died of various causes like poisoning, drowning, road/railway accidents, burns etc, with no medical history during the period from Jan 2016 to Dec 2016 were taken for the study. Children below one year was not included in the study. Sections from the liver were submitted for processing and then stained with Hematoxyline and Eosin.

Results: The most common pathology found in our study was Fatty change 39.5% followed by Normal histology of liver 26.6%, Chronic venous congestion 15.6%, Hepatitis 4.6%, Cirrhosis 2.8%, Hepatocellular carcinoma 0.9%, Hemangioma 0.9% and 10 cases (9.1%) with marked Autolytic changes.

Conclusion: Autopsy examination of liver is a major tool to identify silent liver diseases such as Fatty change, Chronic venous congestion, Cirrhosis, Hemangioma and Malignant tumors.

Keywords: Liver autopsy, Fatty change, Hepatocellular carcinoma.

Date of Submission: 25 -11-2017

Date of acceptance: 25-11-2017

I. Introduction

Autopsy provides information about the cause of death and also the individuals health status during the life. Liver is the principle site of many metabolic activities and it is most vulnerable for a wide variety of insults, for example metabolic, toxic and microbial etc. The major primary diseases are hepatitis, alcoholic liver diseases, circulatory disturbances and neoplasm. The main purpose of this study is to interpret different patterns of liver diseases [1] in autopsy and to correlate gross and histopathological examination of autopsy liver specimen.

II. Materials And Methods

Our study is Retrospective study of one year period from Jan 2016 to Dec 2016 of 109 liver autopsy specimens, received in department of pathology, Government Royapettah hospital, Kilpauk Medical College, Chennai. Specimens were examined grossly. Sections from representative area were submitted for processing. After processing tissues were sectioned and stained with hematoxyline and Eosin stain. Our department receives postmortem specimens from poisoning, drowning, road/railway accidents, burns etc. Specimen of children less than one year were not included in the study. 10 cases showed features of marked autolytic changes.

III. Results

Out of 109 cases studied, males were most common with 89 cases (81.7%), females were 20 cases (18.3%). Liver weighed between 1500 to 2500gm [2] were common with 52 cases. [Table 1] Maximum number of liver autopsy specimens in male is seen between 21 to 30yrs (30.3%) and female between 31to 4yrs (25.7%). [Table 2] Most common pathological findings was Fatty liver [3] in 43 cases (39.5%) of which males were 37 and females with 6 cases, followed by 29 cases with Normal histology (26.6%), with males 24 cases and females 5 cases, Chronic venous congestion of 17 cases (15.6%) with males 12 cases and females 5 cases, 5 cases of Hepatitis (4.6%) with 4 males and one female case, 3 cases of Cirrhosis in males (2.8%), one case (0.9%) were seen in Hemangioma and Hepatocellular carcinoma [4] in males and 10 cases (9.1%) with marked autolytic changes seen in 7 males and 3 females. [Table 3]

IV. Discussion

Postmortem examination dates back to nearly third century BC and is being performed till date for various reasons and is also one of the best tools to validate clinical diagnosis. Bauer and Robbins have suggested that there exists a discrepancy between the clinical diagnosis and anatomical findings, all of which cumulatively suggest the indispensable nature of autopsy to clarify the clinical diagnosis to help in better disease detection and hence in treatment of the cases that follow.

Liver is the site of many diseases, many of which become symptomatic, while some are diagnosed only during autopsy. Steatosis (fatty liver, fatty change) corresponds to accumulation of triglycerides in the cytoplasm of hepatocytes. It is a frequent finding and represents a manifestation of reversible cell injury. Steatosis is a nonspecific lesion induced by a variety of causes. The degree of lipid deposition involving most parenchymal cells. Minor amounts of steatosis are of uncertain significance, and occur more frequently in elderly people, possibly as part of the aging process. More extensive steatosis is seen in a variety of primary hepatic diseases and in several systemic conditions.

In our study males were commonly affected and the incidence of liver disease showed higher cases between 21 to 50 years of age. Present study showed that Fatty change liver [Fig. 1] is the most common silent liver disease [5] in autopsy (39.5%), as compared to (35.69%) Patel PR et al[6, 7] followed by Normal liver (26.6%) in present study, as similar to the study by R. Thamil[8] reported (25.9%), Chronic venous congestion [Fig.2]in present study (15.6%) as compared to R. Thamil (16.7%), followed by Cirrhosis (2.8%) [Fig.3] in present study as compared to Patel PR et al (2.44%) and malignancy in present study (0.9%) as similar to R.Thamil (1.9%). [Table 4]

V. Conclusion

Autopsy examination is effective tool to identify silent liver diseases, among that Fatty change is most common liver disease and more common in males in the age group of 21 to 40 years. Quite fairly liver is said to be “The Custodian of Milieu Interior” hence autopsy is useful to ascertain the cause of death and to plan further approach.

References

- [1]. Ph. Madhubala Devi, et al. Pathological Findings of Liver in Autopsy Cases A Study at Imphal. J Indian Acad Forensic Med. July-September 2013, Vol. 35, No. 3
- [2]. Bal MS et al. Pathological findings in liver autopsy. Jiafm,2004;26(2).ISSN0971-0973
- [3]. Amarapurkar A et al. Fatty liver : Experience from western India. Annals of Hepatology 2007; Jan – Mar37-40
- [4]. Bethke BA, Schubert GE. Primary hepatic cancer and liver cirrhosis. Hepato gastroenterology. 1984; 31: 211-4.
- [5]. Sotoudehmanesh R, Sotoudeh M,et al. Silent liver diseases in autopsies from Forensic Medicine of Tehran. Arch Iran Med 2006; 9 (4): 324-28.
- [6]. Ghazala Hanif et al. Incidental findings in the liver- An Autopsy study Ann King Edward Med Coll Jan- Mar 2001; 7 (1): 58-60
- [7]. Patel PR et al. Incidental findings in autopsy examination of liver: a study at tertiary care hospital. INT J Community Med Public Health 2016; 2; 697-9.
- [8]. Thamil.Selvi R. et al. Common silence liver disease in and around of salem population: An Autopsy study. JCDR APRIL 2012; 6(2):207-210.

Table 1: Liver Weight And Sex Distribution (n = 99)

Liver wt in grams	Male	Female	Total
< 1000 gm	6	1	7
1000-1500 gm	30	9	39
1500-2500 gm	45	7	52
>2500 gm	1	0	1

Table 2: Age Wise Distribution Of Male- Female Cases In Liver Autopsy (n = 109)

AGE	Male	Female	Total	Percentage %
>61	6	0	6	5.5
51-60	9	3	12	11.0
41-50	20	1	21	19.3
31-40	23	5	28	25.7
21-30	28	5	33	30.3
11-20	2	5	7	6.4
1-19	1	1	2	1.8

**Table 3: Histopathological Findings
(n = 109)**

Histopathology	Male	Female	Total number of cases	Percentage %
Fatty Liver	37	6	43	39.5
Normal	24	5	29	26.6
Chronic venous congestion	12	5	17	15.6
Hepatitis	4	1	5	4.6
Cirrhosis	3	0	3	2.8
Hemangioma	1	0	1	0.9
Hepatocellular carcinoma	1	0	1	0.9
Autolysed Liver	7	3	10	9.1

**table 4: comparison studies of liver disease
(n = 99)**

Type of Hepatic lesion	Thamil Selvi..R et al [8]	Patel RR et al [7]	Present Study
Fatty Liver	26.9%	30.13%	39.5%
Normal	25.9%	-	26.6%
Chronic venous congestion	16.7%	1.22%	15.6%
Hepatitis	13.9%	0.98%	4.6%
Cirrhosis	7.4%	2.44%	2.8%
Hepatocellular carcinoma	1.9%	0.48%	0.9%

Fig 1: HPE x100- Fatty liver

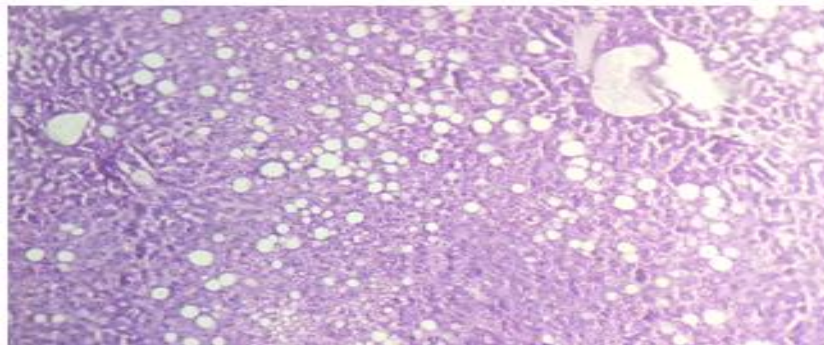


Fig 2: HPE x100- Chronic venous congestion liver

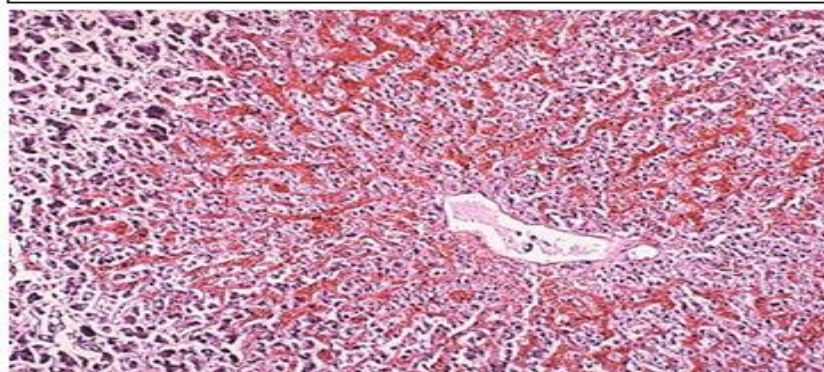
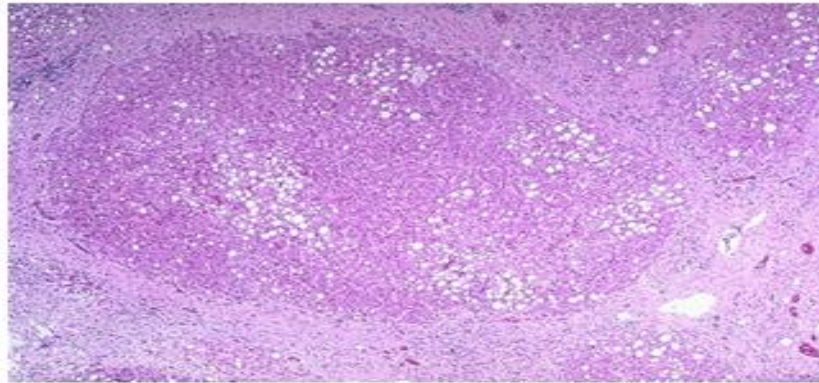


Fig 3: HPE x100 – Cirrhosis liver



*Dr.S.Selvi. "Study of Pathological Lesions in Liver Autopsy." IOSR Journal of Dental and Medical Sciences (IOSR-JDMS) 16.11 (2017): 45-48