

Case Report: Magnetic Resonance Imaging In Rabies Encephalitis

By – Dr. Suman Chaudhary, Dr. A.P. Verma, Dr. Hemant Kumar
Mishra, Dr. Sunil Agarwal, Dr. S.C. Gupta, Dr. M.C. Baberwal

Abstract:- Rabies has long been thought to be an invariably fatal disease with few reports of survival being available. Because of the fulminant course of the disease, imaging is mostly not possible in these patients. Even though rabies is definitively confirmed by the isolation of virus from biological samples or detection of the rabies antigen or antibodies, diagnosis is essentially clinical and magnetic resonance imaging (MRI) brain can be used as one of the modalities of investigation for the early detection of rabies and for distinguishing it from other encephalitis.

Keywords:- Encephalitis, MRI, rabies

Date of Submission: 29 -07-2017

Date of acceptance: 30-09-2017

I. Introduction

Rabies is one of the most feared diseases affecting human beings. It is invariably fatal once the clinical symptoms have set in. It is important to make an early diagnosis to enable the institution of public health measures. Literature regarding the neuroimaging features of rabies encephalitis is scanty due to two reasons: patients rapidly deteriorate following the onset of symptoms without a window in which to perform CT scan or MRI and the clinical presentation is often so characteristic that imaging may not be required. In this report we describe the MRI features in a case of rabies encephalitis and discuss the role of neuroimaging in this disease.

II. Case Report

A 15-year-old male child was bitten on the knee by a dog. Three doses of the antirabies vaccine were administered. twenty days after the bite, he presented with prodromal symptoms in the form of fever and malaise followed by altered sensorium, drowsiness, and irrelevant talking and inability to walk. On physical examination, he showed increased muscular tone in all four limbs, with hyperreflexia. Extensor plantar responses were seen bilaterally. No signs of meningitis were seen. To rule out other causes of neurological deficits, MRI brain was done. On the 7th day after the onset of symptoms, MRI brain was performed on a 1.5-Tesla GE scanner which revealed ill defined T2/fluid-attenuated inversion recovery (FLAIR) hyperintense lesions involving the bilateral cerebral peduncle and pontine tegmentum. Foci of hyperintense signal were also seen in bilateral basal ganglia. The involved regions showed low signal intensity on T1-weighted (T1W) imaging. Diffusion-weighted (DW) imaging revealed a mild increase in the apparent diffusion coefficients (ADCs) in the involved regions. No evidence of blooming was seen in these areas. The findings were consistent with those described in prior reports of rabies encephalitis. The neurological status of the patient continued to deteriorate. After 5 days, the child expired. Considering the characteristic clinical presentation and rapid progression of the illness to death, laboratory confirmation of the disease was not obtained.

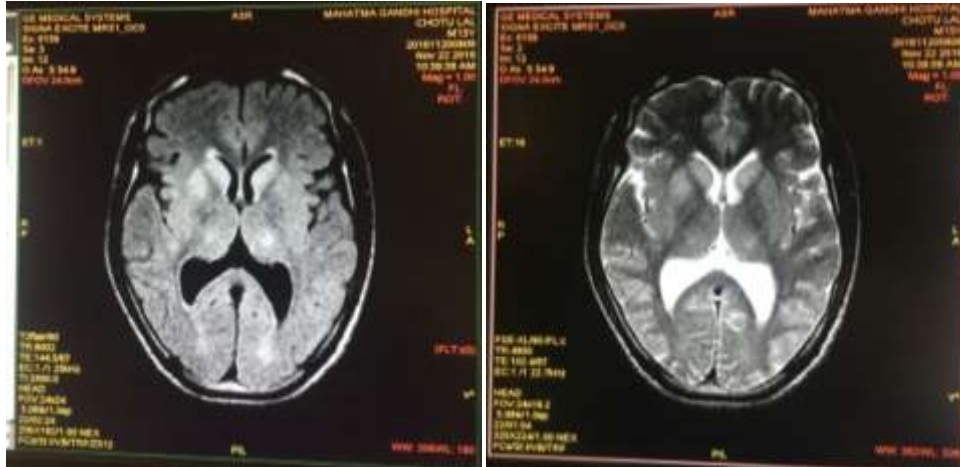

Figure 1 (A and B) : Axial T2/FLAIR MRI images reveal hyperintense lesions involving bilateral basal ganglia and thalami.

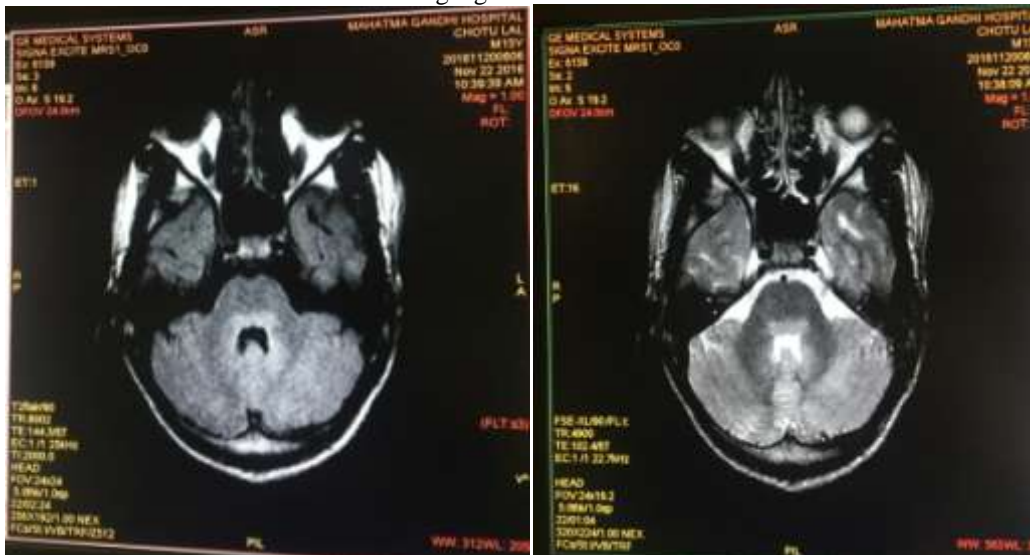


Figure 2 (A and B) : Axial T2/FLAIR MRI images reveal hyperintense lesions involving the dorsal pons (1a and b)

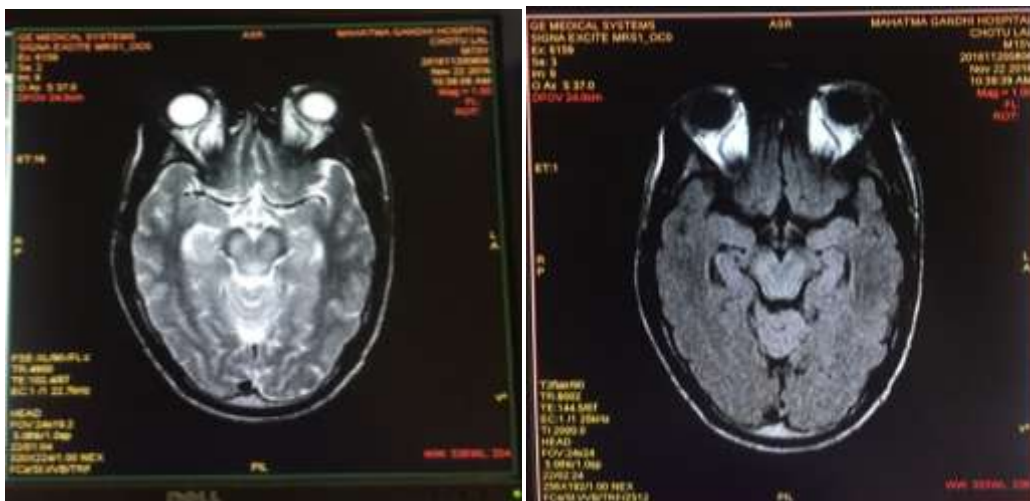

Figure 3: Axial T2/FLAIR MRI images reveal hyperintense lesions cerebral peduncles 3a and b)

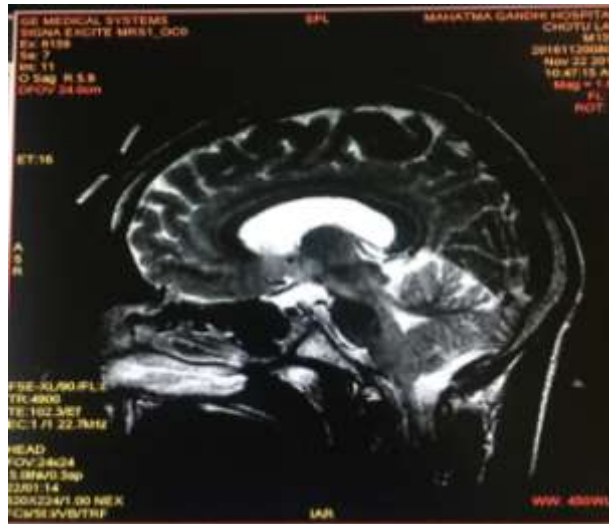

Figure 4 T2 sag MRI images reveal hyperintense lesions involving pons and cerebral peduncles (4a)

III. Discussion

Rabies is an acute, progressive encephalitis caused by a neurotropic RNA virus of the Rhabdoviridae family. Though it is extremely uncommon in the developed world, rabies is a significant public health problem in developing countries¹. Transmission of the disease is mostly through the bite of dogs, through inhalation in bat-infested caves, and in laboratory settings and in rare instances, there is human-to-human transmission. The virus is abundant in saliva of infected animal and is deposited in the wound inflicted on biting. The virus replicates in the muscle tissues at the site and subsequently infects the motor neurons and travels to central nervous system by retrograde axoplasmic flow.^{1,3} Owing to the characteristic clinical presentation, the poor prognosis, and the difficulty in handling the agitated patient, imaging studies are rarely performed² However, imaging of the brain may be used as one of the modalities of investigation for the early detection of rabies and for differentiating it from other encephalitis.¹⁵¹ MRI findings in encephalitic form and paralytic form show ill-defined hyperintense lesions in the brainstem involving the dorsal aspect of the medulla, pontine tegmentum, periaqueductal gray matter, collicular plate, as well as the central white matter of the midbrain, deep and cortical gray matter, deep and subcortical white matter, hippocampi, medial aspects of the thalami, and in the hypothalamus on both sides of midline on T2W imaging.^{6,2} In our cases also, all the findings were same on T2W imaging. In addition, T2 hyperintensity were also seen in the bilateral basal ganglia and left temporoparietal cortex in case no.2. There is also role of DW/ADC maps which show increased diffusion in rabies encephalitis.²¹ However, there are few case reports which show that diffusion restriction can also be seen in involved areas.⁵

Definitive diagnosis of rabies requires laboratory confirmation of the presence of rabies antigen or rabies antibodies or the isolation of the virus from biological samples. However, rabies antigen and antibodies may not be detectable early in the course of the disease.^[1] Also, the poor availability of these laboratory facilities may further delay the confirmation of rabies infection. MRI findings in paralytic rabies can show hyperintense signal in medulla extending to cervical cord associated with cord expansion.^[7] Both the paralytic and encephalitic forms of the disease have been reported to have similar distribution of signal changes on MRI.^[6] Contrast-enhanced studies do not reveal enhancement of these structures in the early phase, while mild-to-moderate enhancement of the hypothalamus, brainstem, and gray matter of the cord may be seen when the patient becomes comatose.

The brachial plexus is an exception and can show enhancement in the early prodromal phase of the disease.^[6] Immunohistochemistry shows that there is maximum concentration of Negri bodies and rabies virus antigen in distribution of signal changes.⁸ Differentials of rabies encephalitis include Japanese B encephalitis and other viral encephalitides, however the predilection of rabies for the brainstem, thalami and hippocampi; the absence of hemorrhages and the absence of enhancement during the acute phase of the disease may help in differentiating it from Japanese B encephalitis and other viral encephalitides. Other important differentials of rabies encephalitis are ischemic encephalitis and mitochondrial diseases. Differentiation can be made by DW images as rabies encephalitis does not show restriction as compared to these entities which show diffusion restriction. MRI may also help differentiate this disease from other illnesses such as Japanese B encephalitis and other viral rhombencephalitides, acute disseminated encephalomyelitis, osmotic demyelination, hypoxic-

ischemic encephalopathy, hypoglycemia and mitochondrial disorders-especially when the clinical presentation is atypical. The predilection of rabies for the brainstem, thalami and hippocampi; the reduced intensity of signal on T2W images;

the absence of hemorrhages and the absence of enhancement during the acute phase of the disease may help in differentiating rabies from Japanese B encephalitis and other viral encephalitides. Rupprecht *et al.* have devised an algorithmic approach to the neurological manifestations and imaging features of rabies encephalitis and other common viral encephalitides.⁹ So we conclude that though rabies encephalitis has classical clinical features, MRI is the imaging of choice for its early diagnosis and it helps to differentiate rabies encephalitis from other encephalitis. Early diagnosis of rabies does not have any impact on patient prognosis, but it does enable prompt institution of public health measures.

References

- [1]. Hemachudha T, Laothamatas J, Rupprecht CE. Human Rabies: a disease of complex neuropathogenetic mechanisms and diagnostic challenges. *Lancet Neurol.* 2002;1:101-9.
- [2]. Rao AS, Varma DR, Chalapathi Rao MV, Mohandas S. Case report: Magnetic resonance imaging in rabies encephalitis. *Indian J Radiol Imaging* 2009;19:301-4.
- [3]. WHO Expert Consultation on Rabies. *World Health Organ Tech Rep Ser.* 2005;93:1-88.
- [4]. Rupprecht CE, Hanlon CA, Hemachudha T. Rabies re-examined. *Lancet Infect Dis.* 2002;2:327-43.
- [5]. Jain M, Mathur RK. MRI in Rabies Encephalitis. Available from: <http://www.maxhealthcare.in/newsletter/max-medical-journal/may-11/mri-in-rabies.html> [Last accessed on 2015 Mar 24].
- [6]. Laothamatas J, Hemachudha T, Mitrabhakdi E, Wannakrairot P, Tulayadaechanont S. MR Imaging in Human Rabies. *AJNR Am J Neuroradiol* 2003;24:1102-9.
- [7]. Vaish AK, Jain N, Gupta LK, Verma SK. Atypical rabies with MRI findings: Clue to the diagnosis. *BMJ Case Reports* 2011;2011.
- [8]. Tirawatpong S, Hemachudha T, Manutsathit S, Shuangshoti S, Phanthumchinda K, Phanuphak P. Regional distribution of rabies viral antigen in central nervous system of human encephalitis and paralytic rabies. *J Neurol Sci.* 1989;92:91-9. [[PubMed](#)]
- [9]. Rupprecht CE, Hanlon CA, Hemachudha T. Rabies re-examined. *Lancet Infect Dis* 2002;2:327-43. [Back to cited text no. 6.](#)