

Minimally Invasive Restoration of Endodontically Treated Molars

*Marwa Chakroun¹, Mohamed Chebil², Ameni Adli³, Zohra Nouira⁴,
Jilani Saafi⁴, Mounir Cherif⁵

¹DDS, ²Assistant Professor, ³Associate Professor, ⁴Professor, ⁵Professor Head of Department
Department of Fixed Prosthodontics, Dental Clinic of Monastir, Tunisia.

Abstract: The restoration of the endodontically treated tooth is a widely debated topic in the literature and has been for many years. The criteria studied are so many and the analytical methods are varied. Indeed, the "gold standard" is to choose the technique that offers the least invasive preparation with maximum dental tissue preservation and improved retention and resistance to fracture. The endocrown could be an alternative to restore a posterior endodontically treated tooth. Therefore, the present article describes a case report of restoration of a non-vital lower molar with an endocrown.

Keywords: endodontically treated teeth, molars, endocrown, CAD/CAM technique

Date of Submission: 02-12-2017

Date of acceptance: 14-10-2017

I. Introduction

Compared to vital teeth, fracture risk of endodontically treated teeth is higher because of loss of structural integrity associated with dental caries, access cavity preparation, and root canal preparation rather than changes in dentin (1). With the development of adhesive systems, the need for post-core restorations is reduced. Especially for restoration of excessively damaged endodontically treated molars, endocrowns have been used as an alternative to the conventional post-core and fixed partial dentures (2). It consists of a total porcelain crown fixed to an endodontically treated posterior tooth, which is anchored to the internal portion of the pulp chamber and to the cavity margins, thus obtaining macro-mechanical retention (provided by the pulpal walls), and micro-retention (by using adhesive cementation) (3). In addition, endocrown presents greater fracture strength than conventional crowns (4).

However, the success and longevity of the endocrown are directly related to tooth selection, correct preparation of the tooth, the selection of the most suitable ceramic options, and the choice of bonding material, since adequate adhesive cementation is absolutely necessary for the success of this restorative treatment (5).

Case Presentation

A 40-year-old female patient was referred to our department for restoring her first left mandibular molar. Clinical examination showed a damaged molar with a defective amalgam restoration (Figure 1). Periapical radiograph showed an incomplete endodontic filling of the apical third of the mesial root due to the presence of a fractured file (Figure 2). We tried to remove the fractured instrument during the endodontic retreatment. Unfortunately, we failed since the instrument was in the apical third of the root.

Since the tooth didn't show any clinical symptomatology, endocrown restoration was recommended. All the unsatisfactory restorative amalgam was removed from tooth #36. The canal entrances were sealed with conventional, chemically activated glass ionomer cement. The preparation consisted of a cervical margin in the form of a butt joint and a central retention cavity into the entire pulp chamber, constructing both the crown and the core as a single unit. The appropriate reduction of the buccal and lingual walls was done. Interocclusal space was carefully evaluated and occlusal reduction done to achieve a clearance of 2 mm (Figure 3).

A provisional endocrown was performed using polymethylacrylate and cemented with eugenol-free temporary cement (Figure 4). The impression was made with polyvinyl siloxane. The endocrown was manufactured in the laboratory via indirect CAD/CAM technique. A lithium-disilicate block was chosen because of its sufficient fracture resistance value (Figure 5).

The patient returned for a try-in of the crown and to test the internal and proximal adjustments, prosthetic retention, and the esthetic result. For cementation, the external cervical margin of the crown was protected with wax and then etched with 10% hydrofluoric acid for 20 seconds, then washed and dried. Next, silane was applied and dried. After that, the tooth was isolated (Figure 6) and treated with 37% phosphoric acid for 30 seconds, then thoroughly rinsed and dried.

Bonding was performed using a dual curing self-adhesive permanent resin (TOTALCEM ®). A thin layer was applied to the prosthetic endocrown, which was positioned, and polymerized at intervals of 5 seconds on the free surfaces, making it easy to remove cement excesses. Afterwards it was polymerized for 60 seconds on all surfaces (Figure 7). Then, occlusion contact was checked in order to have no area contact when dynamic occlusion. If there is contact, rectifications must be followed by a polishing.

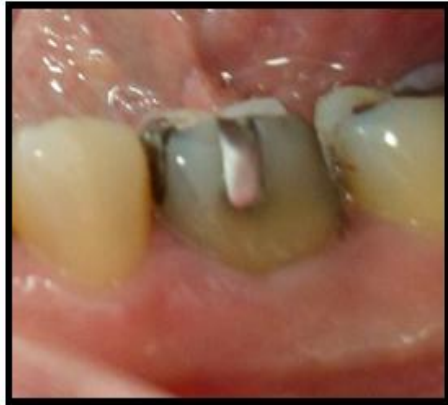

Figure 1: Severely damaged molar with amalgam and provisional restoration.

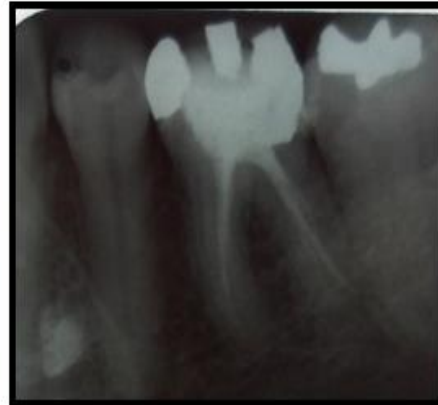


Figure 2: Initial radiograph: the mesial root is incompletely filled due to a fractured file

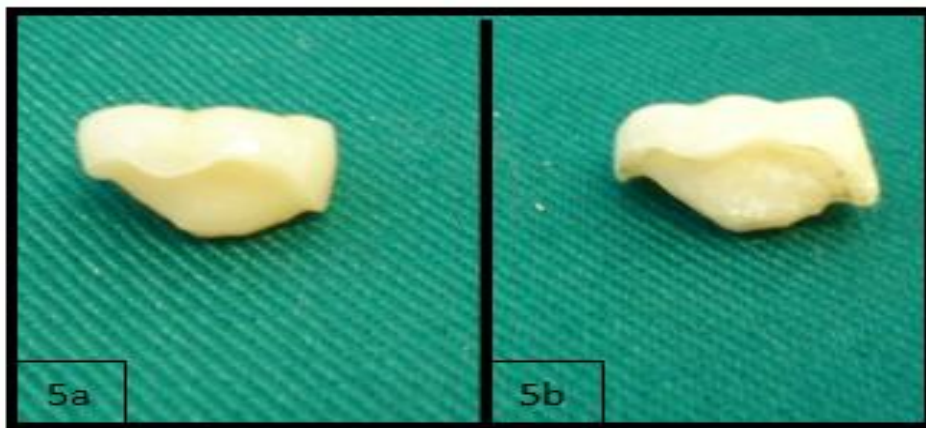

Figure 5a : Definitive prosthesis

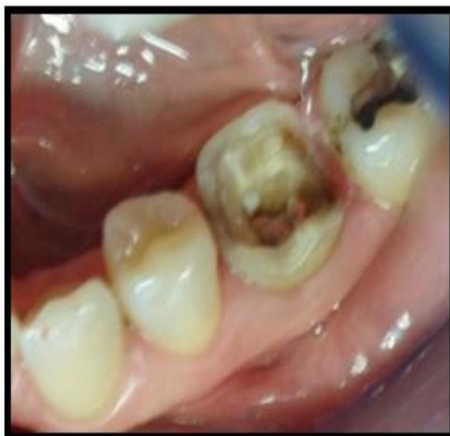

Figure 3 : Molar preparation

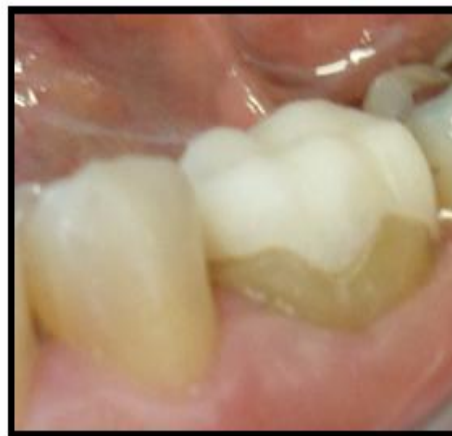

Figure 4 : Provisional prosthesis

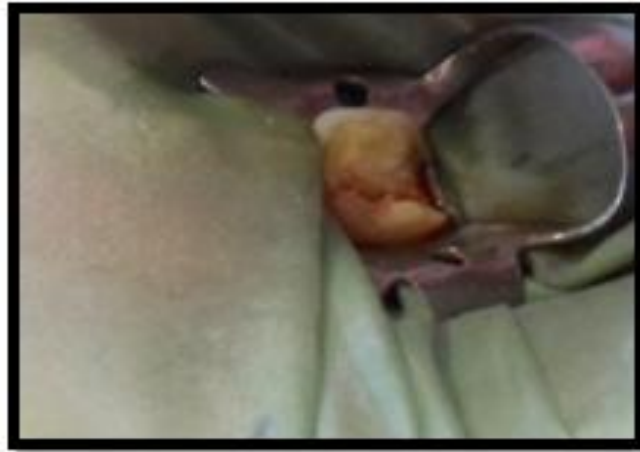

Figure 6 : Molar isolation before endocrown bonding

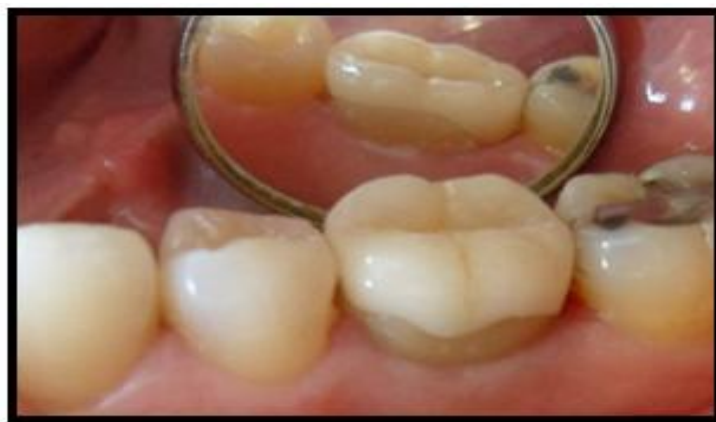

Figure 7: Clinical view after bonding the endocrown

II. Discussion

Endocrown does not need peripheral tooth preparation; it's a good treatment that preserves dental tissue. For preparation, the axial height is reduced at least two millimeters. These two millimeters must always be checked in occlusion. This makes it possible to take into account the occlusal relationship between the prepared tooth and the antagonists. The groove on the buccal wall is dictated by the location of the amalgam and avoid extra mutilation with excessive occlusal reduction. The depth of the cameral chambers should be at least three millimeters, with a divergence of the walls of eight to ten degrees.

There Are Two Types Of Preparation For Endocrowns:

1. A cervical margin in the form of a butt joint. It corresponds to a simple reduction of the occlusal height without peripheral preparation.
2. A peripheral preparation with a shoulder finish line.

In both cases, a preparation of the pulp chamber that does not extend into the root canals must be performed.

Given the cervical discoloration, the peripheral preparation can give esthetic results. However, the cervical third of the mandibular molar is not visible and does not cause an esthetic problem. To keep as much dental tissue as possible, we chose the butt-joint margin.

For endocrowns, 90% of the failures were tooth fracture associated with displacement of restoration on the opposite side of the application of force.

Only 10% presented fracture of the tooth (in the apical third of the root portion) (6)

Different materials like feldspathic, glass ceramic, hybrid composite resin and newest CAD/CAM (computer aided design / computer aided manufacturing) resin blocks can be used for fabrication of endocrowns (7-10).

The endocrown, was first described using the CEREC system; however, other systems may be employed in this particular restoration. Recently, the VITA-PM9 system (Vident, Brea, CA, USA) has been commercialized. It consists of a pressed ceramic that uses a microparticulate coating.

The system employs thin feldspathic ceramic, which provides excellent resistance and polish (11-14).

In this case, the endocrown was made with lithium disilicate, which have esthetic result, provides excellent resistance and polish(15,6). However, according to some clinicians, pressable ceramic systems yield good functionality, retention, esthetics, and durability.

The essential advantage of this technique is the best fitting of the endocrown with the anatomy of the floor of the cavity and the option of using an articulator.(17)

References

- [1]. Roopadevi Garlapati, Bhuvan Shome Venigalla I, Shekhar Kamishetty I, Jayaprakash Thumu ; Ceramic onlay for endodontically treated mandibular molar ; Journal of Orofacial Sciences 69 Vol. 6 • Issue 1 • January 2014
- [2]. Gaye Sevimli, Seda Cengiz, M. Selçuk Oruç ; Endocrowns: Review ; J Istanbul Univ Fac Dent 2015;49(2):57-63.
- [3]. Gislaine Rosa Biacchi, Beatriz Mello, Robertatarkany Basting, The Endocrown: An Alternative Approach for Restoring Extensively Damaged Molars ; Journal of Esthetic and Restorative Dentistry Vol 25 • No 6 • 383–390 • 2013
- [4]. GR Biacchi, RT Basting ; Comparison of Fracture Strength of Endocrowns and Glass Fiber Post- Retained Conventional Crowns ; Operative Dentistry, 2012, 37-2, 130-136
- [5]. Rafael Menezes Silva, Rafael Francisco Lia Mondelli, Sérgio Kiyoshi Ishikiriyama, Endocrown: a conservative approach, Braz Dent Sci 2016 Apr/Jun;19(2):121-131
- [6]. El-Damanhoury HM, Haj-Ali RN, Platt JA ; Fracture resistance and microleakage of endocrowns utilizing three CAD-CAM blocks ; Oper Dent. 2015 Mar-Apr;40(2):201-10
- [7]. Banode Ankur Mahesh, Gade Vandana , Patil Sanjay, Gade Jaykumar, Chandhok Deepika, Nathani Aatif, Endocrown: Conservative Treatment Modality for Restoration of Endodontically Treated Teeth – A Case Report, Endodontology, December 2015;27(2):188-191.
- [8]. Beuer F, Schweiger J, Edelhoff D. Digital dentistry: an overview of recent developments for CAD/CAM generated restorations. Br Dent J. 2008; 204: 505-511.
- [9]. Bindl A, Richter B, Mörmann Wh. Survival of ceramic computer- aided design/manufacturing crowns bonded to preparations with reduced macro retention geometry. Int J Prosthodont. 2005 May-Jun; 18(3):219-24.
- [10]. Daniel J. Poticny, James Clim, Cad/Cam in-office technology Innovations after 25 years for predictable, esthetic outcomes, J Am Dent Assoc 2010; 141(6 suppl):5S-9S.
- [11]. Leonardo Fernandes da Cunha, José Mondelli, Caroline Moreira Auersvald, Carla Castiglia Gonzaga, Rafael Francisco Lia Mondelli, Gisele Maria Correr, and Adilson Yoshio Furuse, Endocrown with Leucite-Reinforced Ceramic: Case of Restoration of Endodontically Treated Teeth; Hindawi Publishing Corporation Case Reports in Dentistry, Volume 2015, Article ID 750313, 4 Pages
- [12]. Dennis J. Fasbinder. The CEREC system; 25 years of chair side CAD/CAM dentistry, , J Am Dent Assoc 2010;141;3S-4S
- [13]. FASHBINDER D.J. Predictable Cerec occlusal relationships. In Mörmann W.H. (ed.) State of the art of CAD/CAM restorations, 20 years of Cerec, Berlin: Quintessence, 2006
- [14]. Laborde G, Lacroix P, Margossian P, Laurent M. Les systèmes céramo-céramiques : Actualités et perspectives. Real Clin 2004;15:89-104. 9
- [15]. Dietschi D, Spreafico R. Restauration esthétique collées : composites et céramique dans les traitements esthétiques des dents postérieures. Paris : Quint Int, 1997, 215p.
- [16]. Fron H, Coudray L, Attal Jp. Céramiques, lesquelles choisir ? Inf dent 2007; 29: 1693-1698.
- [17]. Roopak Bose Carlos, Mohan Thomas Nainan, Shamina Pradhan, Roshni Sharma, Shiny Benjamin, and Rajani Rose; Restoration of Endodontically Treated Molars Using All Ceramic Endocrowns; Hindawi Publishing Corporation Case Reports in Dentistry Volume 2013, Article ID 210763, 5 pages

*Marwa Chakroun. “Minimally Invasive Restoration of Endodontically Treated Molars.” IOSR Journal of Dental and Medical Sciences (IOSR-JDMS) , vol. 16, no. 10, 2017, pp. 78–81.