

## Suprapubic Basal Cell Carcinoma- A CASE REPORT

<sup>1\*</sup>Agarwal Navendu, <sup>2</sup>Sharma Brijesh Kumar

(Department of General Surgery/Mahatma Gandhi Medical College and Hospital/MGUMST/ Rajasthan, India)

Corresponding Author: \*Agarwal Navendu

**Abstract:** This is the case of a 45 years old female who presented with non-healing ulcer measuring 2x2 cm. below umbilicus. Excisional biopsy of ulcer with wide margin was done with primary closure. Histopathology revealed it to be a BCC. Margins of excised specimen were negative. In follow up patient was found healthy without recurrence. Ours is a unique case as BCC. occurs in sun exposed body parts whereas suprapubic region is a covered area.

**Keywords:** BCC, Cutaneous, India, Rare, Suprapubic

Date of Submission: 04 -09-2017

Date of acceptance: 14-10-2017

### I. Introduction


Basal cell carcinoma (BCC) is the most common paraneoplastic disease in the human neoplasms[1]. Up to 80% of all lesions are found on the head and neck whereas approximately 15% develop on the shoulders, back or chest. [2]. It is more commonly seen in males may be due to greater occupational and recreational exposure to UV radiation. However, an indian series reported unusual female preponderance [3]. BCC shows slow progression and metastases are found in 0.0028- 0.5% of the cases [4] however, significant local destruction and mutilation could be observed when treatment is neglected or inadequate. Different variants of BCC are nodular, cystic, micro nodular, superficial, pigmented described in literature and the differential diagnosis in some cases could be difficult. The staging of BCC is done by following Tumor, Node, Metastasis (TNM) classification. Numerous therapeutic modalities are available for treatment of BCC, with their respective advantages or disadvantages, but do not absolutely remove the risk of relapse. Early diagnosis based on good knowledge and timely organized treatment is a precondition for better prognosis.

### II. Case report

**II.1. Patient information-**A 45-year-old female was admitted with complaint of small non-healing ulcer on lower abdomen below the umbilicus. She had no history of D.M., or tuberculosis. No relevant family history of skin diseases or malignancy was present. The original lesion was provisionally diagnosed as an infected mole and excised at a peripheral center. On biopsy of the mole it was diagnosed as nodular basal cell carcinoma with positive resected margins.

**II.2. Clinical Findings-** On physical examination a 2x2 cm ulcer was on suprapubic region along the line joining both ASIS [fig.1]. The ulcer base was mobile with no fixity to underlying structures. Ulcer was non-healing, with raised edges, hard in consistency.

#### II.3 Timeline



**II.4 Diagnostic assessment:** Preoperative assessment was done; all general parameters were found normal and surgery was fixed.

**II.5 Therapeutic intervention-** During surgery wide excision of the ulcer was done [fig. 2], the tumor involved skin and subcutaneous tissue. The underlying fascia was free [fig. 3]. The abdominal skin was lax. Primary closure was done in layers with placement of rhombovac drain which was removed after one day. Her postoperative course was uneventful and she was discharged.

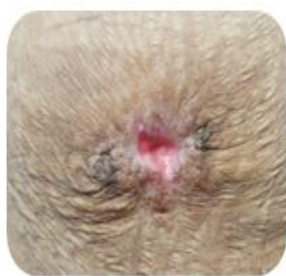

fig.1 2x2 cm Ulcer seen in suprapubic region

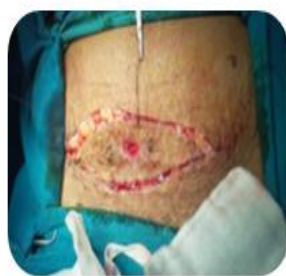

fig.2 Incision circumscribing the ulcer

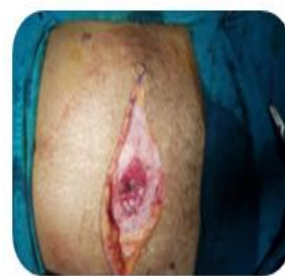

fig.3 Excised disc of rectus sheath to achieve negative margins

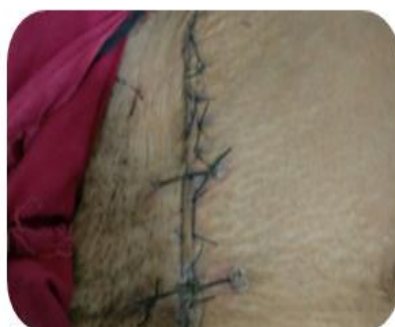

fig.4 Follow up on day 15

**II.6 Follow up-** Wound was well approximated on day 15 of follow up[fig.5]. New histopathology report confirmed BCC with negative resection margins. Follow up was done regularly for 4 months and no signs of recurrence were seen

### III. Discussion

The BCC affects mainly sun exposed areas, in about 80% of patients appearing on the head, and in half of them affects the cheeks and the nose[1]. The other sun exposed areas like the trunk and limbs are less affected and in only 4% of patients lesions can appear on genitals and perianal area[5].The main etiological agent responsible for BCC is the chronic UV exposure consisting of mostly UVB rays with length 290-320 nm[8]. This causes the activation of proto-oncogenes and inactivation of tumor suppressive genes in the keratinocytes. High doses of UV light produce free oxygen radicals, which in combination with the reduced antioxidant protection system result in different degeneration processes including carcinogenesis. The UV rays cause production of pyrimidine dimers and loss of heterozygosity of both tumor suppressive(protective) genes-TP53 and PTCH, resulting in BCC.Other proposed causes of BCC are exposure to arsenic, X-rays, coal-tar derivatives, and thermal burns[7].Immune system suppression in the pathogenesis of skin carcinomas is also suspected since the occurrence of BCC increased among immune suppressed patients and the lesions affect mainly the non-exposed skin of the body and the upper limbs.Surgery is the first line therapeutic method. The results of 5-year follow-up after the surgical excision of BCC with up to 1.5 cm diameter size of the primary tumor show the reappearance in 12% of the cases, while in primary tumor with size above 3 cm diameter the rate is 23%[2]. It is believed that the reoccurrence of tumor is from the periphery nests of the tumor that could not always be detected by routine histology.

### IV. Conclusion

To conclude, BCC is a disease which is frequently diagnosed at the outpatients' practice. The early diagnosis based on good knowledge and adequate treatment is a precondition for better prognosis. Numerous methods of treatment do not absolutely remove the risk of relapses and if the case is neglected, BCC may destroy the underlying tissues and metastasize. Ours is a unique case as the site of lesion is suprapubic which has not yet been reported.

### References

- [1]. Dourmishev A, Popova L, Dourmishev L. Basal-cell carcinoma and squamous-cell carcinomas: Epidemiology, location and radiotherapy. *Skin Cancer*. 1996;11:195–200.
- [2]. Scotto J, Kopf AW, Urbach F. Non-melanoma skin cancer among Caucasians in four areas of the United States. *Cancer* 1974;34:1333-8.
- [3]. Mamata M, Karuna R. Basal Cell carcinoma: evaluation of clinical and histologic variables. *Indian J Dermatol*2004;49:25-7
- [4]. Shrivastava R, Singh KK, Shrivastava M. Soft tissue metastasis in basal cell carcinoma. *Indian J Dermatol*2007;52:206-8.
- [5]. Mulvany NJ, Allen DG. Differentiated intraepithelial neoplasia of the vulva. *Int J Gynecol Pathol*.2008;27:125–35. [[PubMed](#)]
- [6]. Dessinioti C, Antoniou C, Katsambas A, Stratigos AJ. Basal cell carcinoma: What's new under the sun. *PhotochemPhotobiol*. 2010;86:481–91. [[PubMed](#)]
- [7]. Gaughan LJ, Bergeron JR, Mullins JF. Giant basal cell epithelioma developing in acute burn site. *Arch Dermatol* 1969; 99: 594-5.
- [8]. Silverman MK, Kopf AW, Bart RS, Grin CM, Levenstein MS. Recurrence rates of treated basal cell carcinomas.Part 3: Surgical excision. *J DermatolSurgOncol*. 1992; 18:471-6 [[PubMed](#)]

\*Agarwal Navendu. “Suprapubic Basal Cell Carcinoma- A CASE REPORT.” *IOSR Journal of Dental and Medical Sciences (IOSR-JDMS)* , vol. 16, no. 10, 2017, pp. 37–39.