

A rare case of Angiomyxoid Lipoma

*Dr. Deepesh Agrawal¹, Dr Anuj Kumar², Dr S.K. Dhakaita³,

^{1,2} Postgraduate student, ³ Prof. Dept of Surgery, R.D. Gardi Medical College, Surasa, Ujjain

Corresponding Author: Dr. Deepesh Agrawal

Abstract: Angiomyxolipoma is considered an extremely rare variant of lipoma consisting of an admixture of adipose and myxoid elements with numerous vascular structures. We Report the case of a 50 year old female presented with painless swelling over left inguinal region. The Ultrasonography revealed ill-defined, ill-marginated heterogeneous, hypoechoic lesion with area of liquefactive necrosis in it showing thick moving echoes of approxvol 18 cc adjacent to the base of the lesion. Rest of the lesion showed heterogeneous appearance with mild to moderate vascularity and multiple specks of calcification. Patient underwent large excision. The diagnosis was retained on histological findings.

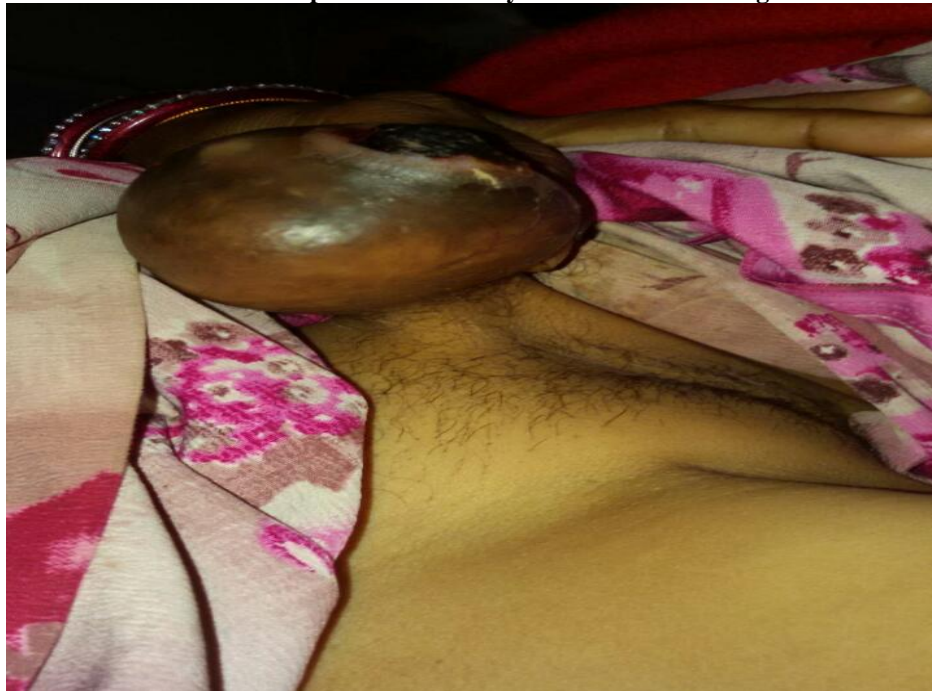Date of Submission: 05-09-2017

Date of acceptance: 10-10-2017

I. Introduction

- Lipoma is a benign tumor composed of mature adipocytes. It is the most common soft tissue mesenchymal tumor in adults. It has many variants. Angiomyxolipoma (AML), or vascular myxoma, is considered as a variant of lipoma. It is a very rare benign tumor, first described in 1996 by Mai et al, and since then 17 cases have been reported in literature arising from different sites.
 - It presents as a well-circumscribed tumor characterized by an admixture of mature adipose tissue, paucicellular myxoid stroma, and an abundance of thin- and thick-walled blood vessels.
 - Here we report first case of angiomyxolipoma arising in subcutaneous tissue from inguinal region.
- Case History
- A 50 year old farmer women presented with 3 year history of a painless swelling on left inguinal region.
 - An ulcer of size 2*3 cm was present over the swelling.

- **Ulcer developed two and half years after the swelling.**



General Examination

- General Condition: - Fair, Afebrile, PR 78/min, BP 116/80 mm of Hg, RR 17 per min.
- Conjunctiva pink, Sclera white, No Pallor Icterus, Cynosis, Clubbing, lymphadenopathy, Edema.

Local Examination

- On local examination there was found to be solitary, movable well demarcated subcutaneous mass that measured 7cm in greatest dimension.

Investigations

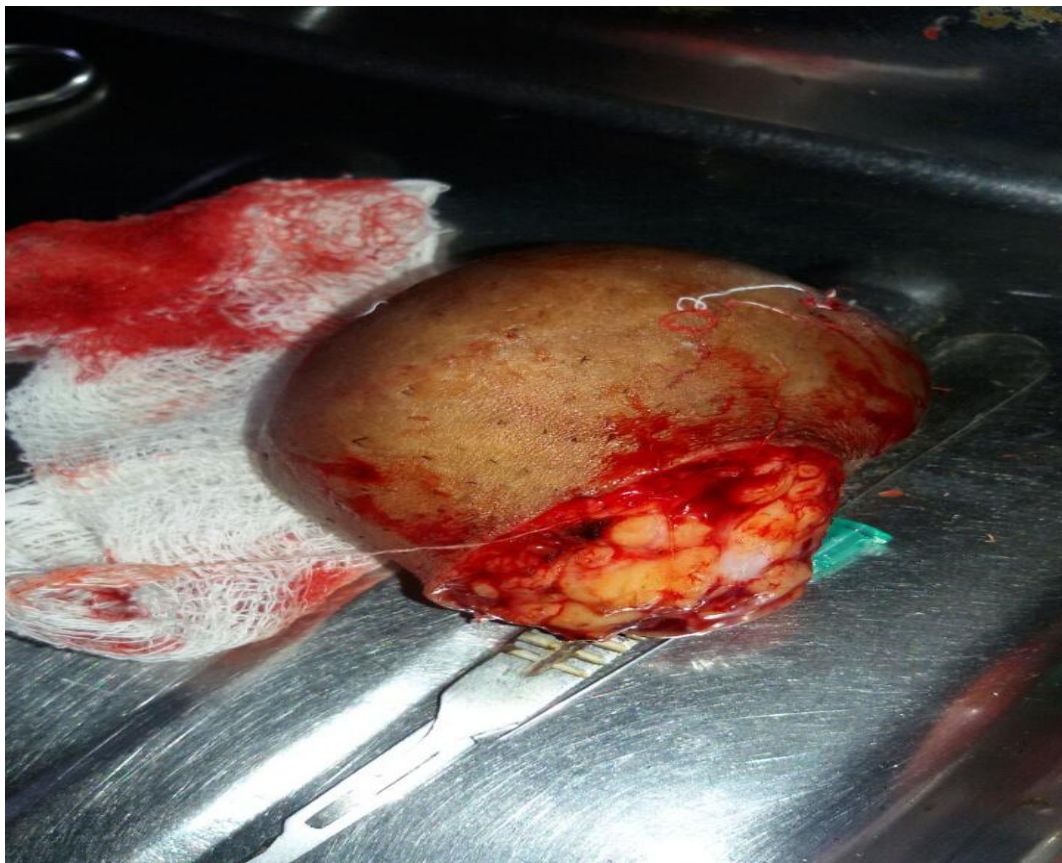- All her routine investigations were within normal limit.
- Ultrasonography showed a heterogenous lesion involving the superficial plane of left inguinal region .
- FNAC from cystic swelling and dependent ulcer showed acutely inflamed hypocellular lesion of skin and soft tissue with benign dependent ulcer showing features of suppurative adenaxal mass along with myxoid growth.

Treatment

- Patient underwent excision with primary suturing under spinal anesthesia.

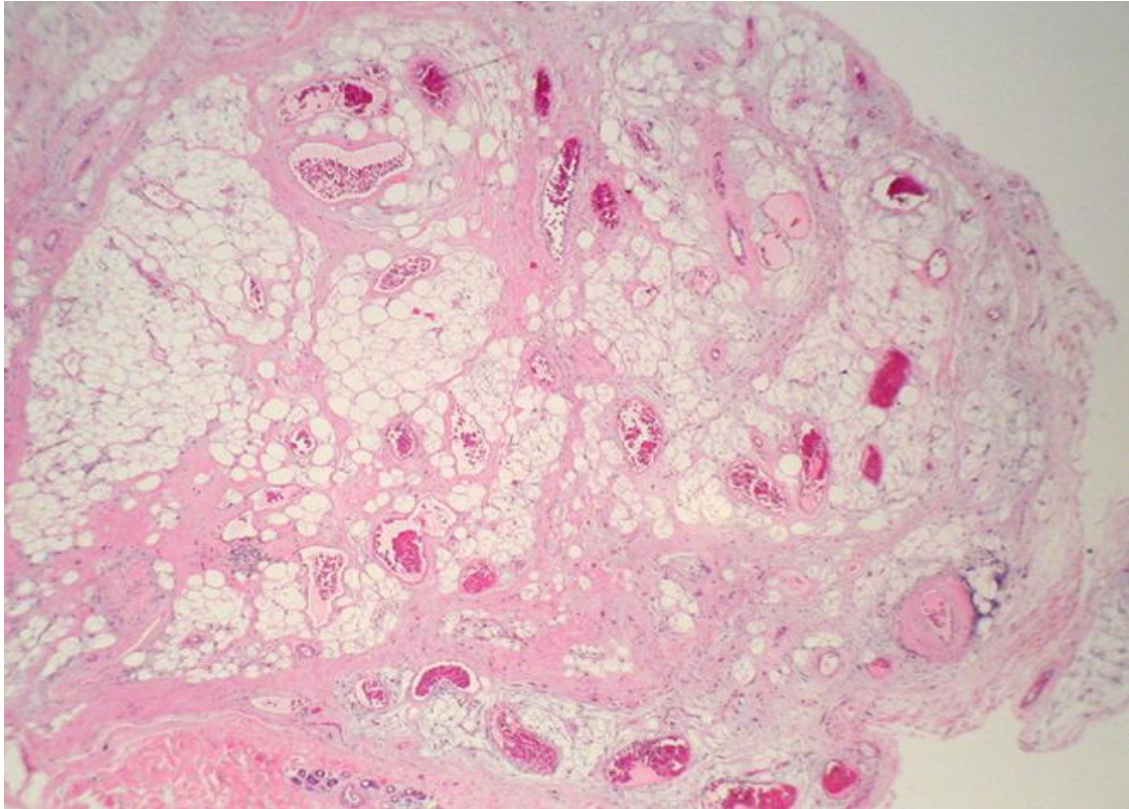
Histopathology

- Gross
- Skin covered firm tissue piece.
- On cut section multiple cystic areas filled with haemorrhagic and glistening greyish white areas separated by fibrous septa are seen.



- **Microscopy**

Hematoxylin and eosin stained sections show covering stratified squamous epithelium which is unremarkable. The dermis shows loose myxoid areas surrounded by fibrous tissue core comprising of spindle cells, adipocytes along with dilated blood vessels lined by flattened endothelial cells and filled with inspissated RBC's and foci of haemorrhagic necrosis. Overall features are suggestive of Angiomyxoid Lipoma.



II. Discussion

- Angiomyxoidlipoma is a very rare benign tumor. It is a variant of lipoma with characteristic histopathological features. It was first reported in 1996 by Mai et al who reported the tumor in spermatic cord which showed a proliferation of mature adipocytes associated with a myxoidstroma and with multiple blood vessels. After this 16 cases have been reported in many sites. Ages of patients ranged from 4 to 69 years. Angiomyxoidlipoma is a soft tissue tumor which presents as a painless slow growing mass.
- Grossly it presents as a well-defined mass of firm consistency.
- On cut section it appears yellow coloured lipomatous and gelatinous in some places, mixed with focal haemorrhage or dilated blood vessels.
- On microscopy this tumour is composed of admixture of myxoid areas with mature adipose tissue and numerous blood vessels. Immunohistochemical studies show that the cells in myxoid component express CD34 and vimentin. Adipose cells express S100 protein and blood vessels are positive for CD34, SMA and vimentin. Desmin and HMB45 were tested in many cases and were negative. Ki67 was also tested but was found under 3%.
- It has to be differentiated from myxoidliposarcoma which is a highly malignant lesion but in some cases it presents as well circumscribed by fibrous tissue with scanty mitosis and mild cellular atypia. The presence of lipoblast and a plexiform or 'chicken wire' vascular pattern are the key for diagnosis. Angiomyxoidlipoma lacks the pleomorphism, nuclear atypia. Other differential diagnosis include benign lesions such as spindle cell lipoma and angioliipoma.
- It is the combination of the adipose tissue, blood vessel and the myxoidstroma that favours the diagnosis of Angiomyxoidlipoma.

III. Conclusion

- We present a new case of subcutaneous angiomyxolipoma of inguinal region. Further cases are needed to evaluate more the histopathological features of these tumours. In our case the treatment was surgical.
- There is no recurrence till date.

References

- [1]. Mai KT, Yazdi HM, Collins JP. Vascular myxolipoma ("angiomyxolipoma") of the spermatic cord. *Am J SurgPathol* 1996; 20: 1145-8.
- [2]. FatenHammedi et al Report of a new case in subcutaneous tissue and review of the literature. *JCRP* 2013;1:17-19
- [3]. Margaret Song et al Angiomyxolipoma of subcutaneous tissue. *Ann Dermatol* Vol. 21. No.2, 2009
- [4]. Song M, Seo S, Jung D, et al. Angiomyxolipoma (vascularmyxolipoma) of subcutaneous tissue. *Ann Dermatol* 2009; 21: 189-92.
- [5]. Martínez-Mata G, Rocío MF, Juan LE, Paes AO, Adalberto MT , Angiomyxolipoma (vascular myxolipoma) of the oral cavity. Report of a case and review of the literature, *Head Neck Pathol.* 2011;5(2):184-7.

*Dr.Deepesh Agrawal. "A rare case of Angiomyxoid Lipoma." *IOSR Journal of Dental and Medical Sciences (IOSR-JDMS)* 16.10 (2017): 54-57