

## Primary Osteosarcoma of the Breast: A Case Report

\*Aaron K M Sangma<sup>1</sup>, RK Bikramjit<sup>2</sup>, N Biplab Singh<sup>3</sup>, Th Bipin<sup>4</sup>,  
Niranjan Ganesh K<sup>5</sup>

Corresponding Author: \*Aaron K M Sangma1

**Abstract:** Primary osteogenic sarcoma of the breast is a very rare and aggressive tumor. It is associated mainly with haematogenous rather than lymphatic spread, making axillary dissection less important. Primary osteogenic sarcoma of the breast must be differentiated from clinically similar metaplastic carcinoma and malignant phyllodes because they differ biologically and in treatment approach as well. The diagnosis of primary osteosarcoma of the breast is mainly based on histopathology and immunochemistry. We report a 45 years old female with primary osteosarcoma of the breast. There is less than a hundred cases in literature on primary osteosarcoma of the breast, most being single case reports. Hence, due to the rarity of the disease, we are reporting this case.

Date of Submission: 18 -10-2017

Date of acceptance: 31-10-2017

### I. Introduction

Mammary sarcomas are extremely rare and make up < 1% of all primary breast malignancies.<sup>1,2</sup> Primary osteosarcomas of the breast are also extremely rare and represent about 12.5% of all primary mammary sarcomas.<sup>1,2</sup> Primary osteosarcomas of the breast originates either from the breast tissue de novo or as a metaplastic differentiation of primary benign or malignant breast lesion.<sup>3</sup> In comparison, bone-producing spindle cell neoplasms with an epithelial origin, known as metaplastic (sarcomatoid) carcinomas, and malignant phyllodes tumors are more common.<sup>4</sup> In contrast to skeletal osteosarcoma affecting mainly young patients, primary osteosarcomas of the breast occurs in older patients, with mean age at presentation around 65 years.<sup>5</sup> There are very few case reports on primary osteosarcoma of the breast because of its uncommon occurrence, most being single case reports. We report this case for its rarity.

### II. Case Report

A 45 years old woman right-sided post-mastectomy, presented with generalized weakness, dyspnea, bloody sputum and fever for a duration of four days. Two years back a lump of 7-9cm was self-detected in her right breast. The lump was on the right outer quadrant around 7-9 cm away from the nipple, irregular in outline, firm, with mild tenderness that was partially mobile with no skin dimpling, nor there was any discharge from the nipple. Patient underwent right sided radical mastectomy at another hospital three months after her presentation (Figure- 1).

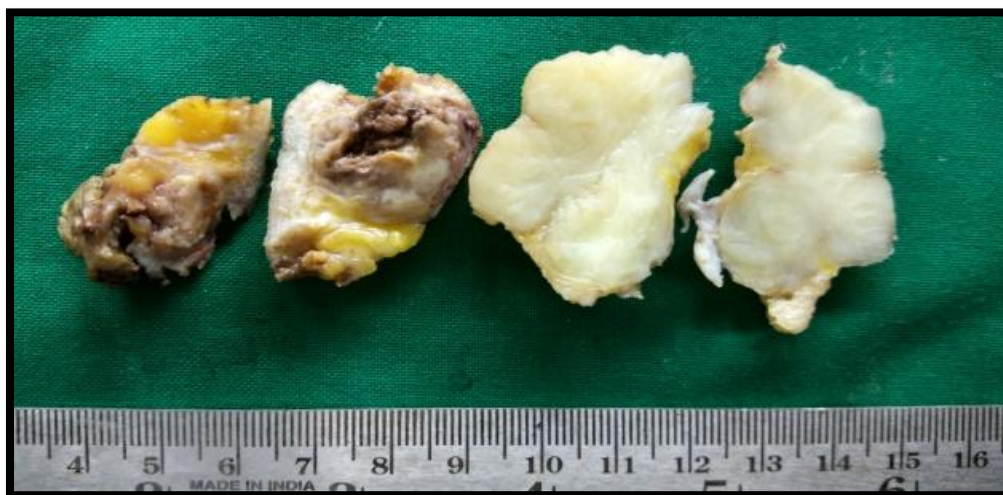
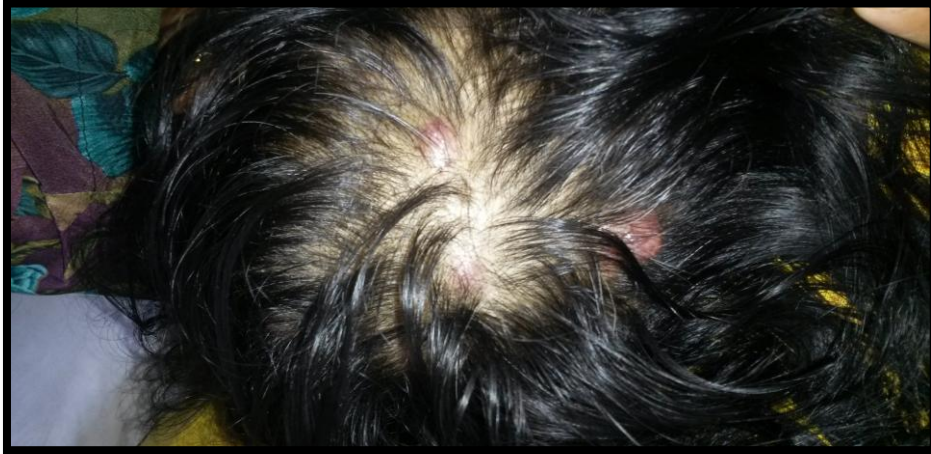

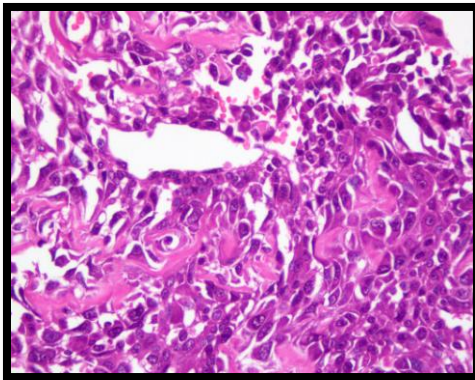
Figure 1- Showing the mastectomy specimen.

The biopsy was reported as phyllodes and no post-operative treatment was given. Examination revealed 2x6cm subcutaneous nodule on the right chest wall around previous mastectomy scar. There were also multiple subcutaneous nodules over the scalp (Figure- 2).

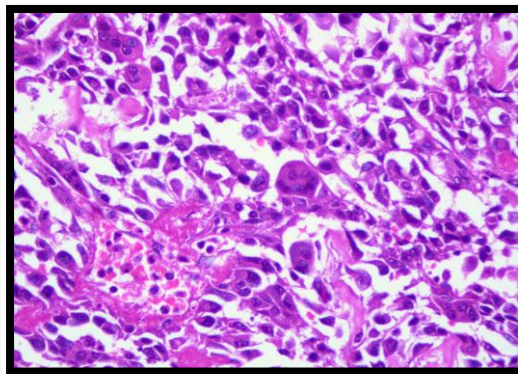


**Figure 2-** Showing multiple subcutaneous nodules over the scalp.

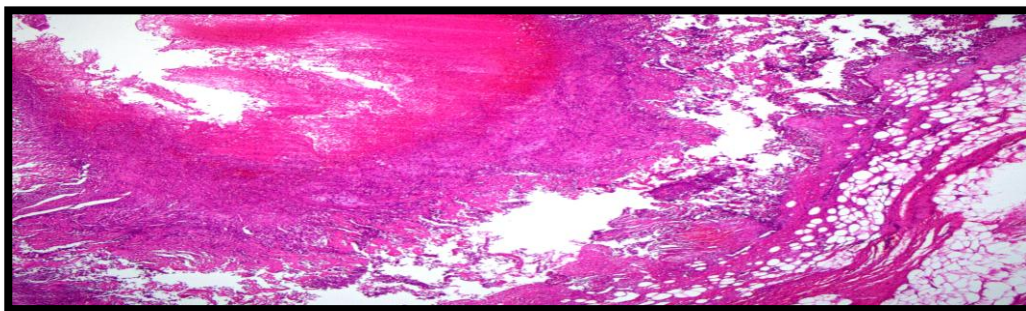
Chest X-Ray had metastatic pulmonary nodules in accordance with the clinical picture and adding to it, axial NCCT and CECT scan of the chest inferred multiple pulmonary nodules, mediastinal lymph nodal mass and subcutaneous nodules suggesting metastasis. Ultrasonography whole abdomen revealed fatty liver, ovarian cyst of 32x33mm and pelvic inflammatory disease. All the laboratory parameters were normal except for serum alkaline phosphatase that was elevated to 626. A biopsy of the chest wall nodule revealed numerous abnormal mitotic figures with areas of hemorrhage and necrosis are seen. Many areas show malignant osteoid surrounded by the tumor cells. Also seen are many scattered osteoclast type of giant cells. Large telangiectatic blood filled spaces lined by tumor cells are seen. Axillary lymphnode shows malignant tumor composed of spindle cells arranged in intersecting fascicles and in herring bone pattern. Individual tumor cells have pleomorphic vesicular nuclei. Mitotic figures (>20/10 hpfs) are seen. Peripheral areas show tumor cells invading into bundles of skeletal muscle altogether an indication of primary telangiectatic osteogenic sarcoma of the breast (Figure 3, 4 and 5).



**Figure- 3**



**Figure- 4**



**Figure- 5**

Immunohistochemistry of the tumour cells showed positivity for vimentin and osteopontin whereas it was non-reactive for cytokeratin, estrogen receptor [ER], proliferation rate [PR] and human epidermal growth factor receptor 2 [HER2 neu]. In view of the poor performance status, chemotherapy could not be given. She developed massive hemoptysis and expired.

### III. Discussion

Osteosarcoma is defined as a malignant tumor composed of spindle cells that produce osteoid and/or bone together with cartilage in some cases.<sup>6</sup> From the limited literature available, primary osteosarcoma of the breast generally occurs at 65 years. In our case, the occurrence was earlier, it was at the age of 45 years. The actual incidence is difficult to determine, because some of the approximately 100 previously-reported cases included metaplastic carcinomas, osteogenic sarcomas arising in association with phyllodes tumor and carcinoma.<sup>5,7</sup> It is possible to recognize the former by the presence of carcinomatous component or cytokeratin immunopositivity on hematoxylin and eosin sections and the latter by specific morphological features.<sup>8</sup> A secondary lesion from a primary osteosarcoma of the bone should be considered in the differential diagnosis. Diagnosis of primary breast osteosarcoma requires the absence of a direct connection between the tumor and the underlying skeleton.<sup>9,10</sup> A preoperative diagnosis is uncommon and most patients have a correct diagnosis only after histological examination of the surgically excised specimen. FNAC in osteosarcoma of breast is not diagnostic as pleomorphic spindle cells, osteoclastic giant cells and plaques of osteoid is seen in both metaplastic carcinoma and malignant phyllodes tumor. Since there are very few cases reported on this case, very little is known about the treatment guidelines and long term prognosis. In a study of 50 patients, a 5-year survival of 38% was observed, 28% developed local recurrence and 41% distant metastasis. In contrast to primary carcinoma of breast, where the spread is mainly through lymphatics, primary breast osteosarcoma spreads more commonly through hematogenous route. Haematogenous metastases most commonly occur to the lungs (80%), bone (20%) and liver (17%). Prognostic factors include tumor size, number of mitoses, presence of stromal atypia, histological type and resection margin involvement.<sup>7</sup>

Thus we can conclude that primary osteosarcoma of the breast is a very rare malignancy, mostly diagnosed after resection and still it needs to be differentiated from other osteoid/bone producing metaplasia by immunohistochemistry for confirmation. Surgical removal with an adequate margin with or without axillary lymph node dissection remains the mainstay of treatment since axillary node involvement is exceptional. Keeping in mind the rare histologic possibilities, early and correct histological diagnosis is needed for the appropriate treatment.

### References

- [1]. Bahrami A, Resetkova E, Ro JY, Ibañez JD, Ayala AG. Primary osteosarcoma of the breast: Report of 2 cases. *Arch Pathol Lab Med.* 2007;131:792-5.
- [2]. Blanchard DK, Reynolds CA, Grant CS, Donohue JH. Primary nonphyllodes breast sarcomas. *Am J Surg.* 2003;186:359-61.
- [3]. Kaul R, Julka PK, Lakshmi J et al. Osteosarcoma of the breast: A case report. *Bahrain Med Bull.* 2000;22(4):86-87.
- [4]. Rakha EA, Tan PH, Shaaban A et al. Do primary mammary osteosarcoma and chondrosarcoma exist? A review of a large multi-institutional series of malignant matrix-producing breast tumours. *Breast.* 2013;22:13-18.
- [5]. Vorobiof G, Hariprasad G, Freinkel W, Said H, Vorobiof DA. Primary osteosarcoma of the breast: A case report. *Breast J.* 2003;9(3):231-33.
- [6]. Tavassoli FA, Devilee P. World Health Organisation-pathology of genetics of tumours of the breast and female genital organs. Lyon: IARC, WHO classification of tumours. 2003;4:97-98.
- [7]. Silver SA, Tavassoli FA. Primary osteogenic sarcoma of the breast. A clinicopathologic analysis of 50 cases. *Am J Surg Pathol.* 1998;22:925-33.
- [8]. Adenm C, Reynolds J, Ingle N, Nascimento G. Primary breast sarcoma: clinicopathologic series from the Mayo Clinic and review of the literature. *Brit J of Cancer.* 2004;91(2):237-41.
- [9]. Momoi H, Wada Y, Sarumaru S, Tamaki N, Gomi T, Kanaya S et al. Primary osteosarcoma of the breast. *Breast Can* 2004;11(4):396-400.
- [10]. Ellman A, Jawa ZM, Maharaj M. Primary osteogenic sarcoma of the breast detected on skeletal scintigraphy. *Clin Nucl Med.* 2006;31(8):474-75.

\*Aaron K M Sangma. "Primary Osteosarcoma of the Breast: A Case Report." *IOSR Journal of Dental and Medical Sciences (IOSR-JDMS)*, vol. 16, no. 10, 2017, pp. 59-61.