

## Ex Vivo URS for Removal of Bilateral Renal Calculi in Cadaveric Kidney Prior to Transplant

<sup>1\*</sup>Dr. Renu Thomas MBBS MS DNB MCh

<sup>2</sup>Dr. Vipin Das P.R MBBS MS DNB Urology (Senior Resident)

Corresponding Author: \*Dr. K.R Vikraman MBBS MS MCh

---

**Abstract:** 59 year old gentleman with history of fall from height sustained severe head injury and was admitted in Neurosurgery ICU. After the patient was declared brain dead his family members agreed for organ donation. CT abdomen taken at the time of admission showed bilateral multiple renal calculi. Dilemma was whether to go ahead with renal transplantation or not. Consensus was reached and decided to do ex vivo URS and clearance of calculi before transplantation. Thus after harvesting both kidneys, bench surgery was done and bilateral URS was done using 7.5 /6 Fr semi rigid ureteroscope and all calculi were basketted out. Both kidneys were transplanted to patients in same centre. Previously, donors with asymptomatic stones found incidentally on CT were not considered ideal donor candidates because of the presumed risk of morbidity to both the donor and recipient. Increasingly, studies show that these risks are low. Ex vivo ureteroscopy has been used to remove stones from the donor kidney on the bench before donation. This case is unique in a way that usually clearance of calculi is done before live donor renal transplantations and reports of clearance of calculi before cadaveric renal transplantation is rarely reported.

**Keywords:** Ex vivo URS, donor kidney lithiasis, renal transplant

---

Date of Submission: 29 -07-2017

Date of acceptance: 30-09-2017

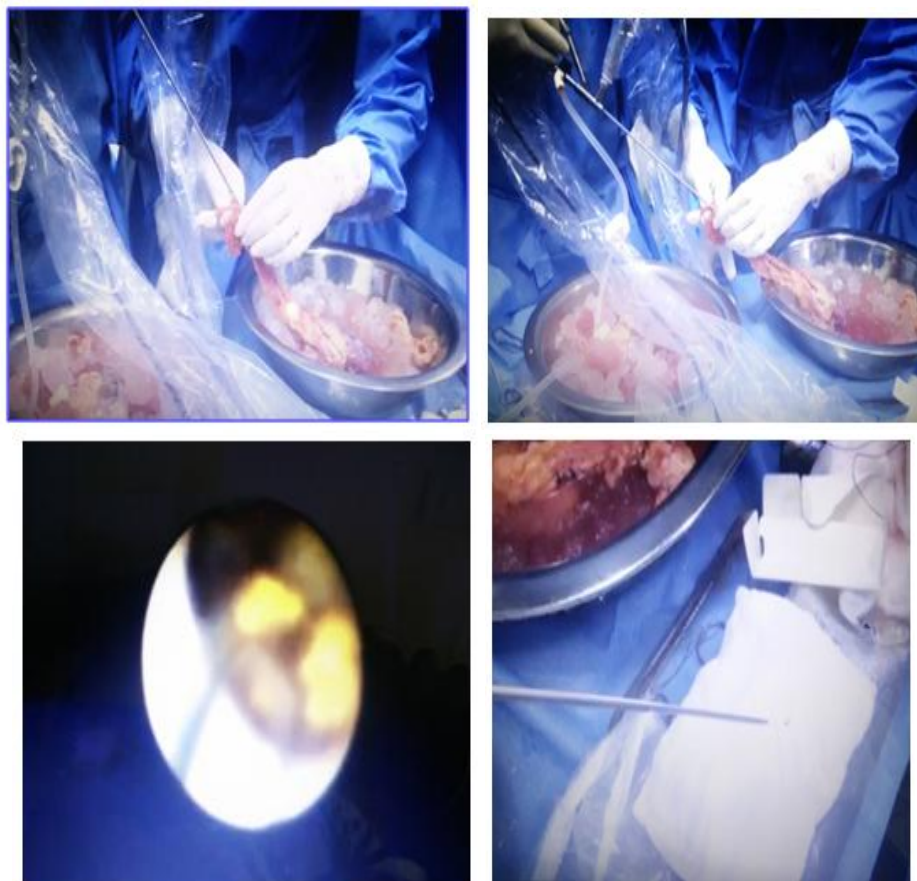
---

### I. Introduction

The general consensus is to remove upper tract stones within renal transplants as obstructing stones can cause significant morbidity and has the potential of impairing graft function. Indeed, because of lack of innervation in renal transplants, obstructing stones do not manifest with typical renal colic. Rather vague discomfort, fevers, oliguria, hematuria, or rising creatinine may be the only presenting signs.

### Case Presentation

59 year old male patient was brought to emergency room with history of fall from height. He had no known co morbidities. His CT head showed massive intracranial bleed and CT abdomen showed bilateral renal calculi (maximum size- 4mm) with no evidence of solid organ injury. Over two days, he was declared brain dead. After obtaining consent from relatives, it was decided to proceed with harvesting his organs for cadaveric transplant. It was decided to harvest liver, kidneys and eyes. It was planned to do ex vivo URS after harvesting kidneys. Kidneys were harvested separately after insitu perfusion, following the standard procedure of cadaveric harvest. After harvesting both kidneys bench surgery was done. URS was done using 6/7.5 Fr semi rigid ureteroscope. Multiple renal calculi were found (maximum size- 4mm), which were basketted out. Both kidneys were transplanted to patients in same centre and both patients had an uneventful post operative period. Post operative doppler study showed normal functioning graft kidney and there was no evidence of any renal calculi.



## II. Discussion

Obstructing ureteric calculi can cause deleterious effects on graft function. Due to lack of innervation in the graft kidney, obstructing stones do not manifest with typical renal colic. Rather vague discomfort, fever, oliguria, hematuria, or rising creatinine may be the only presenting signs. SWL has been described for stones in transplant kidneys and is an option for stones smaller than 1.5 cm; however, high re-treatment rates and auxiliary procedure rates should be expected. Ante grade and retrograde URS have been used to successfully treat transplant kidney and ureteral stones. PCNL remains the preferred treatment choice for large burden stones (>1.5 cm) or if less invasive methods have failed. Stone free rates ranging from 77 % to 100 %, similar to rates in general population, have been reported. Previously, donors with asymptomatic stones found incidentally on CT were not considered ideal donor candidates because of the presumed risk of morbidity to both the donor and recipient. Increasingly, studies show that these risks are low. Outcomes so far suggest that ex vivo URS can safely render a kidney stone-free before transplantation.

## III. Conclusion

Ex vivo URS is technically feasible to render a stone-bearing kidney stone-free without compromising ureteral integrity or renal allograft function. Inclusion of stone bearing kidneys would increase the donor pool of kidneys.

## References

- [1]. Assimos DG. Re: Stone disease in living-related renal donors: long-term outcomes for transplant donors and recipients. *J Urol*. 2014 Aug; 192(2):440.
- [2]. Pushkar P, Agarwal A, Kumar S, Guleria S. Endourological management of live donors with urolithiasis at the time of donor nephrectomy: a single center experience. *Int Urol Nephrol*. 2015 Jul; 47(7):1123-7.
- [3]. Thomas SM, Lam NN, Welk BK, Nguan C, Huang A, Nash DM, Prasad GV, Knoll GA, Koval JJ, Lentine KL, Kim SJ, Lok CE, Garg AX; Donor Nephrectomy Outcomes Research (DONOR) Network. Risk of kidney stones with surgical intervention in living kidney donors. *Am J Transplant*. 2013 Nov; 13(11):2935-44.
- [4]. Olsburgh J, Thomas K, Wong K, Bultitude M, Glass J, Rottenberg G, Silas L, Hilton R, Koffman G. Incidental renal stones in potential live kidney donors: prevalence, assessment and donation, including role of ex vivo ureteroscopy. *BJU Int*. 2013 May; 111(5):784-92.

- [5]. Ganpule A, Vyas JB, Sheladia C, Mishra S, Ganpule SA, Sabnis RB, Desai M. Management of urolithiasis in live-related kidney donors. *J Endourol.* 2013 Feb; 27(2):245-50.
- [6]. Saxena S, Sadideen H, Goldsmith D. Treating stones in transplanted kidneys. *Minerva Med.* 2013 Feb; 104(1):31-40.
- [7]. Kim IK, Tan JC, Lapasia J, Elihu A, Busque S, Melcher ML. Incidental kidney stones: a single center experience with kidney donor selection. *Clin Transplant.* 2012 Jul-Aug; 26(4):558-63.
- [8]. Lechevallier E, Saussine C, Traxer O. [Renal transplantation and urinary lithiasis]. *Prog Urol.* 2008 Dec; 18(12):1024-6.
- [9]. Kar PM, Popili S, Hatch D. Renal transplantation: donor with renal stone disease. *Clin Nephrol.* 1994 Nov; 42(5):347-8.

\*Dr. Renu Thomas MBBS MS DNB MCh . "Ex Vivo URS for Removal of Bilateral Renal Calculi in Cadaveric Kidney Prior to Transplant." *IOSR Journal of Dental and Medical Sciences (IOSR-JDMS)* 16.10 (2017): 73-75