

## Mirizzi syndrome type IV: A case report

\*Ismail Alnjadat M.D.<sup>#1</sup>, Fadi Maaitah M.D.<sup>1</sup>, Khaled Abu Rumman\* M.D.,  
Ala Odeh\* M.D., Rasha Al\_Jalamdeh R.N<sup>2</sup>, Ghaith Gsous\* M.D

<sup>1</sup> Prince Hashim Bin Abdullah II Hospital, Department of General surgery

<sup>2</sup> Prince Hashim Bin Abdullah II Hospital, Department of nursing

\*king Hussien Hospital, Department of General Surgery

Corresponding Author: Ismail Alnjadat M.D

### Abstract:

**Introduction:** Mirizzi Syndrome (MS) is a rare complication of chronic cholelithiasis triggered by impacted calculus in Hartmann pouch or cystic duct. Type IV is complete destruction of the bile duct and represents the most uncommon type. We reported a case of Mirizzi syndrome type IV discovered during elective laparoscopic cholecystectomy.

**Case report:** A 35 year female was found during elective laparoscopic cholecystectomy to have abnormal anatomy. Intraoperative cholangiogram and conversion to open approach confirmed the diagnosis of Mirizzi syndrome type IV. Cholecystectomy and hepaticojunostomy were done. Recovery was uneventful.

**Conclusion:** surgeons performing laparoscopic cholecystectomy should be aware of the possibility of Mirizzi syndrome. They should have a low threshold for intraoperative cholangiogram and hepatobiliary surgeons consultation.

Date of Submission: 31 -07-2017

Date of acceptance: 27-10-2017

### I. Introduction

Mirizzi Syndrome (MS) is a rare complication of chronic cholelithiasis triggered by impacted calculus in Hartmann pouch or cystic duct, causing extrinsic obstruction of the common hepatic duct<sup>(1)</sup>. Preoperative diagnosis on the basis of clinical presentation and investigations is not possible in majority of patients. Due to inflammation and complete obliteration of Calot's triangle, cholecystectomy, either by open or laparoscopic approach, poses a significant risk of bile duct injury<sup>(2)</sup>.

Incidence of MS is reported to be less than 1%. Csendes originally classified MS into four types (figure 1): type I includes those with external compression of the common bile duct (CBD); type II is a cholecystobiliary fistula presenting with erosion of less than one third of the circumference of the bile duct; type III is a fistula involving up to two-thirds of the duct circumference; and type IV is complete destruction of the bile duct. MS type IV represents the most uncommon type<sup>(3,4)</sup>.

We reported a case of MS type IV found intraoperatively during elective laparoscopic cholecystectomy.

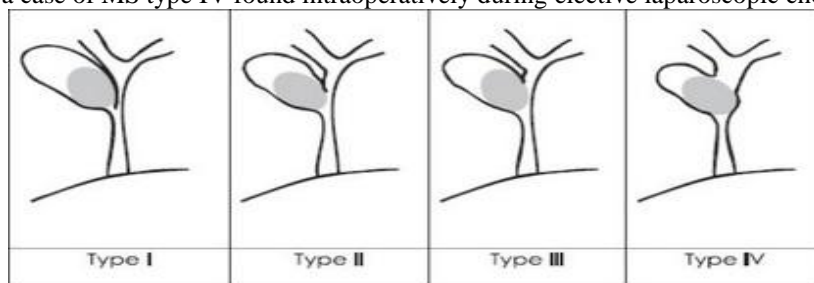


Figure (1): Mirizzi syndrome classification according to Csendes

### Case report:

A 35 year old female patient was admitted for elective laparoscopic cholecystectomy for symptomatic cholelithiasis on April 15, 2016. The patient had no previous surgical or medical history. On physical exam the patient looked well, afebrile, not tachycardic, pale or jaundiced. Her abdomen examination revealed mild right upper quadrant tenderness with negative Murphy sign and no palpable masses. Her laboratory tests showed normal white blood cell count, hemoglobin, bilirubin and liver enzymes. Her preoperative ultrasound showed only multiple gall bladder (GB) stones with no pericholecystic fluid and normal CBD. The procedure started

with introducing 10mm optical trocar using open technique. Three more trocars were inserted under vision. After fundus retraction, Calot's triangle was not clearly visualized. After meticulous dissection, a structure supposed to be the cystic duct (CD) was identified and dissected free. Because we were in doubt about that structure decision was made to perform intraoperative cholangiogram through that duct which showed the dye passing directly into the duodenum without any visualization of proximal biliary system. Decision then was made to convert to open technique through right subcostal incision. We confirmed that the structure once supposed to be a CD was indeed the CBD and there was no any CD. The CBD distal part measured about 1.5 cm in length but proximally it completely emerged with the lumen of the GB forming as a continuation or part of it and at this moment diagnosis of MS type IV was made. Proximal to the GB-CBD complex the common hepatic duct was found to be full of stones. Hepatobiliary surgeons were consulted and they confirmed our diagnosis and perform cholecystectomy and hepaticojejunostomy. The patient was discharged on postoperative day 7 with uneventful recovery.

## II. Discussion

The Mirizzi syndrome refers to common hepatic duct obstruction caused by an extrinsic compression from an impacted stone in the CD or Hartmann's pouch of the GB. Mirizzi reported his syndrome for the first time in 1940<sup>(5)</sup>. The pathophysiological process leading to the subtypes of MS has been explained as an inflammatory phenomenon secondary to a pressure ulcer caused by an impacted gallstone which can cause first external obstruction of the bile duct and eventually erodes into the bile duct evolving into a cholecystocholedochal fistula with different degrees of communication between the GB and bile duct. Anatomical variations with long CD parallel to the common hepatic duct or a low insertion of the cystic duct predispose to development of this syndrome<sup>(6,7)</sup>.

MS appears in 1% to 2% of patients with symptomatic cholelithiasis with higher incidence in Central and South America where the reported incidence is 4.7% to 5.7% with type IV the most uncommon type<sup>(4,8)</sup>. Reverdito R et al<sup>(1)</sup> reported 12 cases of MS type IV in 3,691 cholecystectomies performed from December 2001 to September 2013 with incidence of 0.3%. Kulkarni SS et al<sup>(9)</sup> reported MS in 60 patients out of 4939 patients (1.21 % incidence) who underwent cholecystectomy over 6 years, none of these 60 patients had type III or IV MS. Ashok Kumar et al<sup>(9)</sup> found MS in 169 patients among 8000 cholecystectomies performed between 1989 and 2011, and only 10 of them had type IV. Testini M et al<sup>(10)</sup> reported 18 cases of MS over 10 years with only one of them had type IV. Similarly, Kamalesh NP et al<sup>(11)</sup> found 20 patients with MS among 1530 cholecystectomies, only one patient had MS type IV. Among 8697 cholecystectomies, Xu XQ et al<sup>(12)</sup> reported 27 patients with MS, none of them was type IV. Lastly, Cui Y et al<sup>(13)</sup> found 198 cases of MS among 29 875 patients who underwent cholecystectomy for cholelithiasis, only 6 patients had type IV. The case we reported has been the first case of MS type IV during 8 year experience at our institution.

The clinical diagnosis of MS is difficult, since there are no pathognomonic patterns of presentation. Ultrasonography and CT scan were diagnostic in only 10% patients, with ERCP and/or MRCP to confirm the diagnosis. Despite of all these modern diagnostic tools, the problem may become apparent only during surgery. At this situation, as in our case, old is still gold and intraoperative cholangiogram can provide a clearer picture of the anatomy and hence reduce the risk of injury to CBD.<sup>(2, 14,15)</sup>

Surgical management of Csendes type IV MS is well established as the procedure of choice is cholecystectomy with Roux-en-Y hepatico-jejunostomy<sup>(1,2,4,15)</sup>.

## III. Conclusion

Surgeons should be aware of the possibility of MS during laparoscopic cholecystectomy. Difficulty in identifying structures at Calot's triangle, presence of abnormal anatomic relations or abnormal size CD should alert the surgeon to the presence of biliary anomaly. There should be a low threshold for intraoperative cholangiogram and consultation of experienced hepatobiliary surgeons.

## References

- [1]. Reverdito R, Moricz AD, Campos TD, Pacheco AM Júnior, Silva RA. Mirizzi syndrome grades III and IV: surgical treatment. *Rev Col Bras Cir.* 2016 Jul-Aug;43(4):243-7.
- [2]. Ashok Kumar, Ganesan Senthil, Anand Prakash, Anu Behari, Rajneesh Kumar Singh, Vinay Kumar Kapoor, et al. Mirizzi's syndrome: lessons learnt from 169 patients at a single center. *Korean J Hepatobiliary Pancreat Surg.* 2016 Feb; 20(1): 17–22.
- [3]. Yonetcı N, Kutluana U, Yılmaz M, Sungurtekin U, Tekin K. The incidence of Mirizzi syndrome in patients undergoing endoscopic retrograde cholangiopancreatography. *Hepatobiliary Pancreat Dis Int.* 2008 Oct;7(5):520-4.
- [4]. Daniel Navarini, Carlos Augusto Scussel Madalosso, Diego Reffatti, Luma Guareschi, Ana Paula Schmitt, Guilherme Marx, et al. Mirizzi Syndrome Type IV: A challenging diagnosis. *Clinical & Biomedical Research.* 2016, Vol. 36 Issue 1, p44-46.

- [5]. Marcelo A Beltrán. Mirizzi syndrome: History, current knowledge and proposal of a simplified classification. *World J Gastroenterol.* 2012 Sep 14; 18(34): 4639–4650.
- [6]. Fahri Yetişir, Akgün Ebru Şarer, H. Zafer Acar, et al. Laparoscopic Treatment of Type III Mirizzi Syndrome by T-Tube Drainage. *Case Reports in Surgery.* Volume 2016 (2016), Article ID 1030358, 5 pages.
- [7]. K. Rayapudi, P. Gholami, M. Olyae. Mirizzi Syndrome with Endoscopic Ultrasound Image. *Case Rep Gastroenterol.* 2013 May-Aug; 7(2): 202–207.
- [8]. Dario Pariani, Giorgio Zetti, Fausto Galli, Ferdinando Cortese. Mirizzi Syndrome: From Ultrasound Diagnosis to Surgery—A Case Report. *Case Reports in Surgery.* 2013;2013:268760.
- [9]. Kulkarni SS, Hotta M, Sher L, et al. Complicated gallstone disease: diagnosis and management of Mirizzi syndrome. *Surg Endosc.* 2016 Sep 1.
- [10]. Testini M, Sgaramella L, De Luca GM, et al. Management of Mirizzi Syndrome in Emergency. *J Laparoendosc Adv Surg Tech A.* 2016 Sep 9.
- [11]. Kamallesh NP, Prakash K, Pramil K, George TD, Sylesh A, Shaji P. Laparoscopic approach is safe and effective in the management of Mirizzi syndrome. *J Minim Access Surg.* 2015 Oct-Dec;11(4):246-50.
- [12]. Xu XQ1, Hong T, Li BL, Liu W, He XD, Zheng CJ. Mirizzi syndrome: our experience with 27 cases in PUMC Hospital. *Chin Med Sci J.* 2013 Sep;28(3):172-7.
- [13]. Cui Y1, Liu Y, Li Z, Zhao E, Zhang H, Cui N. Appraisal of diagnosis and surgical approach for Mirizzi syndrome. *ANZ J Surg.* 2012 Oct;82(10):708-13.7.
- [14]. Michael Safioleas, Michael Stamatakos, Constantinos Revenas, Constantinos Chatziconstantinou, Constantinos Safioleas, Alkiviades Kostakis. An alternative surgical approach to a difficult case of Mirizzi syndrome: A case report and review of the literature. *World J Gastroenterol.* 2006 Sep 14; 12(34): 5579–5581.
- [15]. Keta L Keens, Kishore G Pursnani, Jeremy B Ward, Ravindra S Date. Old is still gold. *BMJ Case Rep.* 2013; 2013: bcr2012007798.

\*Ismail Alnjadat M.D. "Mirizzi syndrome type IV: A case report." *IOSR Journal of Dental and Medical Sciences (IOSR-JDMS)* 16.10 (2017): 70-72