

Management of Borderline Ovarian Tumour in A Pregnant Woman: A Case Report

Khoinaijam Neelam¹, Akoijam Usharani², G.Dheepthambiga³, Romey Rai⁴
Junior Resident¹, Assistant Professor², Junior Resident^{3,4}

Abstract: Borderline ovarian tumors (BOTs) are neoplasms with benign and malignant characteristics, affecting young women in childbearing age. Finding incidental adnexal mass in pregnancy is more common with the use of ultrasound, incidence is about 2% to 10% of pregnancies. Treatment varies depending upon the gestational age: before 24 weeks of period of gestation treatment is usually conservative and surgical staging. Radical management is reserved to patients with suspected malignancy. A 27-years-old woman with period of gestation 32 weeks 5 days of her first pregnancy presented with ultrasound showing right adnexal mass of size 25.6cmx16.3cmx17.2cm. She underwent elective cesarean and exploratory laparotomy, surgical findings were: a preterm male baby with no obstetric complications and a right ovarian cyst with histopathological report showing mucinous epithelial cells with atypia, suggestive of ovarian borderline tumor. Right sided salpingectomy with oophorectomy done. Post operative recovery was normal.

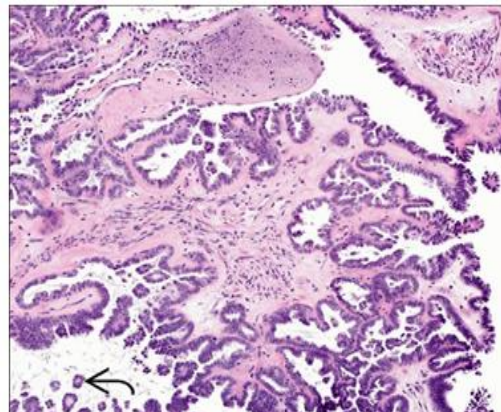
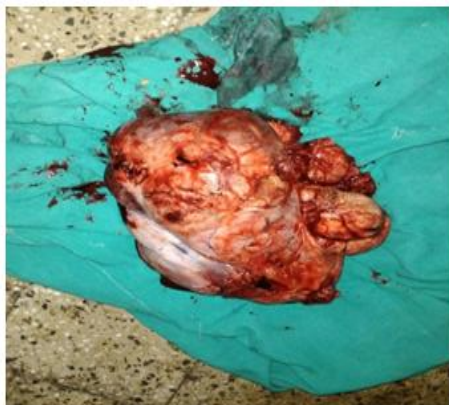Keywords: Pregnant, Borderline, Ovarian Tumour

I. Introduction

Borderline ovarian tumors (BOTs) are defined as an entity with histopathological characteristics between benign and malignant neoplasm^[1]. These tumors account for almost 10%-20% of ovarian neoplasms^[2]. There are often seen in young women whom are in childbearing age. They have a good prognosis in early stages and in absence of peritoneal implants^[3]. There are described three subtypes: serous, mucinous and clear cells, being the first the most common (65%)^[4]. The great majority of high suspicion adnexal masses excised during pregnancy are in fact BOTs. We present a case of a pregnant woman with a borderline ovarian tumor in a tertiary Hospital.

II. Case Presentation

A 27 years old woman presented to Regional Institute of Medical Sciences hospital, Imphal with period of gestation 32 weeks of her first pregnancy in labour. She was asymptomatic and physical examination was normal. Obstetric ultrasound reported: right ovarian mass, 25.6 cm x 16.3 cm x 17.2 cm in size, heterogeneous, with cystic and solid areas, no calcifications and diffused and non-defined borders. Laboratory data and tumor markers were normal. She underwent emergency cesarean and exploratory laparotomy surgical findings were: a preterm male baby with no obstetric complications and a right ovarian tumor measuring 24cm x 28 cm weighing 2.7 kg, heterogeneous whit cystic and solid components. Right sided salpingectomy with oophorectomy was done. No complications were reported. Post-operative recovery was normal. Patient was discharged at fourth post-operative day. Follow up was at 3, 6 and 12 post-operative months with laboratory and ultrasound, showing no evidence of recurrence. Definitive histopathological study reported an ovarian tumor with capsular integrity; neoplastic cells delimited by a fibroconjunctive and vascularized wall, coated with cylindrical cells with irregular nucleus, without evidence of stromal invasion, with papillary formations that bulge through the oviduct lumen.



III. Discussion

BOTs are an intermediate histological entity between benign and invasive ovarian tumor; representing almost 10%-20% of all ovarian epithelial tumors^[5]. Previous studies in pregnant patients with adnexal masses have reported an incidence of BOTs of 0.15% to 3%^[6]. BOTs are frequently diagnosed during the first trimester and usually they are detected in routine imaging studies^[6]. These tumors can be treated conservatively by adnexectomy and peritoneal cytology and exploration with biopsies, never lead to the end of the pregnancy and should be performed without rupture^[7]. It is mostly done by laparotomy, but laparoscopic surgery may be an option before 24 weeks^[8]. Cystectomy is associated with a higher recurrence rate (up to 31%)^[9]. It should be performed only for patients with bilateral tumors and/or only one ovary; it was associated with a higher rate of intraoperative cyst rupture, and with the knowledge that is not safe in patients with mucinous borderline tumors because is associated with an increased risk of recurrence in the form of invasive carcinoma, but is an acceptable option for women who plan further pregnancies^[10]. If borderline tumor is revealed by the histology of a surgical specimen, it seems reasonable to defer surgical treatment until after delivery and the surgical staging should be completed 3-6 weeks after delivery^[10]. Spontaneous conception is reported after conservative surgery in 50% of patients without any deterioration in the survival rates^[10].

Follow-up is usually a combination of clinical examination, ultrasound, and CA125 levels. During the initial two years, follow-up evaluation is performed every three months. Patients are then evaluated biannually for 3-5 years after surgery, and then annually thereafter. Transvaginal and transabdominal ultrasound are the optimal techniques for the surveillance because of their high ability to detect discrete intraovarian abnormalities as well as extraovarian implants^[11].

IV. Conclusion

The importance of this case is to reaffirm the diagnostic criteria and therapeutic measures to be taken into account in a pregnant woman with suspicious findings in ultrasound and intraoperative report showing borderline ovarian tumor. Although current publications refer to a conservative surgery in women who want to conserve fertility, there is clear evidence that radical surgery offers the lowest rates of recurrence, therefore we consider that treatment in a patient with satisfied parity, poor prenatal care and without adequate diagnostic tools and in the third trimester of pregnancy, should be a candidate to perform caesarean section with a radical surgery.

References

- [1]. Karseladze AI. WHO histological classification of ovarian tumors. *Arkh Patol.* 2005; Suppl: 1-64. PMID: 16108150.
- [2]. Lorusso D, Ratti M, Ditto A, et al. High-risk borderline ovarian tumors: analysis of clinicopathological features and prognostic impact of different follow-up strategies. *Oncology.* 2014; 87(3): 183-92.
- [3]. Hannibal CG, Vang R, Junge J, et al. A nationwide study of serous "borderline" ovarian tumors in Denmark 1978-2002: centralized pathology review and overall survival compared with the general population. *Gynecol Oncol.* 2014; 134(2): 267-73. <http://dx.doi.org/10.1016/j.ygyno.2014.06.002>
- [4]. Seidman JD, Kurman RJ. Pathology of ovarian carcinoma. *Hematol Oncol Clin North Am.* 2003; 17(4): 909-25, vii. [http://dx.doi.org/10.1016/S0889-8588\(03\)00061-3](http://dx.doi.org/10.1016/S0889-8588(03)00061-3).
- [5]. Fauvet R, Brzakowski M, Morice P, et al. Borderline ovarian tumors diagnosed during pregnancy exhibit a high incidence of aggressive features: results of a French multicenter study. *Ann Oncol.* 2012; 23(6): 1481-7.
- [6]. Sherard GB, Hodson CA, Williams HJ, et al. Adnexal masses and pregnancy: a 12-year experience. *Am J Obstet Gynecol.* 2003; 189(2): 358-62; discussion 362-3. [http://dx.doi.org/10.1067/S0002-9378\(03\)00731-2](http://dx.doi.org/10.1067/S0002-9378(03)00731-2).
- [7]. Van Calster B, Van Hoorde K, Valentin L, et al. International Ovarian Tumour Analysis Group. Evaluating the risk of ovarian cancer before surgery using the ADNEX model to differentiate between benign, borderline, early and advanced stage invasive, and secondary metastatic tumours: prospective multicentre diagnostic study. *BMJ.* 2014; 15: 349:g5920. <http://dx.doi.org/10.1136/bmj.g5920>
- [8]. du Bois A, Ewald-Riegler N, de Gregorio N, et al. Gynäkologische Onkologie (AGO) Study Group. Borderline tumours of the ovary: A cohort study of the Arbeitsgemeinschaft Gynäkologische Onkologie (AGO) Study Group. *Eur J Cancer.* 2013; 49(8): 1905- <http://dx.doi.org/10.1016/j.ejca.2013.01.035>
- [9]. Fischerova D, Zikan M, Dundr P, et al. Diagnosis, treatment, and follow-up of borderline ovarian tumors. *Oncologist.* 2012; 17(12): 1515-33. <http://dx.doi.org/10.1634/theoncologist.2012-0139>
- [10]. Yinon Y, Beiner ME, Gotlieb WH, et al. Clinica outcome of cystectomy compared with unilateral salpingo-oophorectomy as fertility-sparing treatment of borderline ovarian tumors. *Fertil Steril.* 2007; 88(2): 479-84. PMID: 17408624. <http://dx.doi.org/10.1016/j.fertnstert.2006.11.128>
- [11]. Morice P. Borderline tumours of the ovary and fertility. *Eur J Cancer.* 2005; 42(2): 149-58. PMID: 16326097. <http://dx.doi.org/10.1016/j.ejca.2005.07.029>