

Teratogenic Effect of Lamotrigine on Developing Liver of Swiss Albino Mice

Sharda Singh¹, S.K. Pandey¹, K.N. Dwivedi², Shweta Singh³

¹Department of Anatomy, Institute of Medical Sciences, Banaras Hindu University, India

²Department of Dravya Guna, Institute of Medical Sciences, Banaras Hindu University, India

³Department of Anatomy, Hind Institute of Medical Sciences, Barabanki, India

Abstract: The aim of present study was to observe the noxious effect of Lamotrigine (LTG) in growing liver of mice. The pregnant mice (20-25 g) were treated orally with LTG during organogenesis period i.e. 7th - 9th day of gestation. The treated group received 0.3 ml (60 mg/kg body wt) of stock solution of LTG, whereas the same volume of distilled water was given to control mice via same route. The foetuses of both control and treated group were collected on 18th day of gestation and kept in 10 % formalin for fixation. After 48 hours of fixation, liver were taken out from foetuses and observed for gross anomaly, if any and then photographed. Finally, liver of both groups were processed for histological study. On macroscopic examination, the treated liver showed increase in weight and haemorrhagic spots especially on their lateral and inferior surfaces. On microscopic examination the treated group of liver showed loss of normal architecture of hepatic cords, oedematous spaces in hepatic lobules, dilated sinusoids and central vein with destruction of their lining endothelium. The present study revealed that the lamotrigine causes noxious effect on growing liver, therefore its use in pregnant women may be advised by experts working in the field.

Key words: foetus, gestation, lamotrigine, liver, noxious, teratogenic.

I. Introduction

Lamotrigine (LTG) [3,5-diamino-6-(2,3-dichlorophenyl)-1,2,4-triazine] is one of the most frequently prescribed drug among the newer antiepileptic drugs during pregnancy [1]. Many reports and studies showed a free transplacental passage of lamotrigine [2,3,4,5]. Myllynen and colleagues, 2003 revealed that LTG crossed the placenta rapidly and was detected in foetal circulation as early as 15 min after drug administration into the maternal pool [6]. Therefore the treatment by LTG during pregnancy leads to considerable foetal exposure of the drug. In different experimental studies LTG at higher doses and multiple low doses was found to produce intrauterine growth retardation and other congenital malformations [7,8]. Ramadan F.L., 2014 showed that lamotrigine and radiation induced a significant elevation in serum gamma glutamyl transferase, α fetal protein and lactate dehydrogenase in placental tissue of pregnant rats associated with an increase of phosphorus content in liver of foetuses [9].

On the other hand, the long term treatment of adult male mice with LTG was found to cause a significant increase in the level of liver enzymes (ALP, AST, ALT) and bilirubin at therapeutic dose of LTG. The level of these enzymes and bilirubin at toxic dose were seen higher and showed a significant increase [10]. A significant increase in both ALT & AST liver enzymes, a decrease in TBARS content with an increase in the activities of both catalase and glutathione reductase enzymes was also reported in rats with induced convulsion, treated by LTG [11]. Hepatic failure and multi-organ failure has been reported in children as well as in adults by the use of LTG [12, 13, 14].

The previous studies have been reported the noxious effect of LTG mainly on adult liver. The teratogenic effect of LTG on the growing liver has been observed by Dr. Shweta Singh, 2013 in her thesis [15]. So the present study was based on the observation of thesis of Dr. Shweta Singh and the effect of LTG has been observed macro and microscopic changes in growing liver of foetuses exposed to lamotrigine, during organogenesis period.

II. Materials and Methods

The pregnant mice (each weighing 20-25 g) has been used as experimental animal for the present study, which were caged in air conditioned Animal house of Department of Anatomy, Institute of Medical sciences, Banaras Hindu University, Varanasi, 221005, India. Female mice were transferred to cage containing adult fertile males, overnight for mating and were inspected next morning for the presence of vaginal plug. The day of vaginal plug positive, was considered as day 0 of pregnancy. The experimental animals were divided into two groups i.e. control (4 mice) and treated (8 mice). The pregnant mice of treated group were given 0.3 ml of stock solution containing 1.5 mg of the drug, orally for three subsequent days i.e. 7th - 9th day of gestation. Same volume of distilled water was given to control mice via same route and duration. Mice of both the groups

were sacrificed by cervical dislocation on 18th day of gestation. Abdominal cavity of mice was opened and the foetuses were collected and kept in 10 % formalin for fixation. After 48 hours of fixation, liver was removed from the foetuses, then observed for gross anomalies and photographed. Finally, the liver from both control and treated groups was processed for microscopic study. Statistical analysis was done by student's independent t test to compare the mean weight of control and treated liver.

III. Observations and Results

On macroscopic examination weight of liver of treated group was found more as compared to control group but it was not statistically significant (TABLE 1). The graphical presentation of mean weight of liver of control and treated group has been shown by bar diagram (Fig.1). There was no any change in size and dimensions of the treated group as compared to their corresponding control group. The haemorrhagic patches were found on the various surfaces of treated liver, mainly on the inferior surface (Fig.2).

On microscopic examination the treated liver revealed the loss of normal pattern of hepatic cords and lobules of developing liver (Fig.3). It was also observed that the growing liver of the treated group showed oedematous appearance in the lobules, dilatation of the sinusoids and the central vein (Fig.4). In higher magnification treated liver showed disruption of lining epithelium of the central vein and the sinusoids along with pyknotic changes of the growing hepatoblasts cells (Fig.5). The clumping of degenerated hepatoblast cells has been also observed at some places.

IV. Discussion

The results of the present study showed the presence of haemorrhagic spots on lateral and inferior surface of fetal liver in treated group. An increase in mean weight of lamotrigine treated liver was observed as compared to control liver, but the difference was not statistically significant. Microscopically, dilatation of central vein, oedematous changes and the loss of normal pattern of parenchyma, pyknotic changes of the growing hepatoblasts was observed in the sections of liver of treated group as compared to control. Similar findings were also found by Shweta Singh, BHU in her thesis in the year 2013.

Histologically, liver development begins around E9.0- E9.5 as a diverticulum of proliferating endodermal cells arising from the ventral surface of the foregut [16]. Administration of LTG on gestation day (GD) 7, 8 and 9 may cause its metabolites to affect the development of liver adversely, as the organ is involved in metabolism of drug by glucuronidation.

The *o* dichlorophenyl moiety of lamotrigine suggests a potential for bioactivation to an arene oxide. Arene oxides are non radical oxidants and donot require free radicals as intermediates to oxidize thiols [17].Therefore oxidative stress might have occurred as a consequence of the disruption of thiol redox circuits which are controlled, among others, by glutathione reductase [18,19,20].

A study reported that antiepileptic drugs which induce hepatic CYP 450 enzyme system appear to be associated with vitamin K deficiency in the newborn. Their use can result in hemorrhagic disease of the newborn leading to intraparenchymal and intracerebral hemorrhage [21] could be the probable hypothesis for the haemorrhagic spots found on surfaces of the liver .

V. Figures and Tables

Table 1 showing liver weight of control and treated groups

	Group	N	Mean	SD	SE	p value
Liver weight	Control	30	.0569	.0225	.0079	0.146
	Treated	30	.0734	.0238	.0072	

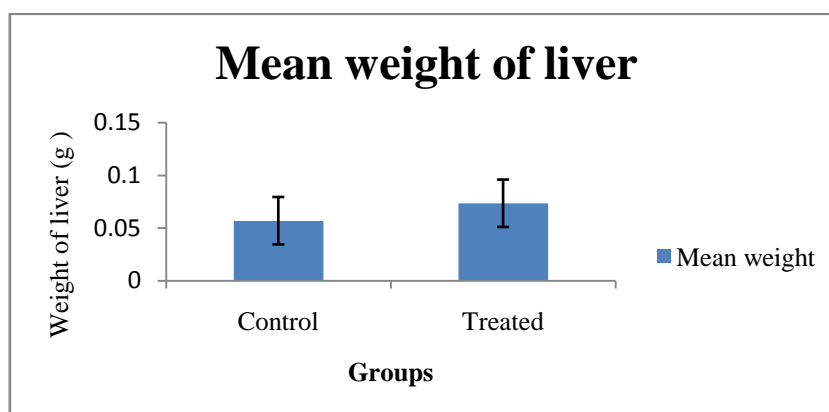



Figure1. Bar diagram showing mean weight of liver of control and treated groups

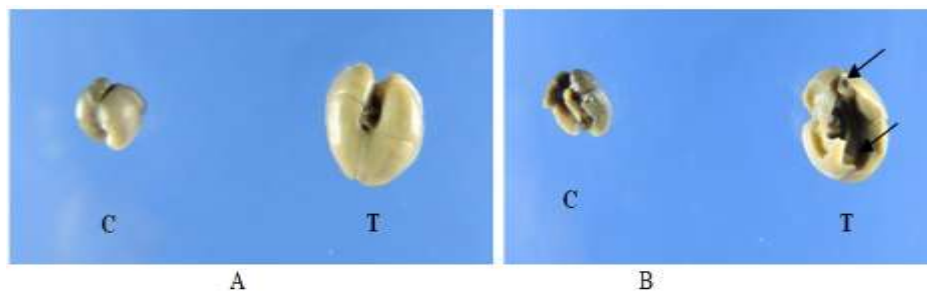

Figure 2: Gross photographs of liver of control (C) and treated (T) groups.

- A. Antero-superior view showing enlargement of liver of treated group
- B. Postero-inferior view showing haemorrhagic spots on inferior surface of treated liver ()

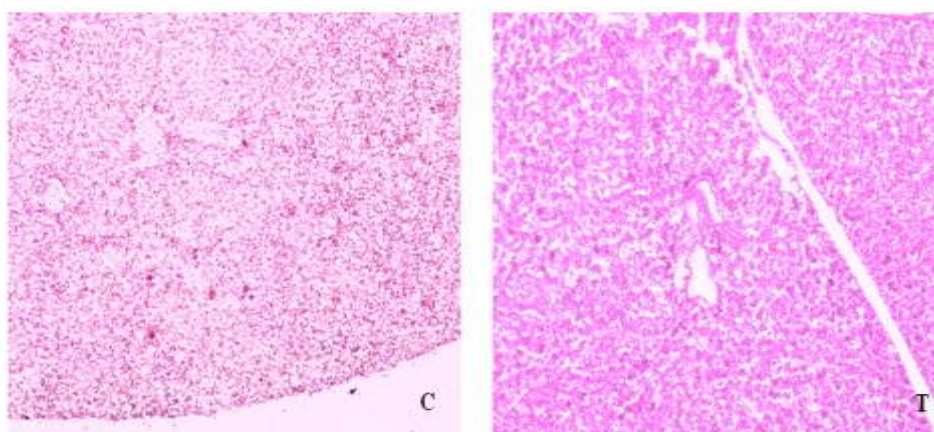


Figure 3. Photomicrograph of liver of control and treated mice foetuses collected on 18th day of gestation, H&E, 100 X

- C. Section of control liver showing the normal appearance of growing parenchyma, sinusoids and central vein in developing liver.
- T. Section of treated liver showing dilatation of central vein, oedematous changes and the loss of normal pattern of parenchyma of growing liver

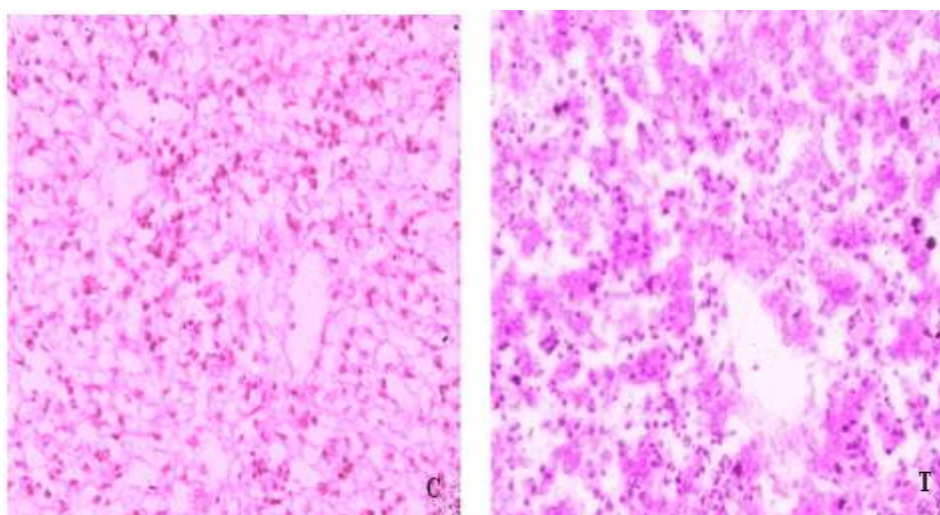


Figure 4: Photomicrograph of liver of control and treated mice foetuses collected on 18th day of gestation, H&E, 400 X

- C. Section of control liver showing the lining epithelium of central vein and growing hepatoblast cells around central vein.
- T. Section of treated liver showing the destruction of lining epithelium of central vein, presence of oedematous spaces, degeneration of liver parenchyma along with pyknotic changes of the growing hepatoblasts.

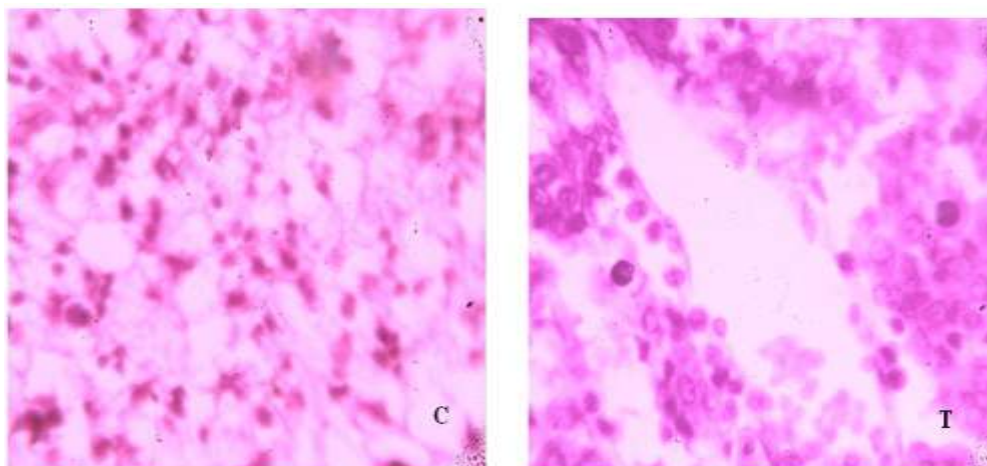


Figure 5. Photomicrograph of liver of control and treated mice foetuses collected on 18th day of gestation, H&E, 1000 X

C. Section of control liver showing normal pattern of growing parenchyma. T. Section of treated liver showing degenerated hepatic cells with pyknotic nuclei and oedematous spaces between the hepatic cords.

V. Conclusion

Lamotrigine was found toxic to growing liver so proper risk benefit analysis regarding its safety is advised before prescribing this antiepileptic drug during pregnancy.

References

- [1]. EURAP, An International Antiepileptic Drugs and Pregnancy Registry. Interim Report May 2008.
- [2]. T. Tomson, I. Ohman, S. Vitols, Lamotrigine in pregnancy and lactation: a case report, *Epilepsia*, 38(9), 1997, 1039-1041
- [3]. I. Ohman, S. Vitols, T. Tomson, Lamotrigine in pregnancy: Pharmacokinetics during delivery in the neonate and during lactation. *Epilepsia*, 41(6), 2000, 709-713.
- [4]. G.J. de Haan, P. Edelbroek, J. Segers, M. Engelsman, D. Lindhout, M. Dévilé-Notschaele, P. Augustijn. Gestation-induced changes in lamotrigine pharmacokinetics: a monotherapy study, *Neurology* 63, 2004, 571-3.
- [5]. C.H. Fotopoulou, R. Kretz, S. Bauer, J.C. Schefold, B. Schmitz, J.W. Dudenhausen, W. Henrich, Prospectively assessed changes in lamotrigine-concentration in women with epilepsy during pregnancy, lactation and the neonatal period. *Epilepsy Research*. 85, 2009, 60-64.
- [6]. P.K. Myllynen, P.K. Pienimäki, K.H. Vahakangas, Transplacental passage of Lamotrigine in a human placental perfusion system in vitro and in maternal and cord blood in vivo. *European Journal of Clinical Pharmacology*, 58(10), 2003, 677-682.
- [7]. R. Padmanabhan, Y.M. Abdulrazzaq, S.M. Bastaki, M. Shafiulla, S.I. Chandranath, Experimental studies on reproductive toxicologic effects of lamotrigine in mice, *Birth Defects Research Part B, Developmental and Reproductive Toxicology*, 68(5), 2003, 428-438.
- [8]. J. Morrow, A. Russell, E. Guthrie, L. Parsons, I. Robertson, R. Waddell, B. Irwin, R.C. McGivern, P.J. Morrison, J. Craig. Malformation risks of antiepileptic drugs in pregnancy: a prospective study from the UK epilepsy and pregnancy register, *Journal of Neurology, Neurosurgery and Psychiatry*, 77(2), 2006, 193-198.
- [9]. F.L. Ramadan, Lamotrigine and Radiation Induced Rat Fetuses Malformations, *Journal of Nuclear Technology in Applied Science*, 2(1), 2014, 83-98
- [10]. M.H. Meshkibaf, A. Ebrahimi, R. Ghodsi, A. Ahmadi, Chronic effects of lamotrigine on liver function in adult male Rats, *Indian Journal of Clinical Biochemistry*, 21 (1), 2006, 161-164
- [11]. Sahar Mohamed Kamal Shams El Dine, Possible effects of lamotrigine on liver of wister rats exposed to chemoconvulsion and Chronic Restraint model, *American Journal of Psychiatry and Neuroscience*, 2(4), 2014, 50-55
- [12]. R. Arnon, D. De Vivo, A.R. Defelice, Acute hepatic failure in a child treated with lamotrigine, *Pediatric Neurology*, 18, 1998, 251-252
- [13]. G. Sauve, S. Bresson-Hadni, P. Prost, et al. Acute hepatitis after lamotrigine administration, *Digestive Diseases and Sciences*, 45, 2000, 1874-1877.
- [14]. M. Fayad, R. Choueiri, M. Mikati, Potential hepatotoxicity of lamotrigine, *Pediatric Neurology*, 22, 2000, 49-52.
- [15]. Dr. Shweta Singh, Teratogenic effects of Lamotrigine in developing mice, Institute of Medical Sciences, Banaras Hindu University, Varanasi, India, 2013
- [16]. S. A. Duncan, Mechanisms controlling early development of the liver, *Mechanisms of Development*, 120, 2003, 19-33.
- [17]. D.P. Jones, Radical-free biology of oxidative stress, *American journal of physiology. Cell Physiology*, 295(4), 2008, C849-C868.
- [18]. R. L. Fisher, S. J. Hasal, I. G. Sipes, A. J. Gandolfi, and K. Brendel, Comparative metabolism and toxicity of dichlorobenzene in Sprague-Dawley, Fischer-344 and human liver slices, *Human and Experimental Toxicology*, 14, 1995, 414-421.
- [19]. A. M. Hissink, B. van Ommen, and P. J. van Bladeren, Dose-dependent kinetics and metabolism of 1,2-dichlorobenzene in rat: effect of pretreatment with phenobarbitone., *Xenobiotica*, 26, 1996, 89-105.
- [20]. E. Hissink, B. van Ommen, J. J. Bogaards and P. J. van Bladeren, Hepatic epoxide concentrations during biotransformation of 1,2- and 1,4-dichlorobenzene: the use of in vitro and in vivo metabolism, kinetics and PB-PK modeling. *Advances in Experimental Medicine and Biology* 387, 1996, 129-133
- [21]. M. Cornelissen, R. Steegers-Theunissen, L. Kollee, Supplementation of vitamin K in pregnant women receiving anticonvulsant therapy prevents neonatal vitamin K deficiency, *American Journal of Obstetrics and Gynecology*, 168, 1993, 884-8