

## Large Dermoid Cyst of Floor of Mouth : A Case Report

Dr. Zahid M.Khan<sup>1</sup>, Dr. Abhishek Verma<sup>2</sup>

<sup>1</sup>(Department of Oncology, Rajendra Institute of Medical Sciences, Ranchi)

<sup>2</sup>(Department of Laboratory Medicine, Rajendra Institute of Medical Sciences, Ranchi)

---

**Abstract:** The dermoid cysts are mid line lesion occurring in floor of mouth and elsewhere. They occur in oral cavity due to germinal epithelium retention of hyoid branchial arches and mandible development. We report an unusual case of large dermoid cyst occurring in floor of the mouth in a 65 year female presenting with difficulty in closing mouth due to presence of large cystic lesion in floor of mouth.

**Keywords:** Floor of the mouth, Dermoid cyst.

---

### I. Introduction

Dermoid cysts are benign cystic lesion accounting for 1.6% to 6.9% of all cystic lesion occurring in head and neck region.<sup>1</sup> They are seen at the sites of fusion of lateral mesenchymal mass and constitute of three cell lineages : ectoderm, mesoderm and the endoderm.<sup>2</sup> They are less than 0.01% of all cystic lesion of oral cavity.<sup>3-4</sup> They are commonly seen in second or third decade. Surgical removal is treatment of choice either by extra-oral or intra-oral route depending on size. We report this unusual case of large dermoid cyst occurring in floor of the mouth in seventh decade of life with surgical removal and follow up.

### II. Case Report

A 65 years female presented to oncology outdoor patient department (O.P.D.) with inability to close mouth due to presence of large globular mass at floor of mouth. On examination a large 6 x 5 cm mass was present in floor of mouth and budges out with protrusion of tongue.(Fig 1) Further surgical removal was planned with proper work up. Computerized tomography scan (CT) was done, showed a well defined cystic mass in the floor of the mouth without extension into surrounding tissue. Patient was subjected to fine needle aspirated cytology (FNAC) which showed anucleated and nucleated squamous cells in the background of keratin material and cholesterol crystals. Intra-oral route of surgical removal was done (Fig 2) and the specimen was histopathological assessed. On gross a well circumscribed mass measuring approximately 7 x 4 x 2 cm is seen, externally congested.(Fig.3) Cut section showed thick grey white pultaceous material with ball of hair. Histological section showed cyst lined by hyperkeratotic squamous epithelium. The subepithelium showed fibrocollagenous tissue amidst of sebaceous glands and hair follicles. (Fig.4). The diagnosis of dermoid cyst was offered. Patient is on regular follow up since last 6 months and doing absolutely fine.

### III. Discussion

Dermoid cysts occurs as developmental defects which results from pluripotent cells entrapment termed as congenital or epithelium implantation termed as acquired.<sup>5</sup> Depending on the position of dermoid cyst, its development and the size it manifests either in floor of the mouth or submental area. Depending on the size there is discomfort in speech, opening of mouth, eating or even in breathing. Infection may lead to pain, dysphagia and fever.<sup>6,7</sup> The dermoid cyst occurs mainly in adults in second and third decade of life.<sup>8</sup> The various imaging studies help in finding the cystic nature of the lesion, anatomical relations and its size.<sup>9,10</sup> The differential diagnoses includes blockage of unilateral or bilateral Wharton's ducts, Ranula, cystic hygroma, branchial cleft cysts, Infections of sublingual glands, cellulitis, benign as well as malignant tumors occurring in floor of the mouth. Surgical removal either via an extra-oral or intra-oral approach. In our case a 65 years female presented with large dermoid cyst in floor of mouth which was surgically removed and is on regular follow up without any complaints.

#### IV. Figures

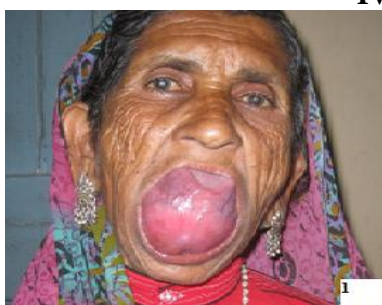


Fig 1 : Large cystic lesion in floor of mouth

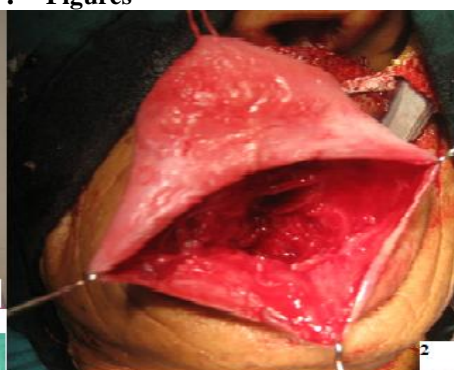


Fig2 : Removal of intra-oral lesion

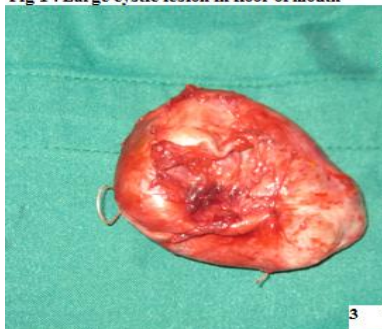

Fig.3 : Well circumscribed cystic lesion



Fig.4 : Hyperkeratotic squamous epithelium. The subepithelium shows sebaceous and hair follicles .

#### V. Conclusion

Dermoid cyst are rare lesion, occurring in floor of mouth which when removed surgically has good prognosis and very less chances of recurrence .

#### References

- [1]. Bonet-Coloma C, Mínguez-Martínez I, Palma-Carrió C, Ortega-Sánchez B, Peñarocha-Diago M, Mínguez-Sanz JM. Orofacial dermoid cysts in pediatric patients: A review of 8 cases. *Med Oral Patol Oral Cir Bucal*. 2011;16:e200-3.
- [2]. De Ponte FS, Brunelli A, Marchetti E, Bottini DJ. Sublingual epidermoid cyst. *J Craniofac Surg*. 2002;13(2):308-10
- [3]. Bitar MA, Kumar S. Plunging congenital epidermoidcyst of the oral cavity. *Eur Arch Otorhinolaryngol*. 2003;260(4):223-25.
- [4]. Lima SM Jr, Chrcanovic BR, De Paula AM, FreireMaia B, de Souza LN. Dermoid cyst of the floor of the mouth. *Scientific World Journal*. 2003;3:156-62
- [5]. Longo F, Maremonti P, Mangone GM, De Maria G, Califano L. Midline (dermoid) cysts of the floor of the mouth: Report of 16 cases and review of surgical techniques. *Plast Reconstr Surg*. 2003;112:1560-5

- [6]. B. D. Gold, D. E. Sheinkopf, and B. Levy, "Dermoid, epidermoid and teratomatous cysts of the tongue and the floor of the mouth," *Journal of Oral Surgery*, vol. 32, no. 2, pp. 107–111, 1974.
- [7]. S. Oatis Jr., G. L. Hartman, G. R. Robertson, and W. E. Sugg, "Dermoid cyst of the floor of the mouth. Report of a case," *Oral Surgery*, vol. 30, no. 2, pp. 192–196, 1975.
- [8]. W. R. Walstad, J. M. Solomon, S. R. Schow, and M. W. Ochs, "Midline cystic lesion of the floor of the mouth," *Journal of Oral and Maxillofacial Surgery*, vol. 56, no. 1, pp. 70–74, 1998
- [9]. King RC, Smith BR, Burk JL. Dermoid cyst in the floor of the mouth. Review of the literature and case reports. *Oral Surg Oral Med Oral Pathol*. 1994;78:567–576. doi: 10.1016/0030-4220(94)90166X
- [10]. Meyer I. Dermoid cysts (dermoids) of the floor of the mouth. *Oral Surg Oral Med Oral Pathol*. 1955;8:1149–1164. doi: 10.1016/0030-4220(55)90380-7.