

## A Study on Prevertebral Coarctation of Vertebral Arteries in Cadavers

Pramila Padmini Mantraratnam<sup>1\*</sup>, Narasinga Rao Bhattam<sup>2</sup>.

<sup>1</sup> Associate Professor, Department of Anatomy

<sup>2</sup> Professor and HOD, Department of Anatomy

<sup>1,2</sup> Gitam Institute of Medical sciences and Research, Rushikonda, Visakhapatnam, Andhra Pradesh, India.

**ABSTRACT:** A detailed anatomy of the blood vessels supplying the head and neck is very important in cervical spine surgeries and cerebral strokes. As a part of routine dissection during the year 2003-2012 and 2015-2016, the thorax and neck of 60 cadavers were dissected. In the present study during the year 2015-2016, 0.85% (1 case) showed unilateral coarctation of vertebral artery on the left side. Vertebral artery coarctation may lead to posterior circulation stroke or transient ischemic attack.

**Key words:** aorta, cerebral, cervical, coarctation, hyoid, vertebral, stenosis

### I. Introduction:

The vertebral artery is originated at subclavian artery, ascending anteriorly to the transverse process of the seventh cervical vertebra, thus lateral to the transverse foramen at that level, penetrating the foramen transversarium of the sixth cervical vertebra and follows an ascending path always through the transverse foramina up to the first cervical vertebra. Then, it runs across the posterior lateral side of the first vertebra, going into the foramen magnum. Cervical vertebrae's transverse foramina are located at vertebral body's lateral side, in front of the lateral mass and just anterior to nerve root. Stenosis of the vertebral artery occurs either in its extra- or intracranial portions, and account for up to 20% of posterior circulation ischaemic strokes (Caplan 1992<sup>1</sup>, Goerge 1982<sup>2</sup>, Koroshet 1987<sup>3</sup>, Pessin 1988<sup>4</sup>). Anatomical variations of the artery path at the segment between the second and sixth vertebrae are rare (Ebraheim NA, 1996a<sup>5</sup>, 1996b<sup>6</sup>, 1997<sup>7</sup>). Aortic origin of vertebral arteries are common due to the persistent sixth dorsal intersegmental artery. The main focus of the present study deals with vertebral artery coarctation with a coincidence of unusual course of prevertebral part and its clinical importance.

Material and methods: 60 cadavers male and female formed the study material during the period (2003-2012) and (2015 -2016). Thorax and neck region were exposed during dissection.

Observations:

The present case was found during 2015-2016. Out of 120 right and left vertebral arteries studied, only one vertebral artery (VA) of left (L) side in an adult female cadaver showed prevertebral coarctation in its proximal part and co-incidentally the prevertebral part was seen disappearing into the foramen transversarium of C3 vertebra opposite hyoid bone (fig.1). This part of the artery was tortuous throughout its course. Vertebral arteries on right side were branches of right (R) subclavian artery and entered the foramen transversarium of C6 (fig.2).

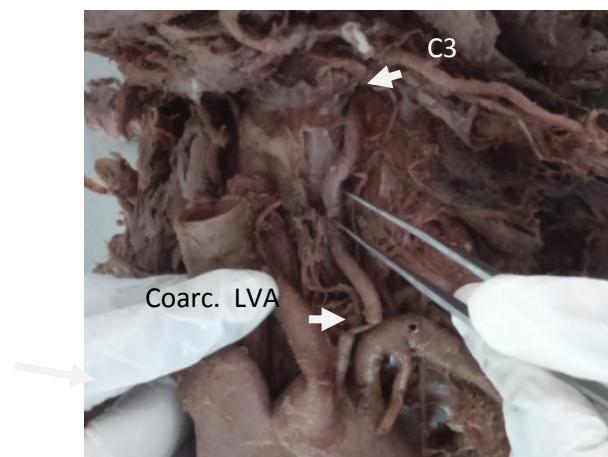


Fig:1 showing coarctation(Coarc.) of LVA and passing through C3 foramen transversarium

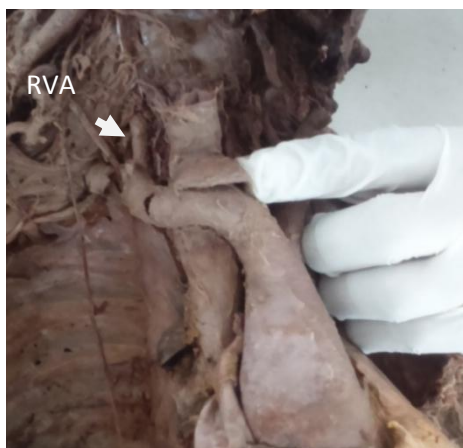

Fig:2 showing normal course of RVA passing through C6 foramen transversarium

## II. Discussion

Anatomically, the vertebral artery can be divided into three extracranial parts and an intracranial portion (Figure 1). Part one is from the origin to the point at which it enters the transverse foramina of either the fifth or sixth cervical vertebra. During the second part, it courses within the intervertebral foramina until exiting as the third part behind the atlas and heading towards the foramen magnum. The final intracranial part begins as it pierces the dura and arachnoid mater at the base of the skull, and ends as it meets its opposite vertebral artery to form the midline basilar artery at the level of the pontomedullary junction. Atherosclerotic disease at the first part of the vertebral artery is commonly associated with similar disease in the internal carotid artery (Castaigne P 1973<sup>8</sup>, Hustinchan 1956<sup>9</sup>).

Aortic arch anomalies are also associated with chromosomal 22q deletion (Momma K 1999<sup>10</sup>). The extracranial portion, especially the prevertebral part of the VA is frequently affected from atherosclerosis and it is the common site of stenosis (Imre N 2010<sup>11</sup>). There are no population-based prevalence data for extracranial vertebral artery stenosis. Studies to date have been of small numbers in specialist cohorts (Cehn 1998<sup>12</sup>). The largest published series are from the New England Medical Centre posterior circulation stroke registry. Of 407 patients who were symptomatic from either posterior circulation stroke or transient ischaemic attack (TIA) or both, 80 (20%) were found to have >50% stenosis of the first part of the vertebral artery (Wityk 1998<sup>13</sup>). In the present study, coarctation of prevertebral part of vertebral artery was observed in 1 female cadaver on the left side.

Ben Hur Junitiro KaJimoto 2007<sup>14</sup> in a study on 20 cadavers (40 vertebral arteries) found 37 vertebral arteries entering the transverse foramen of the sixth cervical vertebra (C6 - 92.5%), and three of them through C7 transverse foramen (7.5%). In the present study, the first part of vertebral artery sprouted as third branch of aortic arch and disappeared into the foramen transversarium of third cervical vertebra C3 opposite to the hyoid bone. In a study by Bruneau et al<sup>15</sup>, out of 500 vertebral arteries studied, they observed an abnormal level of entrance into foramen transversarium in 7% specimens (35 cases), with a level of entrance into the C3, C4, C5, or C7 foramen transversarium respectively in 0.2%, 1.0%, 5.0% and 0.8% of all specimens. Seventeen abnormalities were right sided and 18 were left sided. Thirty-one out of 250 patients had a unilateral anomaly and two had a bilateral anomaly (M. Bruneau 2006<sup>15</sup>). In the present study, the LVA entered C3 foramen transversarium.

## III. Conclusion

Aortic origins of left vertebral arteries are clinically asymptomatic. Vertebral artery coarctation leads to posterior circulation stroke or transient ischemic attack. Tortuous vertebral artery may lead to nerve compression, bone erosion, leading to fractures. A detailed vascular anatomy is very important when dealing with cervical spine approaches, head and neck surgeries and cerebral strokes.

### Figure Legends:

Fig:1 showing coarctation of LVA and passing through C3 foramen transversarium

Fig:2 showing normal course of Right Vertebral Artery

Note: I, the corresponding author worked in MIMS medical college, Vizianagaram during the period 2003-2013 where the above presented vertebral coarctation was not observed. The above described case was observed during 2015-2016 in GIMSR, Rushikonda, Vizag.

### References

- [1]. Caplan LR, Amarenco P, Rosengart A, Lafranchise EF, Teal PA, Belkin M, DeWitt LD, Pessin MS. Embolism from vertebral artery origin occlusive disease. *Neurology* 1992; 42:1505–12.
- [2]. George B, Laurian C. Vertebro-basilar ischaemia. Its relation to stenosis and occlusion of the vertebral artery. *Acta Neurochir (Wien)* 1982; 62:287–95.
- [3]. Koroshetz WJ, Ropper AH. Artery-to-artery embolism causing stroke in the posterior circulation. *Neurology* 1987; 37:292–5.
- [4]. Pessin MS, Daneault N, Kwan ES, Eisengart MA, Caplan LR. Local embolism from vertebral artery occlusion. *Stroke* 1988; 19:112–15.
- [5]. Ebraheim NA, Xu R, Yeasting RA. The location of the vertebral artery foramen and its relation to posterior lateral mass screw fixation. *Spine*. 1996; 21:1291-95.
- [6]. Ebraheim NA, Lu J, Brown JA, Biyani A, Yeasting RA. Vulnerability of vertebral artery in anterolateral decompression for cervical spondylosis. *Clinical Orthop Relat Res* 1996; (322):146-51.
- [7]. Ebraheim NA, Reader D, Xu R, Yeasting RA. Location of the vertebral artery foramen on the anterior aspect of the lower cervical spine by computed tomography. *J Spinal Disord*. 1997; 10:304-7.
- [8]. Castaigne P, Lhermitte F, Gautier JC, Escourolle RD, Derouesne C, Agopian P, Popa C. Arterial occlusions in the vertebro-basilar system. *Brain* 1973; 96:133–54.
- [9]. Hutchinson EC, Yates PO. The cervical portion of the vertebral artery: a clinico-pathological study. *Brain* 1956; 79:319–31
- [10]. Momma K, Matsuoka R, Takao A. Aortic arch anomalies associated with chromosome 22q11 deletion (CATCH 22). *Pediatr Cardiol*. 1999; 20: 97–102.
- [11]. Imre N, Yalcin B, Ozan H. Unusual origin of the left vertebral artery. *Int J Anat Var (IJAV)*. 2010; 3: 80–82.
- [12]. Chen WH, Ho DS, Ho SL, Cheung RT, Cheng SW. Prevalence of extracranial carotid and vertebral artery disease in Chinese patients with coronary artery disease. *Stroke* 1998; 29:631–4.
- [13]. Wityk RJ, Chang HM, Rosengart A, Han WC, DeWitt LD, Pessin MS, Caplan LR. Proximal extracranial vertebral artery disease in the New England Medical Center Posterior Circulation Registry. *Arch Neurol* 1998;55:470–8
- [14]. Ben Hur Junitiro Kajimoto; Renato Luis Dainesi Addeo; Gustavo Constantino de Campos; Douglas Kenji NarazaKi; Leonardo dos Santos Correia; Marcelo Poderoso de Araújo; Alexandre Fogaça Cristante; Alexandre Sadao Iutaka; Raphael Martus Marcon; Reginaldo Perilo Oliveira; Tarcísio Eloy Pessoa de Barros Filho Anatomical study of the vertebral artery path in human lower cervical spine *Acta ortop. bras.* vol.15 no.2 São Paulo 2007
- [15]. M. Bruneau, J. F. Cornelius, V. Marneffe, M. Triffaux, and B. George, “Anatomical variations of the V2 segment of the vertebral artery,” *Neurosurgery*, vol. 59, supplement 1, pp. S20–S24, 2006.