

## Pre-Prosthetic Orthodontic Implant for Management of Congenitally Unerupted Lateral Incisors – A Case Report

Abu-Hussein Muhamad<sup>1</sup>, Chlorokostas Georges<sup>2</sup>, Watted Nezar<sup>3</sup>,  
 Abdulgani Azzaldeen<sup>4</sup>, Ayah Jabareen<sup>5</sup>

<sup>1</sup>University of Naples Federic II, Naples, Italy, Department of Pediatric Dentistry, University of Athens, Athens, Greece

<sup>2</sup>Implantologist, Private dental practice, Athens, Greece

<sup>3</sup>Department of Orthodontics, Arab American University, Jenin, Palestine,

<sup>4</sup>Department of Conservative Dentistry, Al-Quds University, Jerusalem, Palestine

<sup>5</sup>Graduate student, Arab American University, Jenin, Palestine

**Abstract:** The maxillary lateral incisor is one of the most common congenitally missing teeth of the permanent dentition. With the advent of implants in the field of restorative dentistry, a stable and predictable fixed prosthetic replacement has become a reality, especially for young adult patients who suffer from congenital absence of teeth. The dual goals of establishment of functional stability as well as enhancement of esthetic outcomes are made achievable by the placement of implants. A multidisciplinary team approach involving the triad of orthodontist, periodontist and restorative dentist will ensure the successful completion of the integrated treatment approach in these patients. The present case report achieved successful implant based oral rehabilitation in a patient diagnosed with congenital absence of bilateral maxillary lateral incisors utilizing a preprosthetic orthodontic implant site preparation for the purpose of space gain.

**Keywords:** Preprosthetic, interdisciplinary treatment, implant placement

### I. Introduction

The lateral incisor is the most common congenitally missing permanent tooth in the maxillary anterior region with the prevalence of 1 to 3%. This has been associated with their anatomical position in the fusion area of facial process.[1] However, when maxillary lateral incisors are missing, individuals are confronted with functional problems and poor smile esthetics at a young age.[1, 2] The management of maxillary lateral incisor agenesis has gained of multiple dental specialties (orthodontics, periodontics, oral surgery, prosthodontics...). Congenitally missing maxillary permanent lateral incisors often lead to an unattractive appearance and difficulty in treatment planning. Age, location, space limitations, alveolar ridge deficiencies, uneven gingival margins, occlusion, and periodontal factors often necessitate an interdisciplinary approach. [1,2,3,4] Several studies have shown that MSX1 and PAX9 genes play a role in early teeth development. PAX 9 is a paired domain transcription factor that plays a critical role in odontogenesis. All identified mutations of PAX 9 and MX1 have been associated with nonsyndromic form of teeth agenesis.[1,3]

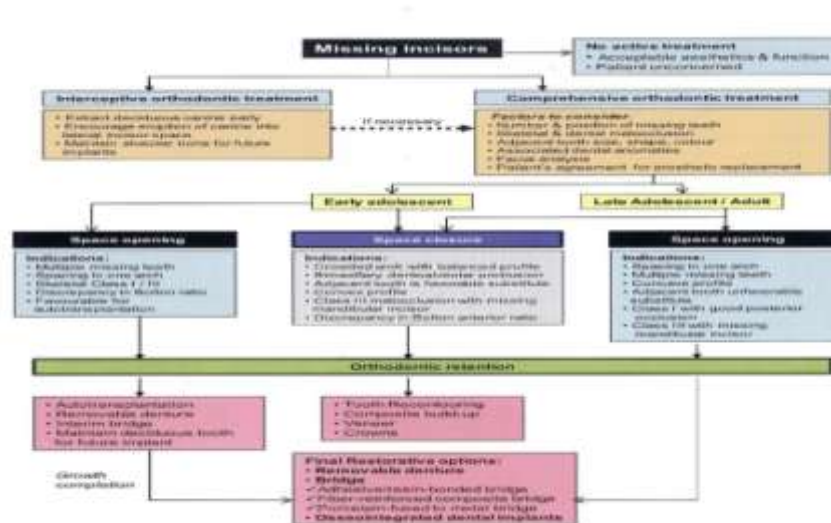


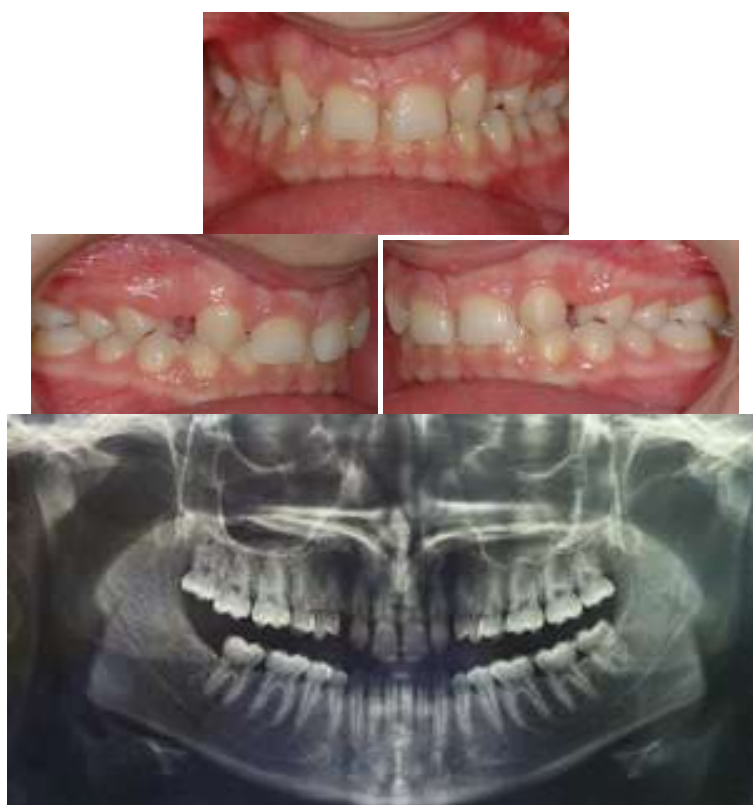Table.1; Interdisciplinary approach congenitally missing lateral incisor

Hypodontia creates significant challenges to the clinicians in both diagnosis and management. Comprehensive management often requires a multidisciplinary approach. There are different treatment alternatives for patients with a missing lateral incisor because of congenital reasons [1-8]. Esthetic and functional problems can arise when an orthodontic space closure is realized and the canine is moved into the missing lateral incisor's space. [1,3]

The two major alternative treatment options are orthodontic space closure or space opening for prosthetic replacements. But they both can compromise aesthetics, periodontal health and function. Treatment alternatives for restoring edentulous spaces resulting from congenitally missing permanent lateral incisors include removable partial dentures, conventional fixed bridges, resin-bonded bridges, autotransplantation, orthodontic repositioning of canines to close the edentulous space and single-tooth implant.[5,7,9]

The first step to the successful, long-term management of a congenitally missing lateral incisor case is early detection and referral to the orthodontist. The role of the orthodontist in the early mixed-dentition stage of development is to monitor and guide the eruption of the permanent canine. If the crown of the permanent canine is erupting apical to the primary canine root as it normally does, it may be necessary to selectively extract the primary lateral incisor to encourage the permanent canine to erupt adjacent to the central incisor. The reason for this is twofold. A mesially positioned canine not only provides a natural means for augmenting the supporting tissues, but it also allows for greater flexibility in future treatment planning.[6,7,8,9][ Table.1]

The single-tooth implant has become the most popular treatment alternative for the replacement of missing teeth. Various studies have shown the successful osseointegration and long-term function of restorations supported by single-tooth implants. In addition to the high success rates, one main benefit of this type of restoration is that it leaves the adjacent teeth untouched. This is particularly important in young patients and unrestored dentitions. It is true that implant-supported restorations are not without potential problems. These problems range from mechanical complications to biologic changes that can impact their long-term predictability[9,10] However, if the proper surgical and restorative protocols are followed, potential complications or esthetic compromises are minimal. To achieve a stable esthetic and healthy outcome with dental implants, it is beneficial to understand their effects on the surrounding hard and soft tissues.[5,6,9,10,11]



**Figure 1a-d;Pre Treatment Intra Oral Photographs**

An interdisciplinary approach is necessary to provide the most predictable treatment results when single-tooth implants are inserted to replace congenitally missing lateral incisors. Osseointegration enables long-term stability of a prosthesis supported by a single-tooth implant.[11,12] In the past, however, neither approach

produced results that were entirely satisfactory from an esthetic and functional standpoint. Selecting the appropriate treatment option depends on the malocclusion, anterior relationship, specific space requirements and condition of the adjacent teeth. The ideal treatment is the most conservative option that satisfies individual esthetics and functional requirements.[6,8,9,10,13]

In an orthodontic patient, missing teeth will require restoration or reshaping of an adjacent tooth, after the orthodontic treatment. Furthermore, each type of restoration may require slightly different tooth position. Therefore, it is mandatory for the team to establish a treatment plan[10]. The orthodontist should join hands with the restorative dentist and consult before the treatment plan. However, some adult orthodontic patients may have several missing permanent teeth. If teeth have been absent for several years, the remaining teeth may have been drifted. In such situation, it may be necessary to position the teeth in unusual place[9,10]. These patients may require a combination of orthodontic and restorative dentistry to rehabilitate their occlusion. In these patients, it may be difficult for the orthodontist to visualize or foresee the final result as she/he may not be aware of restorative requirements or the eventual restoration plans and vice versa for the restorative dentist also.[11,12]

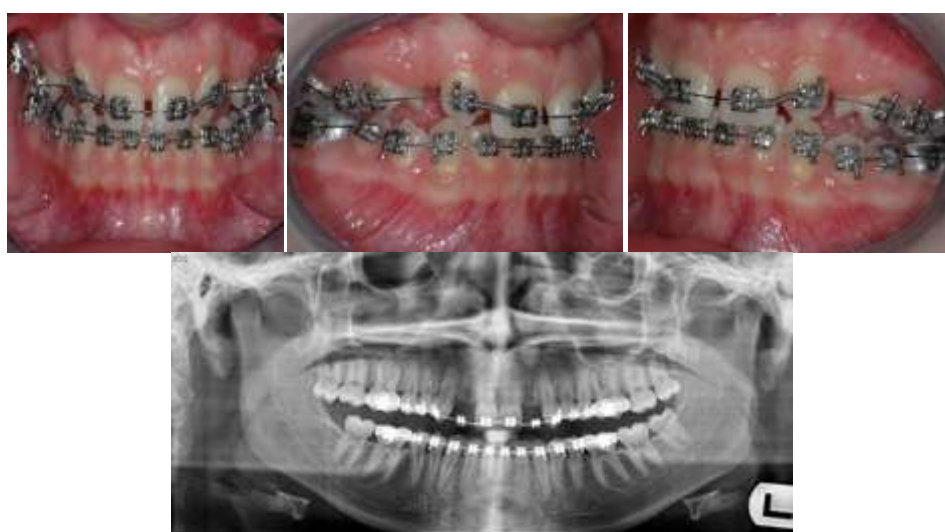
Most commonly, the missing permanent teeth next to third molars and second premolars are the maxillary laterals. Treatment planning for patients with missing maxillary lateral incisors traditionally includes either space closure or space reopening and insertion of implants[10]. Some common objections to orthodontic space closure are that the treatment outcome may not look "natural," that the functional occlusion is compromised, and that retention of the treatment result is difficult, although it may appear preferable esthetically and functionally to create space for replacement of the missing lateral incisor with a single-tooth implant or resin-bonded bridge, and while high survival rates for implant-supported porcelain crowns can be expected.[11,13,14,15] The aim of this case report is to provide a conservative multi-disciplinary approach for the management of bilaterally missing maxillary permanent lateral incisors.

## II. Case Report

A girl, aged 18 years came to my practice with the request of having teeth fixed for upper front spacing. She was physically healthy with no history of dental trauma. She had a slightly convex profile. She had a pleasing smile and lip competence. The intraoral examination showed half-cusp Class II molar relationships and spacing in upper arch with crowding of 3.5 mm in the mandibular arch. Her maxillary dental midline was displaced 2 mm to the right of the facial midline and mandibular dental midline coincided with the body midline. Overbite was 50% with a moderate curve of Spee of 3 mm. The panoramic radiograph showed normal root and tooth development, with the missing maxillary lateral incisors. Cephalometric assessment showed Class II (Wits, 2 mm; ANB, 4.5°; SN-GoGn, 32°) with normally inclined incisors. **[Figure 1a-d]**

### Treatment objectives

Ideally, the treatment objectives would include full resolution of the replacement of the missing teeth. However, achievement of this objective might subject the restoration and orthodontics. Class I molar and canine relationships, ideal overjet and overbite, and an esthetic smile with minimal change in the profile were desired.



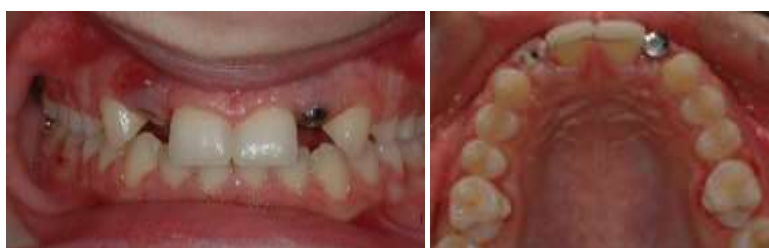**Figure 2.a-d; Treatment Progress (Regained Lateral Spaces)**

### Treatment progress

We started the case on size 022 ROTH Preadjusted Edgewise Appliance , and did initial leveling and aligning of the upper and lower arches [Figure 2.a-d] .After leveling, we planned to open space for the missing teeth, followed by more radiographs to confirm the position of the canine and central incisors roots. The width for the root implant of the lateral incisor space was adequate. The roots of the central incisors and canines were made parallel. Sequential arch wire changes progressing to rigid stainless steel wires were achieved in both arches. Open-coil spring was used to open up the space for the laterals. After space for implants were consolidated, tapered root implants were placed by osteotomy in the lateral areas. Check X-rays confirmed their positions [Figure 3a-b]. The metal-fused ceramic crowns were placed on their respective implant abutments. Lower lingual retainer was given. [Figure 4 a-e]

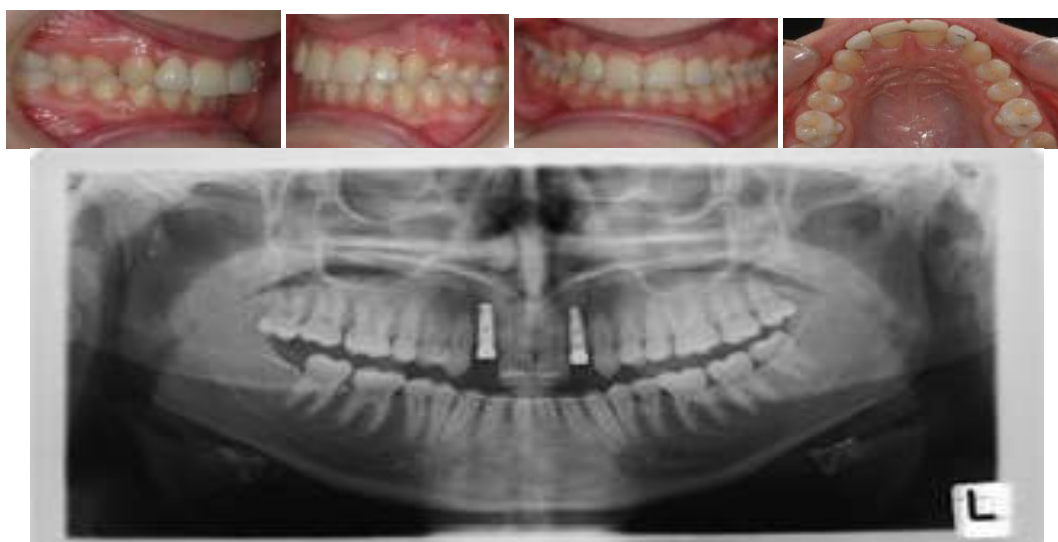### III. Discussion

The treatment of MLIA patients with implants is considered an innovative, more conservative approach, which preserves the morphological features of canines and first premolars, as there is no need to reshape sound adjacent teeth.[5,7,9,10]



**Figure 3a-b; Treatment Progress (Surgical Implant Placement)**

The gingival contour and interdental space filling with papilla comprise important aspects in the esthetic perception of the smile . In general, in implant treatments, these aspects are related with the implant position in regard to the gingival margin. In adult patients, the alveolar bone is usually positioned 2 mm apical to cemento enamel junction, which favors implant placement. In younger patients, however, the alveolar bone is frequently at the level of the cemento enamel junction, which requires the performance of periodontal surgical procedures . In relation to the gingival papilla, space opening is more predictable in young patients.[13-18]



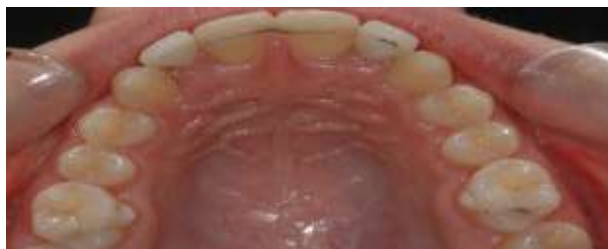**Figure 4 a-e; Post Treatment intraoral Photographs**

The orthodontic movement provides the formation of two papillae, which will be located at the mesial and distal sides of the implant . Concerning the gingival architecture and the composition of the gingival zenith, the treatment of patients with MLIA with implants showed better results when compared with patients treated with space closure and canine recontouring . However, progressive infraocclusion in the implant area can occur after some years because of the continuous eruption of adjacent teeth, even in adults and elderly patients.[5,7,8,9,10,11,19,20]

Another possible outcome with the implant technique is the progressive loss of marginal bone support at the buccal aspect of the implant . This ongoing buccal bone resorption can result in discolored soft tissue,



gingival retraction, and abutment exposure . However, with the use of switch-design implants with narrow diameters or platforms, the effects of bone remodeling may be minimized . Besides, with the new advances in customized zirconia components, all-ceramic implant-supported restorations may be used to replace absent lateral incisors, reducing the esthetic impact in cases the tissue around implants shift positions over time.[21,22,23,24]



**Figure 5; Post Treatment intraoral Photographs**

From an esthetic point of view patients treated with implants presented similar mean teeth width values, but divergent height values when compared to patients without agenesis . This is due to the natural limitation of the implant technique, in which the height of the implant will be determined by crestal bone level and the thickness of keratinized tissue of the gingiva around the implants. These aspects may vary depending on several different aspects such as the type of platform or abutment, the relationship between implant and adjacent teeth, the location of the implant/abutment junction, gingival biotype, among others . As a result, implant crown height may not always be reestablished proportionally to the width of the agenesis area . Although MLIA patients treated with implants present narrower teeth, it has been reported that they finish their treatment with a more proportional smile than patients treated with canine recontouring, closer to the Golden Proportion. [5,9,25,26]

A common orthodontic restorative situation involves a patient who has congenitally missing one or two lateral incisors. If the patient has one maxillary lateral incisor missing, the contralateral incisor would determine the amount of space for the implant and crown. However, in some patients, the existing lateral may be peg shaped. In other situations, both lateral incisors missing are congenitally absent and the amount of space is determined by two factors "esthetics and occlusion". An esthetic relationship exists between the size of the maxillary central and lateral incisors. The size relationship has been called as the "Golden proportion". Ideally, maxillary lateral incisor should be about two-third the width of the central incisor. Since most central incisors are about 9 mm wide, the width of the lateral incisor space should not be less than 6 mm. Today, the narrowest implant is about 3.2 mm in diameter. If the edentulous space is 6 mm wide, then 1.4 mm would exist between the implant and adjacent roots. In this case, the important things are implant site development and timing of implant placement, which are vital for the success, and had been achieved. [5,8,9,23,25,26][Figure 5] [Table.1]

#### **IV. Conclusions**

Orthodontists, prosthodontists and general dentists could correctly identify the procedure performed (implant, RMB, canine substitution, or natural) about ¾ of the time. It is the practitioner's or dental institution's obligation to explain the limits and risks of extensive orthodontic, restorative, and implant therapy to other dental professionals so all can mutually agree while planning treatment. Furthermore, successful restorative treatment involving implants depends on interdisciplinary treatment planning, preprosthetic orthodontic tooth alignment for achievement sufficient space, bone grafting for augmentation ridge width and implant surgery and prosthesis.

#### **References**

- [1]. Abu-Hussein M., Watted N., Abdulgani N. , Alterman M.; Non-Syndromic Oligodontia: A Rare Case Report, *jmscr*2015,3(5), . 5649-5655
- [2]. Abu-Hussein M., Watted N., Watted A., Abu-Hussein Y, Yehia M .Awadi O. , Abdulgani A .; Prevalence of Tooth Agenesis in Orthodontic Patients at Arab Population in Israel, *International Journal of Public Health Research* ,2015; 3(3): 77-82.
- [3]. Abu-Hussein M., Watted N., Yehia M., Proff P., Iraqi F.; Clinical Genetic Basis of Tooth Agenesis, *Journal of Dental and Medical Sciences*2015,14(12),68-77
- [4]. Abu-Hussein M., Abdulgani A., Watted N .Zahalka M.; Congenitally Missing Lateral Incisor with Orthodontics, Bone Grafting and Single-Tooth Implant: A Case Report. *Journal of Dental and Medical Sciences*2015, 14(4),124-130
- [5]. Abu-Hussein M., Watted N., Abdulgani A., Bajali M.;Treatment of Patients With Congenitally Missing Lateral Incisors: Is an . Interdisciplinary Task. *RRJDS* 2014,2(4),53-68
- [6]. Abu-Hussein M., Watted N., Abdulgani A., BorbélyB.; Modern Treatment for Congenitally Missing Teeth : A Multidisciplinary Approach; *INTERNATIONAL JOURNAL OF MAXILLOFACIAL RESEARCH*,2015,1(2):179-190
- [7]. Abu-Hussein M., Watted N., Abdulgani A., Kontoes N.; Prosthodontic-Orthodontic Treatment Plan with Two-UnitCantilevered Resin-Bonded Fixed Partial Denture, *IOSR-JDMS* 2015,14(12) , 131-136
- [8]. Abdulgani A., Kontoes N., Chlorokostas G.,Abu-Hussein M .;Interdisciplinary Management Of Maxillary Lateral Incisors Agenesis With Mini Implant Prosthesis: A Case Report; *IOSR-JDMS* 2015,14 (12) , 36-42
- [9]. Abusalih A. , Ismail H, Abdulgani A. , Chlorokostas G ., Abu-Hussein M .;

- [10]. Interdisciplinary Management of Congenitally Agenesis Maxillary Lateral Incisors: Orthodontic/Prosthetic Perspectives, *Journal of Dental and Medical Sciences* 2016, Vol 15, 1 , 90-99
- [11]. Abu-Hussein M, Watted N, ; Congenitally Missing Upper Laterals. Clinical Considerations: Orthodontic Space Closure, **Int Res Pub Med Sci, 2015;1(3):82-89**
- [12]. Kavadia S, Papadiochou S, Papadiochos I, Zafiriadis L. Agenesis of maxillary lateral incisors A global overview of the clinical problem., *Orthodontics (Chic)*. 2011; 12: 296-317.
- [13]. Kinzer GA, Kokich Jr VO. Managing Congenitally Missing Lateral Incisors Part 2: Tooth-supported restorations., *J Esthet Restorat Dent. 2005; 17: 76-84.*
- [14]. De-Marchi LM, Pini NIP, Hayacibara PM, Silva RS, Pascotto RC. Congenitally missing maxillary lateral incisors Functional and periodontal aspects in patients treated with implants or space closure and tooth re-contouring., *Open Dent J.* 2012; 6: 248-54.
- [15]. Antonarakis GS, Prevezanos P, Gavric J, Christou P. Agenesis of maxillary lateral incisor and tooth replacement Cost-Effectiveness of different treatment alternatives., *Int J Prostodont.* 2014; 27: 257-63.
- [16]. Al-Anezi SA. Orthodontic treatment for a patient with hypodontia involving the maxillary lateral incisors., *Am J Orthod Dentofac Orthoped.* 2011; 139(5): 690-7.
- [17]. Park JH, Okadakage S, Sato Y, Akamatsu Y, Tai K. Orthodontic treatment of a congenitally missing maxillary lateral incisor., *J Esthet Restor Dent.* 2010; 22(5): 297-312.
- [18]. Pini NP, De-Marchi LM, Gribel BF, Ubaldini ALM, Pascotto RC. Analysis of the golden proportion and width/height ratios of maxillary anterior dentition in patients with lateral incisor agenesis., *J Esthet Restor Dent.* 2012; 24: 402-14.
- [19]. Pini NIP, De-Marchi LM, Gribel BF, Ramos AL, Furquim LZ, Pascotto RC. Analysis of width/height ratio and gingival zenith in patients with bilateral agenesis of maxillary lateral incisors., *Dental Press J Orthod.* 2012; 17: 87-93.
- [20]. Zachrisson BU1, Rosa M, Toreskog S. Congenitally missing maxillary lateral incisors canine substitution., *Point. Am J Orthod Dentofac Orthoped.* 2011; 139(4): 434-436.
- [21]. Avila ED, Molon RS, Mollo-Junior FA, Barros LAB, Capelozza-Filho L, Cardoso MA, Cirelli JA. Multidisciplinary approach for the aesthetic treatment of maxillary lateral incisors agenesis thinking about implants., *Oral Surg Oral Med Oral Pathol Oral Radiol.* 2012; 114: e22-8.
- [22]. Kinzer GA, Kokich Jr VO. Managing Congenitally Missing Lateral Incisors Part III single-tooth implants., *J Esthet Rest Dent.* 2005; 17: 202-10.
- [23]. Krassnig M, Fickl S. Congenitally missing lateral incisors--a comparison between restorative, implant, and orthodontic approaches., *Dent Clin North Am.* 2011; 55: 283-99.
- [24]. Marchi LM, Pini NI, Hayacibara RM, Silva RS, Pascotto RC. Congenitally missing maxillary lateral incisors functional and periodontal aspects in patients treated with implants or space closure and tooth re-contouring., *Open Dent J.* 2012; 6: 248-54.
- [25]. Jackson BJ, Slavin MR. Treatment of congenitally missing maxillary lateral incisors an interdisciplinary approach., *J Oral Implantol.* 2013; 39(2): 187-92.
- [26]. De-Marchi LM, Pini NIP, Ramos AL, Pascotto RC. Smile attractiveness of patients treated for congenitally missing maxillary lateral incisors as rated by dentists, laypersons, and the patients themselves., *J Prosthet Dent.* 2014; 112(3): 540-6.
- [27]. Cappiello M, Luongo R, Di R , et al. Evaluation of peri-implant bone loss around platform-switched implants., *Int J Periodontics Restorative Dent.* 2008; 28: 346-55.