

## Morphometric Study Of Variation Of Branching Pattern Of Posterior Tibial Artery And Its Clinical Significance

<sup>1</sup>Dr G.A. Jos Hemalatha M.D(Anatomy), <sup>2</sup>Dr..K.Arumugam M.D (Anatomy)

Assistant Professor, Tirunelveli Medical College, Tirunelveli, Tamilnadu.

Assistant Professor, Tirunelveli Medical College, Tirunelveli, Tamilnadu.

### Abstract:

**Introduction:** In the current millennium, the anatomical knowledge makes a successful diagnosis and provides proper treatment to the patient. It is of paramount importance for Surgeons, Orthopaedicians, Radiologists and Vascular Surgeons to have a sound knowledge of Anatomy. Normal anatomical course and the variations of neurovascular structures have gained importance due to surgical interventions in lower limb region. The incidence of peripheral arterial embolism in popliteal artery and its branches were 10.9%.

### Methods and Materials:

#### Materials Of Study

- 40 lower limb specimens from 20 adult cadavers.  
[15 males, 5 females]
- 10 lower limb specimens from 5 full term fetuses.  
[3 males, 2 females]
- 10 adult Computerised Tomographic lower limb angiogram from patients who undergone angiographic procedures.

#### Methods Of Study

- Dissection Method.
- Radiological Study-By taking angiogram.

**Results:** In 36 adult specimens the posterior tibial artery arose at the lower border of popliteus muscle.[ 90%] In 1 adult specimen it arose below the lower border of popliteus. [ 2.5%] Out of 40 adult specimens, in 37 adult specimens the popliteal artery was divided into anterior tibial artery and tibioperoneal trunk. In 2 adult specimens there was trifurcation of popliteal artery. In one adult specimen the posterior tibial artery was absent. [2.5%].

In 36 adult specimens normal course was found out [ 90%]. In 3 specimens, after giving the peroneal artery, it becomes very smaller in size and passed more medially and after giving a communicating branch to a peroneal artery, terminated at a higher level [7.5%] The posterior tibial artery was absent in 1 specimen

**Conclusion:** Anatomical knowledge about the origin and branching pattern of posterior tibial artery and its variations is important for Vascular and Reconstructive Surgeons and Radiologists for the diagnosis of arterial injury, vascular grafting and embolectomy. Hence I hope this study is useful for Clinicians in various field of medicine.

**Key words:** Popliteus muscle, Peroneal artery, Anterior tibial artery

### I. Background

**“ANATOMY IS THE MOTHER OF MEDICINE”.** In the current millennium, the anatomical knowledge makes a successful diagnosis and provides proper treatment to the patient. For correct interpretations of observations, one requires the basic knowledge of Anatomy.

It is of paramount importance for Surgeons, Orthopaedicians, Radiologists and Vascular Surgeons to have a sound knowledge of Anatomy. Normal anatomical course and the variations of neurovascular structures have gained importance due to surgical interventions in lower limb region. The incidence of peripheral arterial embolism in popliteal artery and its branches were 10.9%.

To do Angiography, Duplex Ultra Sound, Magnetic Resonance Angiography and Computerised Tomography one should know the normal pattern of posterior tibial artery and its variations, for planning these procedures and to avoid misinterpretations of the observations.

### Aim Of The Study

**“Variations in Anatomy are Rule”.** Variations in the origin of posterior tibial artery and its branches are of significance for making an arteriovenous shunt with the great saphenous vein for haemodialysis. Distal popliteal arterial variations may influence the success of femoro distal popliteal and tibial arterial reconstructions.

Awareness of anatomical variations determined by the embryonic vascular development is important for Radiologists and Surgeons. Despite of improvement in vascular surgical techniques, patients with high division of popliteal artery are vulnerable to arterial complications. The arterial complications are fistula formations, pseudo aneurysm during orthopaedic procedures such as high tibial osteotomy and lateral meniscal repair.

Arthroscopic knee surgery is recently a very often performed surgical procedure. Variations in the origin of posterior tibial artery from popliteal artery and its relations need attention during knee joint surgery, total knee arthroplasty and angiographic evaluations.

The study was done in posterior tibial artery with the following parameters:

- Origin in relation to popliteus muscle.
- Branching pattern.
- Course and mode of termination.

## **II. Materials And Methods**

### **Materials Of Study**

- a. 40 lower limb specimens from 20 adult cadavers.  
[15 males, 5 females]
- b. 10 lower limb specimens from 5 full term fetuses.  
[3 males, 2 females]
- c. 10 adult Computerised Tomographic lower limb angiogram from patients who undergone angiographic procedures.

### **Methods Of Study**

- a. Dissection Method.
- b. Radiological Study-By taking angiogram.

### **Specimen Collection:**

1. 20 adult embalmed cadavers were selected from the cadavers allotted to the first MBBS students in the Department Of Anatomy, Stanley Medical College, Chennai-1 and the posterior tibial artery was studied in these cadavers.
2. Five full term fetuses were obtained from Department of Obstetrics and Gynaecology, R.S.R.M attached to Stanley Medical College, Chennai-1. They were embalmed and dissection was done in them.

### **Radiological Study:**

Five patients who underwent angiogram in the Department of Vascular Surgery, Stanley Medical College, Chennai - 1 were included as the subjects for study.

### **Methods Of Study**

#### **A. Dissection Method:**

##### **Adult Specimen:**

The dissection was carried out according to the methodology prescribed by Cunningham's manual of dissection for the exposure of posterior tibial artery and its branches.

A longitudinal incision on the back of leg from popliteal fossa to the heel was made. Skin and superficial fascia were reflected. Then the deep fascia also reflected. The flexor retinaculum was exposed posteroinferior to medial malleolus. The two bellies of gastrocnemius were identified and separated from their attachment to the femur and were reflected downwards. The lower part of popliteal vessels and tibial nerve in the popliteal fossa were exposed.

The soleus was separated from its tibial attachment. The lower border of the popliteus was identified. The fascia was removed from the lower part of popliteal vessels and the terminal branches popliteal artery namely the anterior and posterior tibial arteries were exposed. The posterior tibial artery was traced up to flexor retinaculum. The branches of posterior tibial arteries were dissected.

During the above procedure, the tibial nerve was medial to the artery in the upper part, and then the nerve crosses the artery superficially and was on the lateral side of the artery in the middle and lower part of leg.

### **The following observations were noted:**

Origin of posterior tibial artery from popliteal artery in relations to popliteus was noted. Course of posterior tibial artery in relation to tibial nerve was noted. Level of origin of circumflex fibular artery was noted. Origin of nutrient artery in relation to peroneal artery and its entry in to nutrient foramen of tibia was also noted. The origin, course and termination of peroneal artery were noted. Length of tibioperoneal trunk was measured.

Origin of medial calcaneal branches was seen and their numbers were noted down. Relations of neurovascular bundle within flexor retinaculum were noted. Termination of posterior tibial artery into medial and lateral plantar arteries and their sizes were noted.

**Foetal Specimens:**

In the foetus, the dissection was done similar to the above procedures and the origin and branches of posterior tibial artery were identified. The findings of the observation were noted down as per the parameter taken for the study. [PIC-1]

**PICTURE-1. DISSECTION OF FOETAL SPECIMEN**



**B. Radiological Study:**

*164 multi slide detector Computerised Tomographic Angiogram:*

Computerised Tomographic angiogram images of five patients, who underwent this procedure in Vascular Surgery Department, Stanley Medical College, Chennai -1 were selected without disclosing their identity.

For the above patients, lower limb Computerised Tomographic Angiogram was done and the posterior tibial artery was photographed and studied.

**Observation**

**Dissection study:**

The posterior tibial artery in 20 cadavers of varying age groups and sex were studied.

The posterior tibial artery was studied in 5 foetuses.

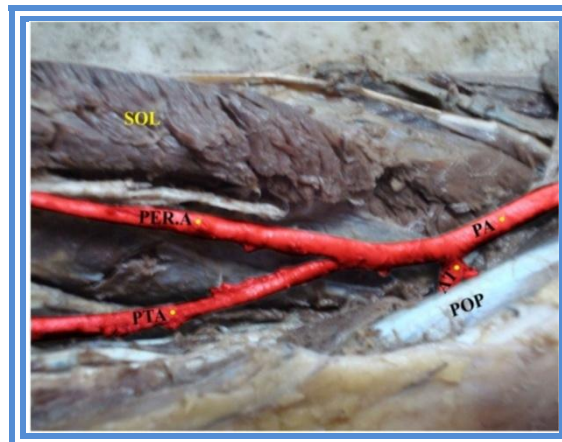
The observations were summarized in accordance with the parameters taken for the study.

**I. Origin in relation to popliteus muscle**

**Adult specimens:**

- In 36 adult specimens the posterior tibial artery arose at the lower border of popliteus muscle.[ 90% ] [PIC-2, TAB-1, CHART-1]

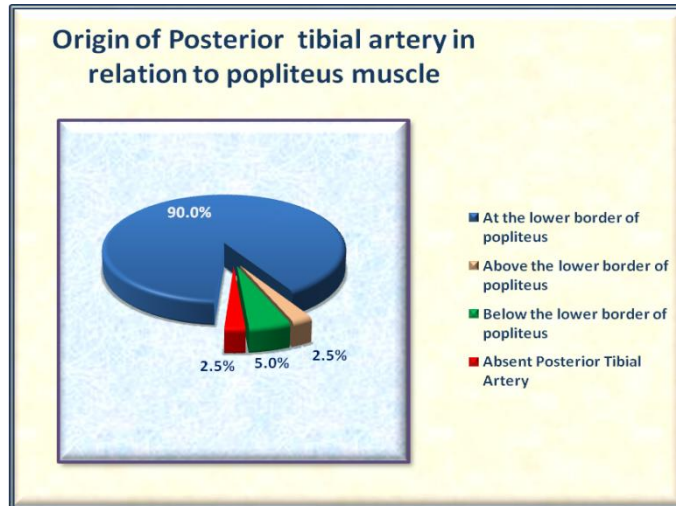
**PICTURE-2 ORIGIN OF PTA AT THE LOWER BORDER OF POPLITEUS**



**TABLE- 1 Origin Of Posterior Tibial Artery In Relation To Popliteus Muscle**

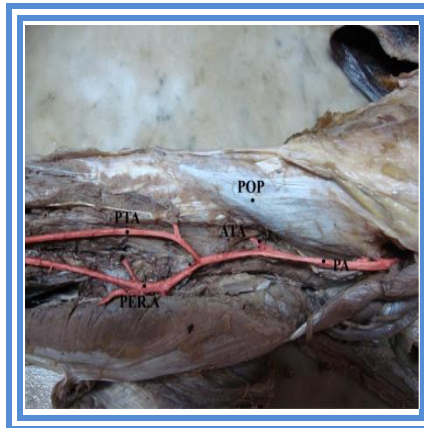Sl. No.	Relation to Popliteus	Adult [40]	Percentage	Fetus [10]	Percentage
1	At the lower border of popliteus	36	90	10	100
2	Above the lower border of popliteus	1	2.5	0	0
3	Below the lower border of popliteus	2	5	0	0
4	Absent Posterior Tibial Artery	1	2.5	0	0

**CHART-1**



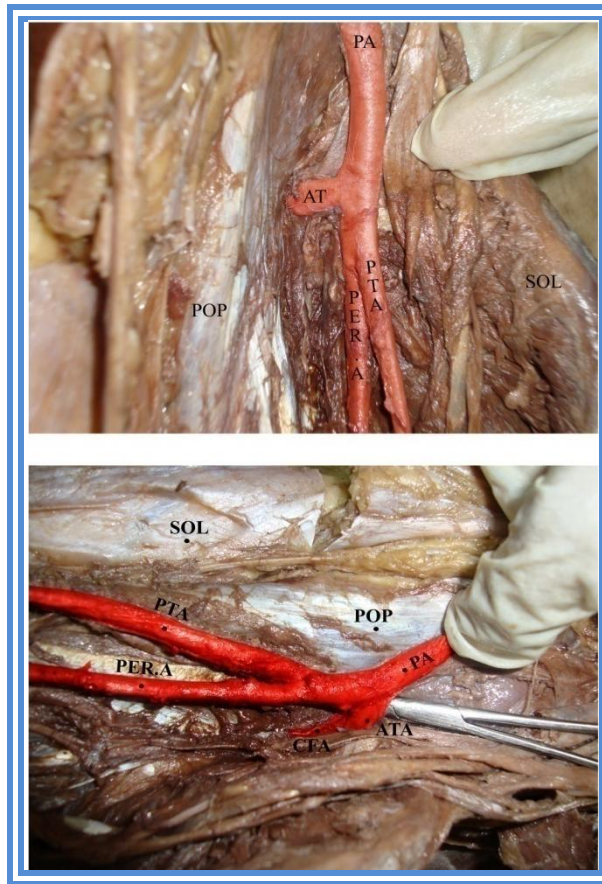
- In 1 adult specimen it arose below the lower border of popliteus. [ 2.5%] [PIC-3]

**PICTURE-3 ORIGIN OF PTA BELOW THE LOWER BORDER OF POPLITEUS**



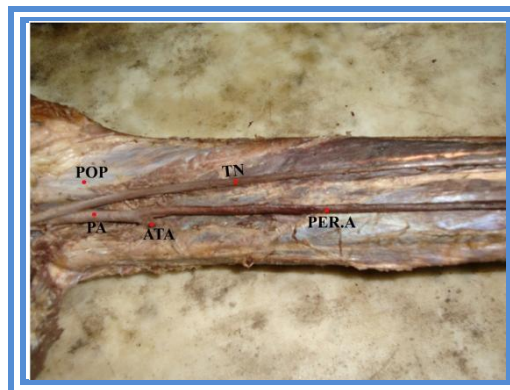- In 2 adult specimens it arose at higher level where there is trifurcation of popliteal artery [ 5%] [PIC-4 & 4a]

PICTURE-4 & 4a TRIFURCATION PATTERN



- In one specimen [2.5%] the popliteal artery at the lower border of popliteus muscle had given 2 branches. One of the branches passed through a gap above the interosseous membrane and appeared in the anterior compartment of leg. Another branch from popliteal artery coursed more laterally and entered within the substance of flexor hallucis longus (PIC.5).

PICTURE-5 ABSENT PTA



**Foetal Specimens:**

- The posterior tibial artery arose at the lower border of popliteus muscle in all the 10 foetal specimens.

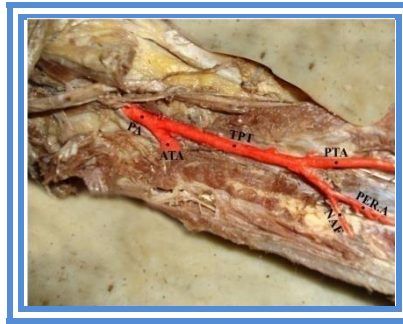
**II. Branching pattern of posterior tibial artery:[TAB-2, CHART-2]**

**Adult Specimen:**

- Out of 40 adult specimens, in 37 adult specimens the popliteal artery was divided into anterior tibial artery and tibio-peroneal trunk. The tibio peroneal trunk then bifurcated into posterior tibial artery and peroneal artery [92.5%][PIC-6 ]



**PICTURE-6 BIFURCATION PATTERN**

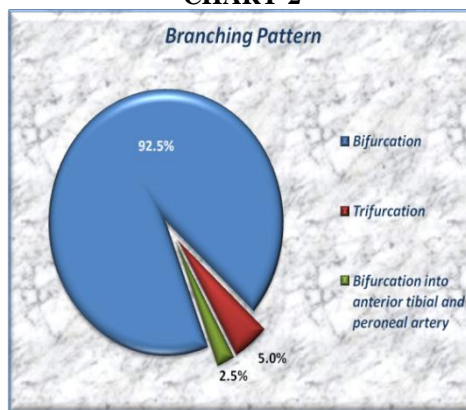


- In 2 adult specimens there was trifurcation of popliteal artery, i.e. the anterior tibial, posterior tibial and peroneal arteries arose within 0.5 cm of from popliteal artery. There was no true tibio peroneal trunk. [ 5%][TAB-2,PIC- 4,4a]

**TABLE-2 Type Of Branching Pattern [Bifurcation / Trifurcation]**

Sl. No.	Type of branching	Adult[40]	%	Fetus[10]	%
1	Bifurcation	37	92.5	9	90
2	Trifurcation	2	5.0	1	10
3	Bifurcation into anterior tibial and peroneal artery	1	2.5	0	0

**CHART-2**

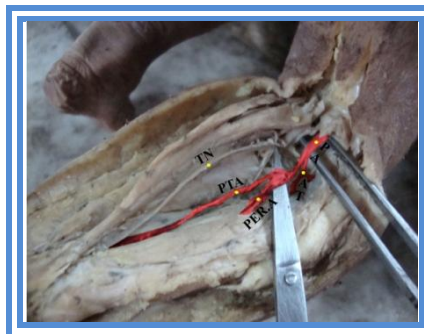


- In one adult specimen the posterior tibial artery was absent. [2.5%].[PIC-5]

**Foetal Specimen:**

- In 9 foetal specimens, bifurcation pattern were seen.
- In one foetal specimen, trifurcation pattern was seen.[PIC-7]

**PICTURE-7 FOETAL STUDY - TRIFURCATION PATTERN**

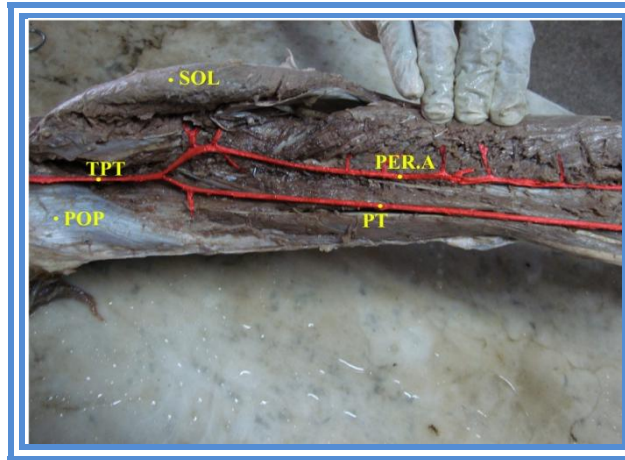


**III. Course and mode of termination of posterior tibial artery:**

The posterior tibial artery after its origin from popliteal artery at the lower border of popliteus passes undercover of tendinous arch of soleus. It was accompanied throughout its course by a pair of venae comitantes.

In upper 2/3<sup>rd</sup> of leg, the artery was superficially covered by soleus. In the posterior surface of tibia the artery was superficially covered by fasciae and skin. Then it passed deep to flexor retinaculum where it terminated by dividing in to medial and lateral plantar arteries. [PIC-8]

PICTURE-8 COURSE OF PTA



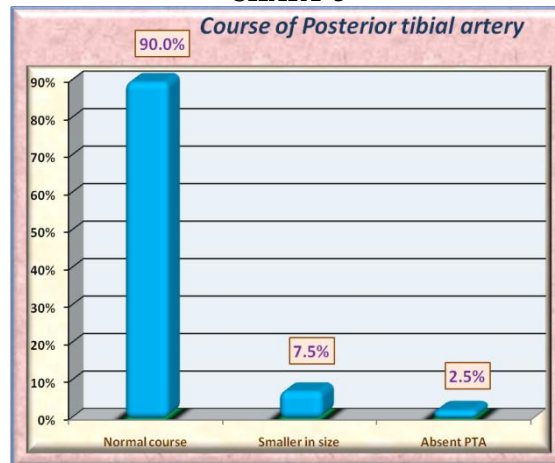
Adult specimens: [TAB-3, CHART-3]

- In 36 adult specimens normal course was found out of 40 specimens[ 90%]

TABLE-3: Course Of Posterior Tibial Artery

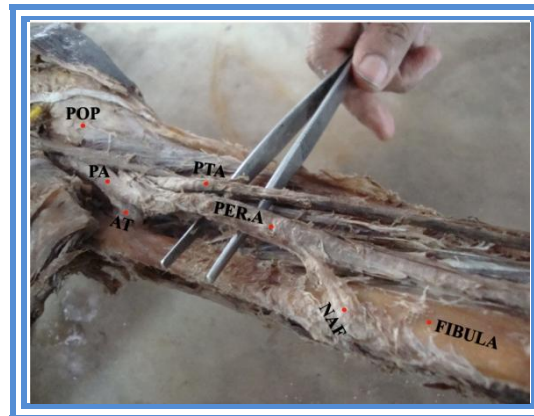
Sl. No.	Course of posterior tibial artery	Adult[40]	%	Fetus[10]	%
1	Normal course	36	90	10	100
2	Smaller in size and terminated at a higher level	3	7.5	0	0
3	Absent Posterior Tibial artery	1	2.5	0	0

CHART-3



- In 3 specimens, after giving the peroneal artery, it becomes very smaller in size and passed more medially and after giving a communicating branch to a peroneal artery, terminated at a higher level [7.5%] [PIC-9]

PICTURE-9 PTA SMALLER IN SIZE



- The posterior tibial artery was absent in 1 specimen [2.5%] [PIC-5]
- In one specimen tibial nerve lies along the medial side of the peroneal artery as the posterior tibial artery was absent [2.5%]

**Foetal specimens:**

- The posterior tibial artery had a normal course and termination in all the 10 foetal specimens.

**Termination**

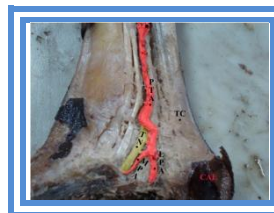**Adult specimens**

Among 37 specimens, in 34 specimens [85%] medial plantar artery was smaller in size. [PIC-10,11] In 3 specimens [7.5%] both were equal in size. [PIC-12]

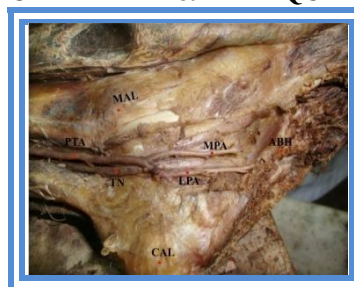
PICTURE-10 LARGE LPA



PICTURE-11 LARGE LPA



PICTURE-12 MPA & LPA EQUAL SIZE



**Foetal Specimens:**

- In all the 10 foetal specimens, the posterior tibial artery was terminated by dividing into medial and lateral plantar arteries.

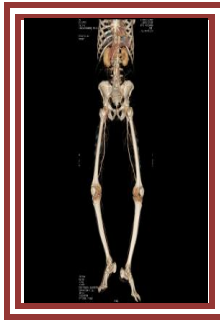
**B. Radiological Study:**

**164 Multislice Detectors Computerised Tomographic Angiogram**

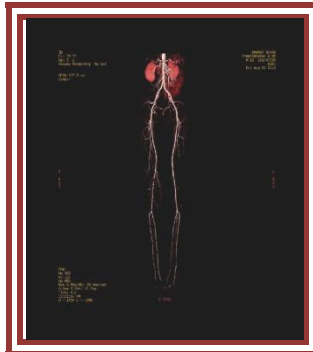
In the ten computerised tomographic images selected, nine computerised tomographic images show normal pattern i.e the posterior tibial artery arose from popliteal artery. [PIC-13-167]. One computerised tomographic image shows the trifurcation pattern. [PIC-17]



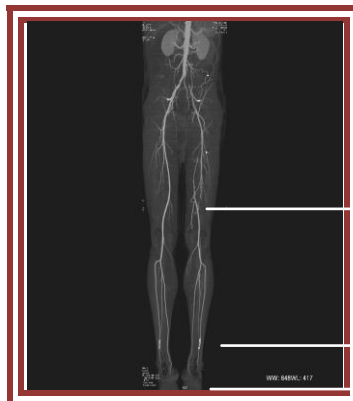**PICTURE – 13 ANGIOGRAPHIC STUDY**



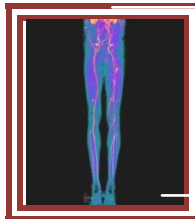
**PICTURE – 14 ANGIOGRAPHIC STUDY - BIFURCATION PATTERN**



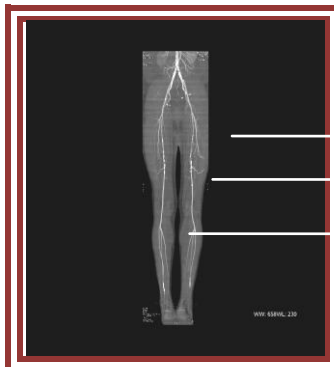
**PICTURE – 15 ANGIOGRAPHIC STUDY - BIFURCATION PATTERN**



**PICTURE – 16 ANGIOGRAPHIC STUDY - BIFURCATION PATTERN**



**PICTURE – 17 ANGIOGRAPHIC STUDY - TRIFURCATION PATTERN**



### **III. Discussion**

The variations in the origin, course, relation and branches of posterior tibial artery and peroneal artery were analysed and compared with those described by previous authors.

#### **1. Origin in relation to popliteus muscle**

##### **a) At the level of lower border of popliteus :**

<sup>6</sup>Henry Gray [1858], <sup>7</sup>W. Henry Hollinshead [1958], Bruce Walmsley Ross [1964], and <sup>17</sup>G. J. Romanes [1964], described that the posterior tibial artery arose at the lower border of popliteus muscle.

<sup>16</sup>Quain [1844], <sup>8</sup>Keen [1961], found that posterior tibial artery arose from popliteal artery at the lower border of popliteus muscle in more than 90 %

<sup>1</sup>Adachi [1928] found that posterior tibial artery arose from popliteal artery at the lower border of popliteus muscle in about 95%

<sup>14</sup>Pearson F.G and Robinson A. [1898], reported that the division of popliteal artery was at the lower border of popliteus muscle in 82%

**In the present study** the origin of posterior tibial artery from popliteal artery at the lower border of popliteus muscle was seen in 90%.

##### **b) Above the level of lower border of popliteus:**

<sup>6</sup>Henry Gray [1858], <sup>18</sup>Sir Solly Zuckerman [1961], observed that the origin of posterior tibial artery was above the lower border of popliteus muscle.

<sup>14</sup>Pearson F.G Robinson [1898] observed high division of popliteal artery in 8.2%

<sup>8</sup>Keen [1961], <sup>2</sup>John L Bardsley[1970] found a high ending of popliteal artery, with the division occurring above the lower border of popliteus muscle in about 5%

<sup>16</sup>Quain [1844] noted the origin of posterior tibial artery above the lower border of popliteus muscle in 3%

**In the present study**, in the posterior tibial artery arose above the lower border of popliteus muscle in 7.5% and it almost coincides with the study of Pearson and Robinson [1898] but more than the incidence quoted by <sup>16</sup>Quain [1844], <sup>8</sup>Keen [1961], Morris [1961], <sup>2</sup>John L Bardsley [1970], R. J Sanders [1986], and Maura[1988] .

#### **II. Branching pattern of posterior tibial artery**

Normally popliteal artery divides into anterior tibial artery and tibioperoneal trunk at the lower border of popliteus .The tibioperoneal trunk divides into posterior tibial artery and peroneal artery. The branching pattern is considered as trifurcation pattern, if anterior tibial artery, posterior tibial artery and peroneal artery divides within 0.5 cm from the popliteal artery.

<sup>8</sup>Keen [1961] observed trifurcation pattern in 4.2%

<sup>16</sup> Quain [1844] observed trifurcation pattern in about 2.5%

<sup>1</sup>Adachi [1928] , <sup>2</sup>Bardsley [1970], noted trifurcation pattern in less than 1%

**In the present study**, the“Trifurcation”pattern was seen in 5%. This finding was similar to the study done by <sup>8</sup>Keen [1961] and more than the study done by <sup>16</sup>Quain [1844], <sup>1</sup>Adachi [1928], [2007].

##### **c) Course and mode of termination of posterior tibial artery**

**According to** <sup>6</sup>Henry Gray [1858], <sup>7</sup>H. Henry Hollinshead [1958], <sup>9</sup>Keith L. Moore [2004] the posterior tibial artery runs downwards and medially and terminates by dividing into medial and lateral plantar arteries under flexor retinaculum.

**In the present study**, in 90% of limbs, the posterior tibial artery passed downwards and medially and terminated by dividing into medial and lateral plantar arteries under flexor retinaculum. This observation coincides with the observations of above said authors.

**According to** <sup>14</sup>Pearson and Robinson (1898) and <sup>3</sup>Christopher Addison [1905] posterior tibial artery is smaller than usual or absent.

**In the present study**, the posterior tibial artery was absent in 2.5% which is similar to the statement of <sup>14</sup>Pearson and Robinson [1898], <sup>3</sup>Christopher Addison [1905].

<sup>15</sup>Pierson [1925] reported that occasionally posterior tibial artery is small in the leg after giving off the peroneal artery but attains its usual size at the ankle after being joined by the communicating branch of peroneal artery.

**In the present study**, posterior tibial artery is small in 7.5% of cases which was similar to the statement given by <sup>15</sup>Pierson [1925].

<sup>8</sup>Keen [1961], <sup>10</sup>Zeliha Kurtalugu et al [2003] reported Type III-A pattern i.e. hypoplastic posterior tibial artery with enlarged peroneal artery in 3-5 % . <sup>2</sup>Bardsley [1970], observed Type III-A pattern in less than 1%

**In the present study**, Type III-A pattern was observed in 7.5% of cases. This finding was higher than the study of <sup>8</sup>Keen [1961], <sup>2</sup>Bardsley [1970], [1989] and <sup>10</sup>Zeliha Kurtalugu et al [1998] but it contradicts the statement of Huber [1940].

<sup>1</sup>Adachi [1928] reported Type III-B pattern: The anterior tibial artery is hypoplastic and the peroneal artery is large. At the ankle, the dorsalis pedis artery is replaced to the peroneal artery. in 6-7% of cases.

**In the present study**, Type III-B pattern was not present in any specimen which contradicts the statement of <sup>1</sup>Adachi [1928].

**In the present study**, the peroneal artery directly arose from posterior tibial artery in 37 adult specimens [92.5%] and coincides with the statement of above said authors.

<sup>14</sup>F. G. Pearson and Robinson [1898], and <sup>4</sup>J. Ernest Frazer [1937] found that high division of popliteal artery was often associated with the origin of the peroneal artery from anterior tibia artery rather than posterior tibial artery. <sup>2</sup>Bardsley and reported that in 1.7% the peroneal artery arose from anterior tibial artery.

**In the present study**, the origin of peroneal artery from anterior tibial artery was not observed. It contradicts the statement of <sup>14</sup>F. G. Pearson and Robinson [1898], <sup>4</sup>Ernest Frazer [1937] and <sup>2</sup>Bardsley.

<sup>14</sup>Pearson F.G and Robinson [1898] reported the incidence of trifurcation pattern in 5%

<sup>8</sup>Keen [1961], noted trifurcation pattern in about 4%

<sup>16</sup>Quain [1844], observed trifurcation of popliteal artery in about 2%

<sup>1</sup>Adachi [1928], <sup>13</sup>Milred Trotter [1940], <sup>2</sup>Bardsley [1970] noted trifurcation pattern in less than 1%

**In the present study**, trifurcation pattern was seen in two adult specimens [5%]. This finding coincides with the study of <sup>14</sup>Pearson and Robinson [1898]

**In the present study**, in one specimen [2.5%], the posterior tibial artery was absent.

#### **Radiological Study:**

Most commonly observed branching patterns were high origin and trifurcation pattern of posterior tibial artery.

**In the present study**, normal branching pattern were seen in nine images and trifurcation pattern was seen in one image out of ten reconstructed Computerized Tomographic images.

#### **IV. Conclusion**

In the present study the anatomy of posterior tibial artery, its branching pattern and its variations and the peroneal artery were analyzed under the parameters described by many authors in the past and present century. The methods of study were routine dissection method and radiological study. The posterior tibial artery was studied in 40 adult cadaveric specimens and 10 foetal specimens and 10 images of Computerised Tomographic Angiograms.

In the present study, the following conclusions were derived:

#### **Origin of posterior tibial artery from popliteal artery:**

- At the lower border of popliteus muscle was seen in 90%.
- Above the lower border of popliteus muscle was seen in 5%.
- Below the lower border of popliteus muscle was seen in 2.5%.
- Absent posterior tibial artery was noted in 2.5%.

#### **Branching pattern:**

- Bifurcation of popliteal artery into anterior tibial artery and tibioperoneal trunk was noted in 92.5% and the trifurcation of popliteal artery into anterior tibial artery, posterior tibial artery and peroneal artery was seen in 5%.
- Bifurcation of popliteal artery into anterior tibial artery and peroneal artery was seen in 2.5%

#### **Course and mode of termination:**

- Normal course and mode of termination was seen in 90%.
- The posterior tibial artery was small in upper one third of leg and attained its usual size in lower one third after being joined by the communicating branch of peroneal artery in 7.5%
- The posterior tibial artery was absent in 2.5%

**FOETAL STUDY:** Among 10 specimens studied, trifurcation pattern was noted in one specimen. In other specimens the branching pattern were normal.

**RADIOLOGICAL STUDY:** Among 10 images studied, trifurcation pattern was seen in one Computerised Tomographic image. In all other images branching pattern were normal.

The two major variants in the branching pattern of popliteal artery are its “Trifurcation” and “High division” which is of greater clinical relevance to Vascular Surgeons. Most common vascular abnormality in club foot is absence of anterior tibial artery in 85%. Care should be taken to avoid injury to the posterior tibial and lateral plantar arteries during club foot release surgery.

Anatomical knowledge about the origin and branching pattern of posterior tibial artery and its variations is important for Vascular and Reconstructive Surgeons and Radiologists for the diagnosis of arterial injury, vascular grafting and embolectomy. Hence I hope this study is useful for Clinicians in various field of medicine.

### References

- [1]. Adachi (1928) Das Arterial system der Japaher Kyoto, Maruzen 1928 vol:2 Pg no 206,227,242,262,269
- [2]. Bardsley (1970) Variations in branching of Popliteal artery – Radiology Pgno 581-587
- [3]. Christopher Addison M D (1905) Ellis’ demonstrations of Antomy, 12th ed Pg no 195-196
- [4]. Ernest Frazer (1939) ,Manual of Practical Anatomy, vol:IPg no 233-235
- [5]. Ernest Garner, Donald J Gray, Ronan O’ Rahilly (1960) Anatomy of Regional Study of Human Structures, 1st ed Pg no 293-296
- [6]. Henry Gray (1858), 38th ed London Churchill Livingstone 1995
- [7]. Henry Hollinshead W (1958) Functional Anatomy of the limbs and back, Pg no 314-315
- [8]. Keen (1961) Astudy of the arterial variations in the limbs with special reference to symmetry of vascular pattern, Annual Journal Anatomy, Pg no 108-245
- [9]. Keith L Moore, Arthur F Dalley, Anne M R Agar (2006) Text book of Surgical Anatomy
- [10]. Kurtoglu et al (2003) A case of fibular artery variation in Trackia Journal of Sciences Vol I ,No 3, Pg no 53-55, 2003.
- [11]. Le Gross Clark (1949) Practical Anatomy, 2nd ed Pg no 114
- [12]. Linden F Edwards (1956) Concise Anatomy, 2nded Pg no 227
- [13]. Milred Trotter (1940), The level of termination of the popliteal artery in the White and Negro, Ann J Phys Anthropology, 27: Pg no 109-118
- [14]. Pearson F.G and Robinson A (1898) Morris ‘Human Anatomy A complete systematic Treatise, 11th ed Pg no 736-740
- [15]. Pierson .H. H (1925), Seven arterial anomalies of human leg and foot, Anatomical record, 30: 139, 1925.
- [16]. Quain R (1844) , Anatomy of arteries of human body, Taylor & Walton Pg no 538-543.
- [17]. Romanes G.J (1964) Cunningham’s Text book of Antomy, 12th ed Pg no 938-940