

## Handle Bar Hernia: A Rare Case Report

Dr.Sasikanth Uddagiri<sup>1</sup>, Dr.Thatha Rao.V<sup>2</sup>, Dr.Nanda Kishore.B<sup>3</sup>,

<sup>1</sup> Dr.Sasikanth Uddagiri, Post Graduate of General Surgery, NRI Medical College & General Hospital, Chinakakani, Guntur Dist, Andhra Pradesh, India.

<sup>2</sup> Dr.Thatha Rao.V, M.S., General Surgery, Professor & HOD of the Department Of General Surgery, NRI Medical College & General Hospital, Chinakakani, Guntur Dist, Andhra Pradesh, India.

<sup>3</sup> Dr.Nanda Kishore.B, M.S., General Surgery, Assistant Professor, NRI Medical College & General Hospital, Chinakakani, Guntur Dist, Andhra Pradesh, India.

**Abstract:** Handlebar hernias are abdominal wall hernias resulting from direct trauma to the anterior abdominal wall. They usually result at weak anatomic locations of the abdominal wall. Such traumatic hernias are rare, requiring a high index of suspicion for a clinical diagnosis. We report the case of a handlebar hernia resulting from an injury sustained during a vehicular injury, and discuss the management of such injuries.

**Key Words:** Handlebar, hernia

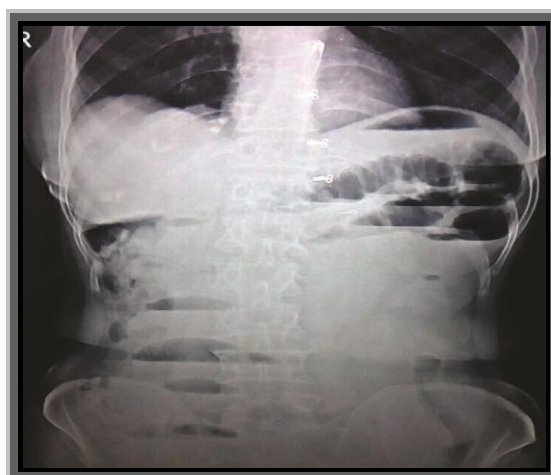
### I. Introduction

Traumatic abdominal wall hernias (TAWHs) are extremely uncommon type of abdominal wall hernia. Blunt traumatic abdominal hernia is defined as a herniation through disrupted musculature and fascia without skin penetration with no evidence of a prior hernial defect at the site of injury. Handlebar hernia caused by direct trauma from handlebar-like objects which was described by Dimyan *et al.* in 1980. In worldwide literature, less than 50 cases of handlebar hernia have been reported with only three to five cases from India.

### II. Observations

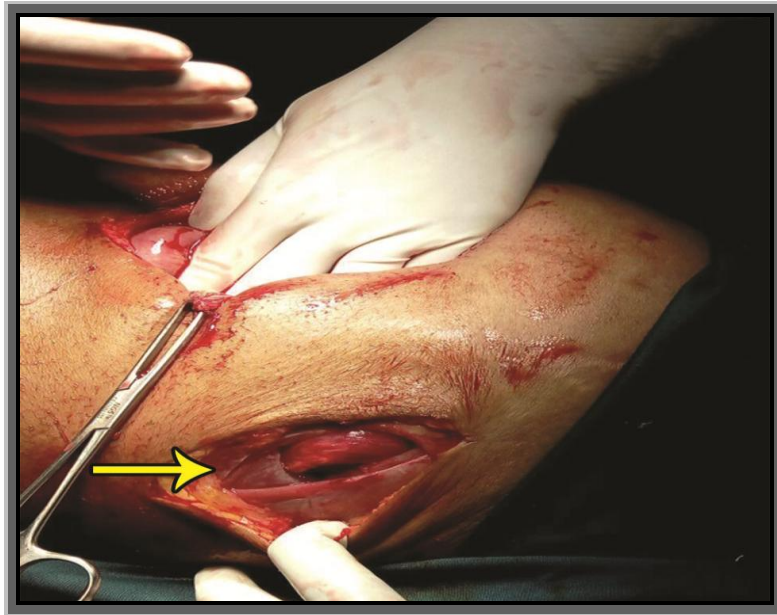
A 55 year old female patient presented with swelling in right lower abdomen after accidental fall over stick 2 days back associated with diffuse abdominal pain more on swelling, obstipation, bilious vomitings. History of Tuberculosis and treated with ATT 12 years back. No other past medical or surgical illness. O/E vitals stable, A oval swelling of size 8 x 5 cm present in right iliac fossa, Impulse on coughing absent, tender, irreducible. P/A – Distended, diffuse tenderness present, Bowel sounds exaggerated, On per rectal examination No mass palpable. X-ray erect abdomen showed multiple air fluid levels.

**Figure 1 : X- Ray Erect abdomen of Irreducible Handle Bar Hernia causing multiple air fluid levels**

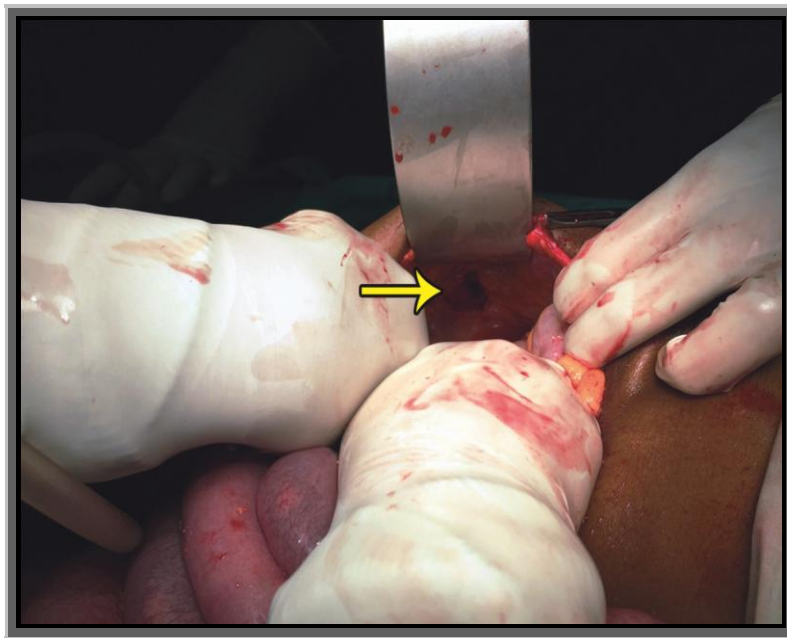


The patient underwent exploratory laparotomy through a midline incision. This revealed distal ileum herniated through defect with small mesenteric tear. Ileum is healthy with no signs of ischemia / luminal compromise. Hernia reduced and mesenteric tear sutured. No other associated injuries of mesentery / solid organs. Defect is closed in layers. Postoperative period uneventful, wound healed well and patient discharged on 12<sup>th</sup> POD after suture removal.

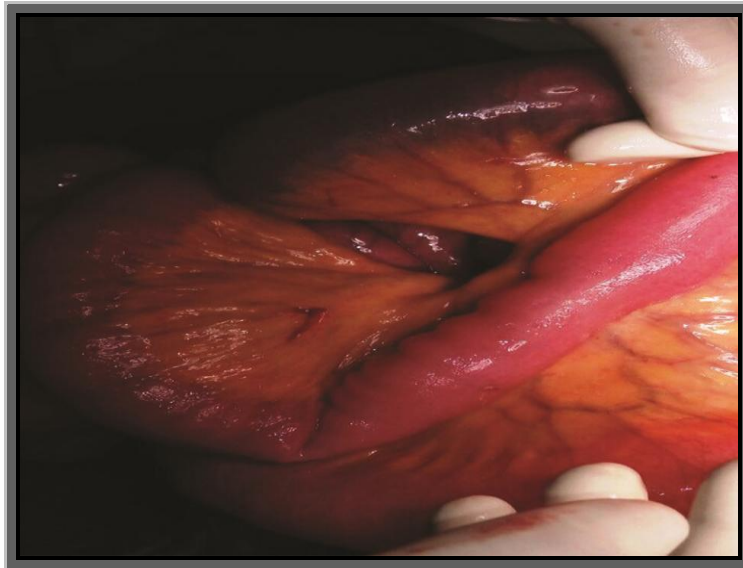
**Figure 2 : External view of the defect.**



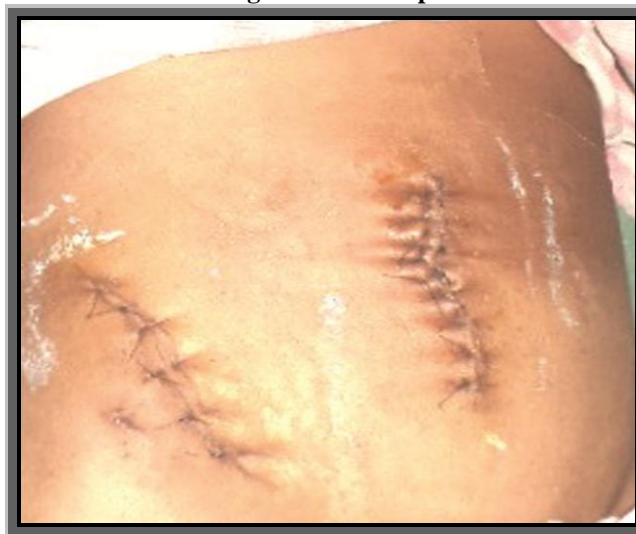**Figure 3 : Internal view of the defect**



**Figure 4 : Hernial content – ileum with small mesenteric tear.**



**Figure 5 : Post Op**



### **III. Discussion**

Most herniations are diagnosed at presentation by physical examination or on abdominal CECT, and most authors have advocated immediate laparotomy with repair of the defect because of the high incidence of associated intra-abdominal injury. Traumatic abdominal hernia was first described by Selby in 1906. The criteria for TAWH include immediate appearance of the hernia through the disrupted muscle and fascia after blunt abdominal trauma, and failure of the injury to penetrate the skin, were defined by Clain and Damschen *et al.* It can occur after blunt trauma abdomen which can be classified into low- or high-energy injuries. Low-energy injuries occur after the impact on a small blunt object. High-energy injuries are sustained during motor vehicle accidents. The pathophysiology of TAWH involves the application of a blunt force to the abdomen over an area large enough to prevent penetration of the skin; the tangential forces resulting in a pressure-induced disruption of the abdominal wall muscles and fascia, allowing subcutaneous herniation of abdominal viscera through the defect, as proposed by Ganchi. As the skin is more elastic than the other layers of the abdominal wall, it remains intact even though the underlying musculature and fascia are disrupted which gives rise to TAWH.

Traumatic abdominal wall hernias are produced by the direct blunt trauma from an object that has insufficient force to penetrate the skin, yet able to disrupt the deeper tissues of muscles and fascia. This is possible because the skin is more elastic than the rest of the layers<sup>1</sup>. There are three major types of traumatic abdominal wall hernias based on the mechanism of injury and the size of the defect. Type I abdominal wall hernia involves a small defect caused by blunt trauma. Type II hernia is a larger defect developed during the high-energy transfer events such as motor vehicle crash or fall from a height. Type III hernias are those defects that involves intraabdominal bowel herniation that has been described for deceleration injuries<sup>2</sup>. Handlebar hernias are often under type I abdominal wall hernias and associated intraabdominal injuries are rare<sup>3,4</sup>. Although handlebar injury was the reason for our case, the presentation was typical of type III hernia.

The diagnosis is usually made on the basis of history and physical examination. However, ultrasonography and CT scans may be helpful in difficult cases<sup>5,6</sup>. In rare cases, the hernia would not be identified until diagnostic laparoscopy<sup>7</sup> or exploratory laparotomy<sup>8</sup> was performed for the associated injuries. Some criteria have been proposed to identify traumatic hernias: absence of preexisting hernia in the same location, evidence of abdominal injury at presentation and immediate or delayed development of the hernia (usually close to the site of injury). In our case, clinical picture and X-Ray confirmed the diagnosis.

With the exception of the rare case of thoracic handlebar hernia<sup>9</sup> all other reported cases were related to the abdominal wall. The abdominal wall hernia is usually found at weak anatomical locations such as the region encompassing the lower lateral abdomen to the rectus sheath. This explains that in the majority of the reported cases of handlebar hernia, including our case, the abdominal wall defect was in the lower abdomen<sup>2,3</sup>. Only two cases were reported for the upper quadrant of the abdomen<sup>1</sup>. The abrupt increase in intraabdominal pressure is responsible for the poor correlation between the site of impact and the resultant defect<sup>3</sup>.

The majority of the cases described with handlebar hernias were caused by low-energy mechanisms such as bicycle or motorcycle. Therefore, in most of the cases, there was no significant intraabdominal injury.<sup>1,4,5</sup> In few cases, the hernia was caused by high-energy mechanism such as motor-car accidents<sup>3,10</sup>. These cases have been reported with significant intraabdominal injury. The most commonly reported injuries were mesenteric and serosal tears. There are two possible mechanisms of blunt mesenteric injuries: (1) a crushing force applied to the bowel against the spine and (2) shearing forces of the bowel and mesentery along the lines of attachment.<sup>[3]</sup>

After dealing with all associated intraabdominal injuries, definitive treatment of these hernias mandates surgical exploration and prompt repair to prevent incarceration or strangulation. This repair can be performed with primary closure if the tissue allows or with prosthetic material if the defect is too large<sup>11</sup>. Debate exists regarding the local wound exploration vs. midline exploratory laparotomy to rule out the intraabdominal injuries<sup>12</sup>.

#### IV. Conclusion

Posttraumatic tender subcutaneous swelling with bruising and ecchymosis of the skin. On physical examination, a reducible hernia or swelling with underlying defect may be detected. CECT and USG of the abdomen are the investigations of choice. Surgery is required to avoid the complications such as incarceration or strangulation and subsequent morbidity.

#### Bibliography

- [1]. Dimyan W, Robb J, MacKay C. Handlebar hernia. *J Trauma*. 1980;20:812–3.
- [2]. Goliath J, Mittal V, McDonough J. Traumatic handlebar hernia: A rare abdominal wall hernia. *J Pediatr Surg*. 2004;39:e20–2.
- [3]. Cheng S, Ko W, Liu C. Handlebar hernia: A misleading term. *Injury Extra*. 2005;36:309–11.
- [4]. Chen HY, Sheu MH, Tseng LM. Bicycle-handlebar hernia: A rare traumatic abdominal wall hernia. *J Chin Med Assoc*. 2005;68:283–5.
- [5]. Prada Arias M, Dargallo Carbonell T, Estevez Martinez E, Bautista Casanovas A, Varela Cives R. Handlebar hernia in children: Two cases and review of the literature. *Eur J Pediatr Surg*. 2004;14:133–6.
- [6]. Mitchiner JC. Handlebar hernia: Diagnosis by abdominal computed tomography. *Ann Emerg Med*. 1990;19:812–3.
- [7]. Iinuma Y, Yamazaki Y, Hirose Y, Kinoshita H, Kumagai K, Tanaka T, et al. A case of a traumatic abdominal wall hernia that could not be identified until exploratory laparoscopy was performed. *Pediatr Surg Int*. 2005;21:54–7.
- [8]. Sahdev P, Garramore RR, Jr, Desani B, Ferris V, Welch JP. Traumatic abdominal hernia: Report of three cases and review of the literature. *Am J Emerg Med*. 1992;10:237–41.
- [9]. Holmes JH, 4th, Hall RA, Schaller RT, Jr Thoracic handlebar hernia: Presentation and management. *J Trauma*. 2002;52:165–6.
- [10]. Huang CW, Nee CH, Juan TK, Pan CK, Ker CG, Juan CC. Handlebar hernia with jejunal and duodenal injuries: A case report. *Kaohsiung J Med Sci*. 2004;20:461–4.
- [11]. Jones BV, Sanchez JA, Vinh D. Acute traumatic abdominal wall hernia. *Am J Emerg Med*. 1989;7:667–8.
- [12]. Perez VM, McDonald AD, Ghani A, Bleacher JH. Handlebar hernia: A rare traumatic abdominal wall hernia. *J Trauma*. 1998;44:568–70.