

A Fetal Study of Sciatic Nerve Division and Its Clinical Implications

Dr Tanusri Debbarma¹, Dr Kaushik Debbarma²

¹Senior Resident, Dept of Anatomy, AGMC & GBP Hospital, Agartala, Tripura, India.

²Senior Resident, Dept of Paediatrics, NEIGRIHMS, Shillong, Meghalaya, India.

Abstract: Sciatic nerve is a branch of the lumbo-sacral plexus that controls the neurological activities of the hamstrings and all the other muscles of the lower limb below the knee. Study on the course and variations of sciatic nerve and its division in developing fetuses on both lower limbs of 30 fetuses from (14 weeks to 40 weeks). Formalin fixed fetuses were dissected at Department Of Anatomy, RIMS, Imphal, after getting formal permission from the Institutional Ethics Committee, RIMS, Imphal. The highest incidence of sciatic nerve division was found at lower 1/3 -70%, whereas upper 1/3 and middle 1/3 had 23.3% and 6.6% respectively. This might be useful for regional anaesthesia particularly in children as this is now the prefer route of anaesthesia for surgical intervention of the foot in children. Complete sciatic nerve blockade with local anaesthetics may fail even after multiple attempts if the sciatic nerve is present as separately sheathed bundle up to the lower level.

I. Introduction

Ischiadic Nerve (Greek “Is-chiadicus”) ^[1] or sciatic nerve is the largest, longest, thickest and widest nerve in human body and approx. 2 cms wide at their origin. ^[2] It is formed in the pelvis, leaves the pelvis through the greater sciatic foramen below piriformis to enter the gluteal region. It passes behind the hip joint and enters the back of the thigh. At the superior angle of popliteal fossa, it terminates into tibial and common peroneal nerve. ^[1,3,4,5] The sciatic nerve is so large that it receives a named branch of inferior gluteal artery, the artery to the sciatic nerve or arteria comitans nervi ischiadici. The sciatic nerve supplies no structure in the gluteal region. It supplies the posterior thigh muscle, leg and foot muscle. It also supplies the articular branches to all joints of lower limbs. ^[1,6,7]

II. Aims And Objects

The aim of this study is to see the course and variations of sciatic nerve and its division with reference to the lateral condyle of femur in developing fetuses

III. Materials And Methods

This study was done in the Department of Anatomy, Regional Institute of Medical Sciences, Imphal, in 30 fetuses (60 Limbs) from 14 to 40 weeks of gestational ages (GA), (Male-16, Female-14). Collected from Obstetrics & Gynaecology, Department in RIMS, Imphal, as a product of MTP (under MTP Act, 1971) & stillbirth. Institutional Ethics Committees has been taken. Immediately after collection, fetuses were immersed and fixed in 10% formalin. Gestational ages were determined by Crown-Rump length (CRL). Foetus showing gross maceration and malformation were excluded. The gluteal regions of the fetuses were dissected and exposed to popliteal fossa. The sciatic nerves on both sides were traced and studied. Femur length (FL) and sciatic nerve division were measured with the help of sliding vernier calliper (Femur length from lateral condyle to greater trochanter & from lateral condyle to SN division)

IV. Results And Observation

Among the 60 lower limbs studied, the level of the sciatic nerve separation in the upper 1/3, middle 1/3, lower 1/3 were 23.3%, 6.6%, 70% on the right side and on the left side were 20%, 3.3% and 76.6% respectively. (Fig. 1, 2, 3). We also observed trifurcation of sciatic nerve in one right lower limb (1.66%). (Fig. 4).

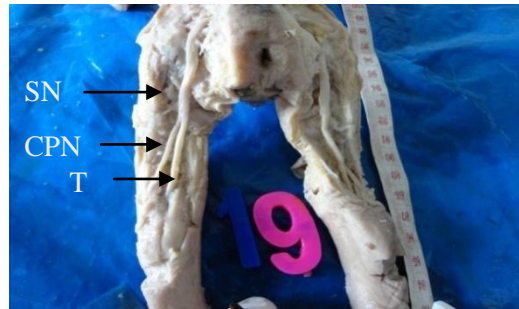


Fig.1: Photograph showing sciatic nerve (SN) division at the level of (L) midthigh Tibial nerve (TN), Common peroneal nerve (CPN).

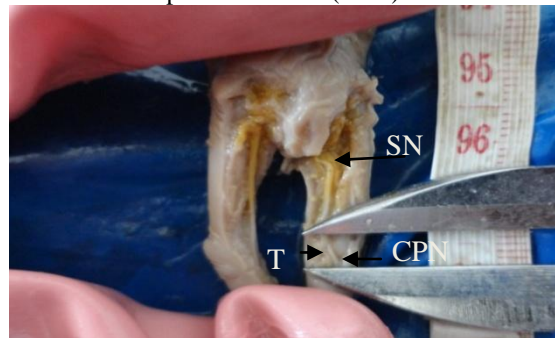


Fig.2: Photograph showing sciatic nerve (SN) division at the level of lower thigh, Tibial nerve (TN), Common peroneal nerve (CPN).

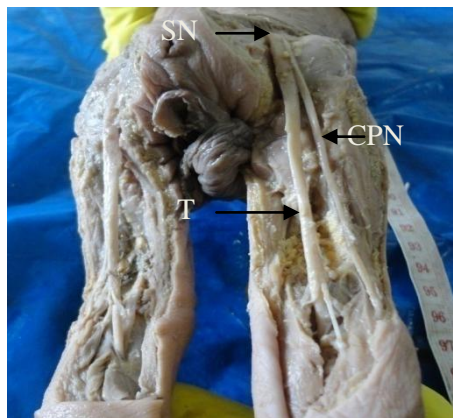


Fig.3: Photograph showing sciatic nerve (SN) division at the level of upper thigh Tibial nerve (TN), Common peroneal nerve (CPN).

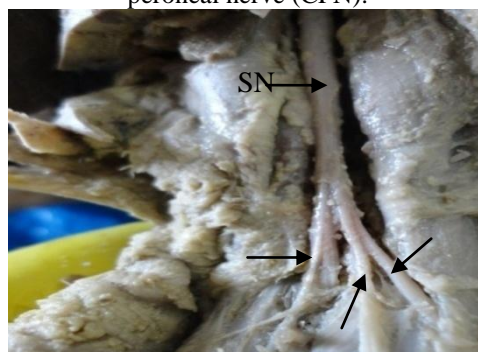


Fig.4: Photograph showing Trifurcation of sciatic nerve (SN) division at the level of lower thigh

V. Discussion

The two parts of the sciatic nerve develop separately in early embryonic stage and maintain their individual identity throughout their extent, even though joined together to form a single nerve trunk by a common connective tissue sheath.^[3]Ogeng'o JA et al⁸ stated separation of sciatic nerve 67.1% in the popliteal fossa, 10.4% in the middle third of the thigh, 2.4% in the gluteal region. Hollinshead WH stated that 10-15 %

separates at their origin, whereas, there is no such division in our study. The SN divided at a distance range of 50 to 180 mm above the popliteal fossa by Saleh H et al^[9] and minimal distance of sciatic nerve 13 mm as stated by konrad C et al^[10]. In our study we found that the range was from 2mm-65mm. Ugrenovic S et al^[11] stated that higher level of sciatic nerve division may be the cause of an incomplete block (popliteal fossa-72.5%, mid thigh-9%, upper thigh 18.5%). According to Moore et al^[6] 12.2 % of 640 limbs the sciatic nerve divide before exiting the greater sciatic foramen and the common fibular division passed through the piriformis. In 0.5% of cases, the common fibular division passed superior to the muscle, where it is especially vulnerable to injury during intragluteal injection. Berkol N et al^[12] stated that sex and side does not play an important role in the passage incidence of the common fibular nerve. 87.5% below piriformis, 12% through piriformis, 0.5% above the piriformis. The low division and trifurcation of SN noted in our study may be a boon to surgeon who do the popliteal block for leg surgery as stated by Nayak S.^[13]

Comparison of S.N. division at popliteal fossa with other authors

A u t h o r s	Years	Work done on	N o	%
OgengoJA et al ^[8]	2011	C a d a v e r	1 6 4	6 7 . 1
Ugrenovic S et al ^[11]	2005	Human foetus	2 0 0	7 2 . 5
Guvencer M et al ^[14]	2009	C a d a v e r	5 0	7 6
Sharma S et al ^[15]	2012	C a d a v e r	6 0	7 2 . 5
Present study	2012	Human fetus	6 0	7 3 . 3

VI. Conclusion

- The high terminal division of sciatic nerve must be kept in mind during performing the popliteal block anaesthesia, the low division and trifurcation resulting in failure even after multiple attempts.
- Variation of sciatic nerve may complicate surgery & interpretation of sciatic neuropathy. Radiologist may erroneously report an abnormal SN.
- Trifurcation of sciatic nerve is ideal for graft.

Reference

- [1]. Mahadeven V, editor. Pelvic girdle and lower limb. In Standring S , Borley NR, Collins P, Crossman AR, Gatzoulis MA, Healy JC, Johnson D, et al. editors. Gray’s Anatomy: The Anatomical Basis of Clinical Practice. 40th ed. London: Churchill Livingstone Elsevier, 2008: 1329-1463.
- [2]. Hollinshead WH. Anatomy for surgeons- the back and limb. 2nd ed. New York: Harper & Row Publishers, Inc. 1968
- [3]. Moore KL, Persaud TVN. The Developing Human Clinically oriented embryology. 5th ed. Philadelphia: WB Saunders Company; 1993.
- [4]. Sadler TW. Langman’s medical embryology. 11th ed. New Delhi: Lippincott Williams & Wilkins; 2010.
- [5]. Arey LB. Developmental anatomy—a textbook and laboratory manual of embryology. 7th ed. Philadelphia: W.B. Saunders Company; 1966.
- [6]. Moore KL, Dally AF, Agur AMR. Clinically oriented anatomy. 6th ed. Philadelphia: Wolters Kluwer; 2010.
- [7]. Sinnatamby CS. Last’s anatomy—regional and applied. 11th ed. Edinburgh: Churchill Livingstone Elsevier; 2006.
- [8]. Ogeng’o J A, El-Busaidy H, Mwika PM, Khanbhai MM, Munguti J. Variant anatomy of sciatic nerve in a black kenyan population. Folia Morphol (Warsz) 2011 Aug;70(3):175-9.
- [9]. Saleh H, El-Fark M, Abdel ahmed GA. Anatomical variation of sciatic nerve division in the popliteal fossa and its implication in popliteal nerve blockade. Folia morphol 2009;68;4 : 256-9
- [10]. Konrad C, Johr M. Blockade of the sciatic nerve in the popliteal fossa: a system for standardization in children. Anesth Analg 1998;87:1256-8
- [11]. Ugrenovic S, Jovanovic I, Kristic V, Stojanovic V, Vasovic L, Antic S, Pavlovic S (2005) The level of sciatic nerve division and its relations to the piriform muscle. Vojnosanit pregl. 62:45-9.
- [12]. Berkol N, Mouchet A, Gogen H. Note sur le niveau de bifurcation du grand nerf sciatique. Ann d’anat Pathol et d’Anat Norm Med 1935; 12: 596-600.
- [13]. Nayak S. An unusual case of trifurcation of sciatic nerve. Neuroanatomy. 2006; 5: 6-7.
- [14]. Guvencer M, Iyem C, Akyer P, Tetik S, Naderi S. Variations in the high division of the sciatic nerve and relationship between sciatic nerve and the piriformis. Turk neurosurg 2009;19:139-44.
- [15]. Sharma S, Khullar M. Direct origin of tibial nerve and common peroneal nerve from. Lumbosacral plexus. Jkpractitioner 2012;17(1-3):54-7.