

Lemierre Syndrome

Prof. N. Tamilselvan MS¹, Dr. P. V. Dhanapal MS²

¹(Associate Professor, Department of General Surgery, Government Mohan Kumaramangalam Medical College, Salem/ Tamilnadu Dr.M.G.R. Medical university, India)

²(Senior Assistant Professor, Department of General Surgery, Government Mohan Kumaramangalam Medical College, Salem/ Tamilnadu Dr.M.G.R. Medical university, India)

Abstract: Lemierre's syndrome also known as postanginal shock including sepsis and human necrobacillosis refers to thrombophlebitis of the internal jugular vein. It most often develops as a complication of a bacterial sore throat infection in young, otherwise healthy adults. It creates a peritonsillar abscess, a blood clot, filled with bacteria near the tonsils in the jugular vein. An Incision & Drainage must be done. We are reporting two such cases that were managed in our hospital.

Keywords: Lemierre's syndrome, Necrobacillus, Peritonsillar abscess, Postanginal shock,

I. Introduction:

Lemierre's syndrome also known as postanginal shock including sepsis and human necrobacillosis refers and infection in young, otherwise healthy adults. It creates a peritonsillar abscess and a thrombus in the internal jugular vein because of the direct spread of infection to it. If this infection is not delt within time the thrombus will break down and produce septic emboli and multiple pyemic abscess.

II. Case Report:

2.1. Case 1:

A 57 year old female came to us with a history of swelling and pain in the right side of the neck for the past ten days. She had throat pain and trismus and she was treated outside with antibiotics. On examination a 10 X 6 cm diffuse swelling was seen on the right side of the neck just below and behind the angle of the mandible. Skin was stretched and shiny. Fluctuation was present at the summit of the swelling. Congestion of the oropharynx was present. Fullness was seen at the right fauces. A Provisional diagnosis of Parapharyngeal abscess was made.

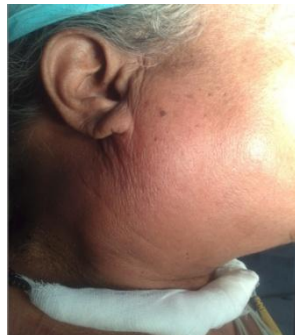


Fig 1: Clinical picture showing Right side swelling.

2.1.1. Investigation

CT was done to know the extent of the abscess. CT revealed a suppurating lymph node on the right side of the neck and thrombosis of the adjoining internal jugular vein.



Fig 2: CT picture showing Right side IJV thrombosis

2.1.2. Treatment:

An I& D was done under GA and the patient was on heparin for five days. Patient was also put on inj.cefaperazonesulbactam 1.5 gmi.vbd and inj.metronidazole 500 mg i.vtds.

2.2. Case 2:

A 27 year old male presented with a swelling and pain in the left side neck for past 10 days, fever for the past 10 days and inability to swallow for past 7 days. Patient treated with antibiotics elsewhere. On examination, woody hard swelling seen on the left side of the neck. Tenderness and trimus present. Case was managed with incision and drainage, antibiotics and intravenous heparin.

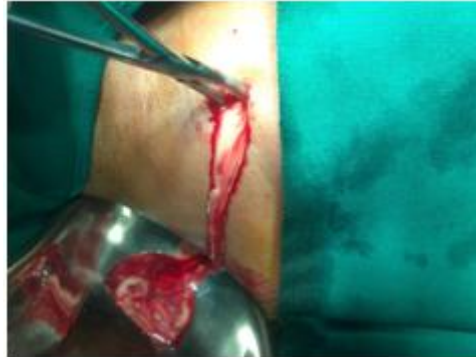

Fig 3: Peroperative picture for I & D on left side.

III. Discussion

The bacteria causing Lemierre's syndrome are anaerobic bacteria that are typically normal components of oropharyngeal flora. Species of *Fusobacterium*, specifically *Fusobacterium necrophorum*, are mostly the causative bacteria, but various other bacteria e has been implicated. Lemierre's syndrome starts as a sore throat and cervical lymphadenitis is produced which may produce a suppurative lymphadenitis[1]. The infection and inflammation affects the adjacent internal jugular vein by incontinuous spread which leads to phlebitis and thrombus formation. Usually this infection is a pharyngitis (which occurred in 87.1% of patients as reported by a literature review), but it can also be initiated by an otitis, a mastoiditis, a sinusitis or a parotitis[2]. Laboratory investigations reveal signs of a bacterial infection with elevated C-reactive protein, erythrocyte sedimentation rate and white blood cells (notably neutrophils). Platelet count can be low or high. Liver function tests and renal function tests are often normal. Management includes incision and drainage of pus followed by antibiotics according to culture sensitivity and venous thromboses is managed with heparin initially and followed by oral anticoagulants[3].

IV. Conclusion:

We conclude by saying that, whenever we are treating any deep seated suppurative lesions in the neck the possibility of lemierre's syndrome should be kept in mind and investigations must be done to rule out IJV thrombosis.

References

- [1]. Chirinos JA, Lichtstein DM, Garcia J, Tamariz LJ (November 2002). "The evolution of Lemierre syndrome: report of 2 cases and review of the literature". *Medicine (Baltimore)* (Lippincott Williams & Wilkins) 81 (6):
- [2]. Sinave CP, Hardy GJ, Fardy PW (March 1989). "The Lemierre's syndrome: suppurative thrombophlebitis of the internal jugular vein secondary to oropharyngeal infection". *Medicine (Baltimore)* (Williams & Wilkins) 68 (2):
- [3]. NCBI PubMed, Bentley TP, Brennan DF (August 2009). "Lemierre's syndrome: methicillin-resistant *Staphylococcus aureus* (MRSA) finds a new home.". *Medicine (Orlando)* (Bentley & Brennan) 37 (2): 131