

## Rhodotorula glutinis and Stephanoascus ciferrii as causes of Onychomycosis: Two rare case presentations.

Asifa Nazir<sup>1</sup>, Farhath Kanth<sup>2</sup>

Associate Professor, Department of Microbiology, Government Medical College, Srinagar<sup>1</sup>  
Demonstrator, Department of Microbiology, Government Medical College, Srinagar<sup>2</sup>

---

**Abstract:** Onychomycosis is a fungal infection of nail, its matrix, and other nail parts which is usually caused by dermatophytes. However number of nail infections due to yeast and nondermatophyte moulds (NDM) is also increasing. Although *Candida albicans* accounts for most of the cases of onychomycosis caused by yeasts, there has been a change in the epidemiology of *Candida* infections, characterized by a progressive shift from a predominance of *Candida albicans* to non-*albicans* *Candida* species. We reports two cases of Onychomycosis caused by uncommon yeasts; *Rhodotorula glutinis* and *Stephanoascus ciferrii*.

**Key words:** Onychomycosis, *Rhodotorula glutinis*, *Stephanoascus ciferrii*

---

### I. Introduction

Onychomycosis is a common superficial fungal infection of the nails, which is usually caused by dermatophytes, yeast and non-dermatophytic moulds. However, there are striking geographic differences in the epidemiology and etiology of onychomycosis, especially in the frequency with which each group of fungi is responsible for infections. <sup>[1]</sup> Although dermatophytes are the most common cause, approximately 5%-17% of fungal nail infections are caused by yeasts. <sup>[2, 3]</sup> Among the yeasts although *Candida albicans* is the most prevalent species involved in both mucocutaneous and disseminated infections, the incidence of candidiasis due to non-*albicans* *Candida* (NAC) spp. is increasing. <sup>[4]</sup> Several factors like severe immunosuppression or illness, prematurity, use of broad spectrum antibiotics, and empirical use of antimycotic drugs are reported to be associated with this change. <sup>[5]</sup>

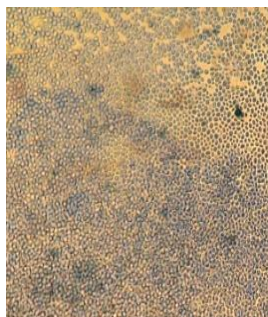
Opportunistic non-dermatophyte molds (NDM) are found in nature as soil saprophytes and plant pathogens. They are fast growing, have universal distribution and are often unnoticed laboratory contaminants <sup>[6]</sup>. The non-dermatophytic moulds most frequently isolated from diseased nails are *Aspergillus* spp., *Fusarium* spp., *Scopulariopsis brevicaulis*, *Scytalidium dimidiatum*, *S. hyalinum*, *Onychocola Canadensis* <sup>[7,8,9]</sup>. These infections are however dependent on the population, geographic area and the mycological or diagnostic methods used.

In our study we report two cases of nail infection due to *Rhodotorula glutinis* and *Stephanoascus ciferrii* in two immunocompetent patients.

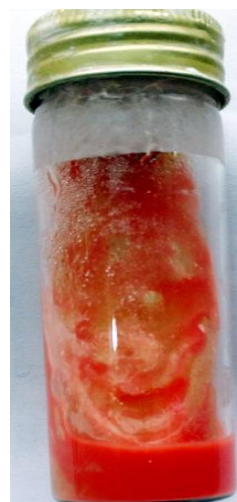### II. Case report one.

A 45 year old female patient, housewife by occupation presented with complaints of nail deformity and thickness of toe nails for more than 6 months duration. On examination the affected toenails were lustreless and dystrophied. The distal part of the nail appeared soft, black coloured with irregular margin. The general physical examination was normal. Patient did not have any chronic disease, malignancy or familial genetic disorder and did not give any history of previous trauma. There was no history of long term broad spectrum antibiotic, antifungal or systemic steroids intake. Other immunosuppressive states like AIDS were absent.

**Microbiological examination:**-Nail clippings from affected toes were collected aseptically after cleaning with 70% alcohol and were subjected to 40% KOH examination. The sample was cultured on two sets of media: one containing Sabaroud's dextrose agar (SDA) with 0.05% chloramphenicol and the second having 0.05% chloramphenicol and 0.5% cycloheximide and were incubated at 25°C and 37°C for 4 weeks. Culture showed orange coloured creamy colony, (Figure 1) which on lactophenol cotton blue (LCB) examination showed the presence of yeast cells (Figure 2). Gram staining of these colonies showed the yeast cells forming blastospores. Morphological evaluation in the Corn Meal-Tween 80 agar revealed oval/round budding yeast at 25°C for 72 hours, with no pseudohyphae formation. The pathogen was identified as *Rhodotorula glutinis/mucilaginosa* according to the Vitek2 compact 60 system (BioMerieux India ®) identification system using Yeast Biochemical Card 2. Assimilation features using Vitek 2 automated system along with conventional methods identified the yeast as *Rhodotorula glutinis*.



**Fig 1.** Yeast cells seen on LCB staining

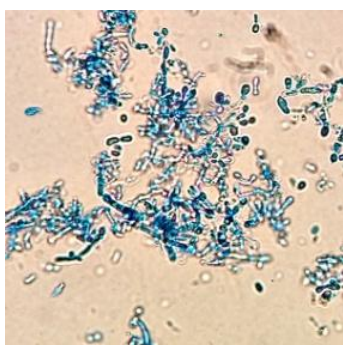


**Fig 2.** Orange coloured colony of Rhodotorula on SD agar

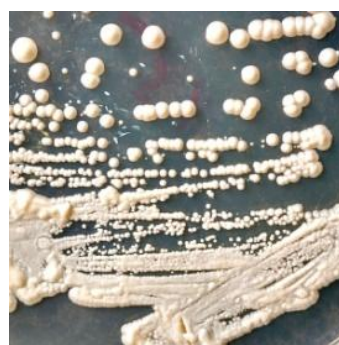### III. Case Report two.

A 32 year old female from Srinagar presented with dystrophy of two toe nails of the left foot. Transverse striations were present on the affected nails along with white patches distally. There was also swelling of the nail bed along with greyish discoloration of the nail. The patient gave no history of trauma, or any long term steroid intake or any other drug use. Patient did not have any chronic disease, malignancy or familial genetic disorder and other immunosuppressive states like AIDS were absent.

For mycological examination, scrapings were collected from the basal layer of the nail plate as well as areas of hyperkeratosis from the affected nails aseptically after cleaning with 70% alcohol. The specimen was subjected to direct microscopic examination in 40% KOH mounts. Also the nail specimen was cultured in two sets of media ; one containing Sabaroud's dextrose agar (SDA) with 0.05% chloramphenicol and the second having 0.05% chloramphenicol and 0.5% cycloheximide and were incubated at 25°C and 37°C for 4 weeks. Yeast like mucoid growth (figure3) was seen after 48 hours of incubation. Lactophenol cotton blue examination (Figure 4) and Gram stain of the colony was carried out which showed the presence of yeast cells. To characterize the genus and species, and confirm the conventional mycological diagnosis, a test of characterization and identification was performed by automated Vitek2 compact 60 system (BioMerieux India ®) using pure colonies streaked in SDA medium, incubated at 37 °C for 24 h. The pathogen was identified as **Stephanoascus ciferrii** and assimilation features detected by automated Vitek Yeast Biochemical Card 2 system. Antifungal susceptibility test results were as follows: amphotericin B (MIC= 8 µg/mL), fluconazole (MIC = 32 µg/mL), caspofungin (MIC = 0.5µg/mL) and fluocytosine <=1.



**Fig 3.** Budding yeast cells of S.ciferrii seen on LCB staining



**Fig 4.** Mucoid colony of S.ciferrii

### IV. Discussion.

As longer lives have become possible due to advances in medical technology and diagnostic technology in recent years, weakly toxic fungi have been emerging as causative agents of opportunistic infections. Onychomycosis due to non albicans candida species has shown an upward trend in the past two decades.

Rhodotorula sp is widespread in nature and isolated from environmental sources and products.<sup>[10]</sup> It was previously considered non-pathogenic, but in the last two decades, it has emerged as an opportunistic etiologic agent, particularly in immunocompromised patients. The sharp rise in the number of cases due to

Rhodotorula has been linked to new modalities of treatment related to critical care medicine and transplantation, short and long term Central venous catheter with or without parental nutrition, broad spectrum antibiotics, and chemotherapy. <sup>[11, 12]</sup>

The first case of Rhodotorula infection, a patient with endocarditis, was reported in 1960 by Louria <sup>[13]</sup>. After this first case, several articles have been published and an increase in the number of Rhodotorula infections has been reported, mainly in the last two decades. Previously considered a low virulence organism in comparison to Candida or Trichosporon, Rhodotorula must be considered a potential pathogen in patients with immunosuppression and Central Venous Catheter. <sup>[14, 15]</sup> Rhodotorula infections in immunocompetent patients are extremely rare. In the literature Rhodotorula mucilaginosa and R. minuta were found as the causative agent in two cases of onychomycosis. <sup>[16, 17]</sup> while as R. glutinis was the cause in two cases of onychomycosis. <sup>[18, 19]</sup> In these cases, the patients were immunocompetent, as in the current case <sup>[16, 17, 18, 19]</sup>.

Candida ciferrii was first described by Kreger van Rij in 1965. <sup>[20]</sup> Stephanoascus ciferrii complex, a teleomorph of Candida ciferrii, is an ascomycetous yeast-like fungus that has been rarely reported as a cause of human infection. However, in immunocompromised host it can cause human infection. <sup>[21, 22]</sup> In humans, isolates have been drawn mainly from the toe nails of elderly patients with trophic disorders of the legs <sup>[23]</sup>. Knowledge of the natural habitat of Candida ciferrii is limited. S. ciferrii has previously been isolated from blood, wound swab, aural discharge and nail sample. Principal sites of infection reported are in ear infections, patients with AML, immunodeficiency patients, superficial and deep mycosis <sup>[24, 25, 26]</sup>. Also this species has a strong tendency to become resistant especially in patients on fluconazole prophylaxis. In our case also the isolate was resistant to amphotericin B and showed intermediate resistance to fluconazole. Therefore, in vitro susceptibility testing is mandatory for the selection of an appropriate antimycotic drug.

## V. Conclusion

In conclusion, Rhodotorula spp. and Stephanoascus ciferrii are rarely seen yeasts that usually cause infection especially in immunosuppressed people. But as seen in our two case reports R. glutinis and Stephanoascus ciferrii can cause onychomycosis in immunocompetent patients also. It is therefore important to make a complete mycological study (microscopic examination with KOH and culture) in patients with suspicion of onychomycosis.

## References

- [1] Haneke E. Fungal infections of the nail: nail disease. *Semin Dermatol* 1991; 10: 41–51.
- [2] B, ed. *Cutaneous fungal infections*. New York: Igaku-Shoin, 1992:106-23.
- [3] Clayton YM. Clinical and mycological diagnostic aspects of onychomycosis and dermatomycoses. *Clin Exp Dermatol* 1992; 17(suppl 1): 37-40.
- [4] Gupta AK, Ryder JE, Baran R, Summerbell RC. Non-dermatophyte onychomycosis. *Dermatol Clin* 2003; 21:257-68.
- [5] J. C. O. Sardi, L. Scorzoni, T. Bernardi, A. M. Fusco-Almeida, and M. J. S. Mendes Giannini, "Candida species: current epidemiology, pathogenicity, biofilm formation, natural antifungal products and new therapeutic options," *Journal of Medical Microbiology* 2013; 62 (1):10–24.
- [6] Asbati M, Smythe B, Cavallera E. Onychomycosis por hongos no dematofitos. Estudio retrospectivo en 4 años. *Rev Soc Ven Microbiol*. 2002; 22:147-52.
- [7] Sharma D, Capoor M R, Ramesh V, Gupta S, Shivaprakash M R, Chakrabarti A. A rare case of onychomycosis caused by *Emericella quadrilineata* (*Aspergillus tetrazonus*). *Indian J Med Microbiol* 2015; 33:314-6
- [8] Fell JW, Boekhout T, Fonseca A, Scorzetti G, Stutzell-Tallman A. Biodiversity and systematics of basidiomycetous yeasts as determined by large-subunit rDNA D1/D2 domain sequence analysis. *Int J Syst Evol Microbiol* 2000; 50: 1351-1371.
- [9] J. García-Suárez, P. Gómez-Herruz, J. A. Cuadros, and C. Burgaleta, "Epidemiology and outcome of Rhodotorula infection in haematological patients," *Mycoses* 2011 ;54, (4): 318–324.
- [10] Nagahama T, Hamamoto M, Nakase T, Horikoshi K. *Rhodotorula lamellibrachii* sp. nov., a new yeast species from a tubeworm collected at the deep-sea floor in Sagami bay and its phylogenetic analysis. *Antonie Van Leeuwenhoek* 2001; 80: 317-323.
- [11] Anaissie E, Bodey GP, Kantarjian H, Ro J, Vartivarian SE, Hopfer R, Hoy J, Rolston K. New spectrum of fungal infections in patients with cancer. *Rev Infect Dis* 1989; 11: 369-378.
- [12] Lanzafame M, De Chechi G, Parinello A, Trevenzoli M, Cattelan AM. *Rhodotorula glutinis*-related meningitis. *J Clin Microbiol* 2001; 39: 410.
- [13] Louria DB, Greenberg SM, Molander DW. Fungemia caused by certain nonpathogenic strains of the family Cryptococcaceae. Report of two cases due to *Rhodotorula* and *Torulopsis glabrata*. *N Engl J Med* 1960; 263: 1281-1284.
- [14] Gomez-Lopez A, Mellado E, Rodriguez-Tudela JL, Cuenca-Estrella M. Susceptibility profile of 29 clinical isolates of *Rhodotorula* spp. and literature review. *J Antimicrob Chemother* 2005; 55: 312-316.
- [15] Rusthoven JJ, Feld R, Tuffnell PG. Systemic infection by *Rhodotorula* spp. In the immunocompromised host. *J Infect* 1984; 8: 241-246.
- [16] M. M. L. da Cunha, L. P. B. dos Santos, M. Dornelas-Ribeiro, A. B. Vermelho, and S. Rozental, "Identification, antifungal susceptibility and scanning electron microscopy of a keratinolytic strain of *Rhodotorula mucilaginosa*: a primary causative agent of onychomycosis," *FEMS Immunology and Medical Microbiology* 2009 ;55(3): 396–403.
- [17] Zhou, M. Chen, H. Chen, W. Pan, and W. Liao, "Rhodotorula minuta as onychomycosis agent in a Chinese patient: first report and literature review," *Mycoses* 2014 ; 57(3):191–195.
- [18] Uludag Altun, H., Meral, T., Turk Aribas, E., Gorpelioglu, C., Karabicak, N. 2014. A case of Onychomycosis caused by *Rhodotorula glutinis*. *Case Rep. Dermatol. Med.*, 2014: 563261.

- [19] Vinod Maurya, P. K. Khatri, Saroj Meena, Archana Bora, K. L. Seervi, Laxmi Rathore and Shivani Khullar Onychomycosis Caused by *Rhodotorula glutinis*: A Case Report *Int.J.Curr.Microbiol.App.Sci.*2015.4(11): 331-335
- [20] Kreger-Van Rij NJ .*Candida ciferrii*, a new yeast species. *Mycopathol Mycol Appl* 1965 ; 26:49–52.
- [21] Gunsilius E, Lass-Flörl C, Kähler CM, Gastl G, Petzer AL. *Candida ciferrii*, a new fluconazole-resistant yeast causing systemic mycosis in immunocompromised patients. *Ann Hematol.* 2001;80:178-9
- [22] García-Martos P, Ruiz-Aragón J, García-Agudo L, Saldarreaga A, Lozano MC, Marín P. *Candida ciferrii* in an immunocompromised patient. *Rev Iberoam Micol.* 2004; 21:85-6.
- [23] Gentile L de, Bouchara JP, Le Clec'h C, Cimon B, Symoens F, Chabasse . Prevalence of *Candida ciferrii* in elderly patients with trophic disorders of the legs. *Mycopathologia.*1995; 131:99–102.
- [24] Soki H, Nagase Y, Yamazaki K, Oda T, Kikuchi K. Isolation of the yeast-like fungus *Stephanoascus ciferrii* by culturing the aural discharge of a patient with intractable otitis media. Case report. *Kansenshogaku Zasshi* 2010; 84:210-12.
- [25] Gunsilius E, Lass-Flörl C, Kähler CM, Gastl G, Petzer AL. *Candida ciferrii*, a new fluconazole-resistant yeast causing systemic mycosis in immunocompromised patients. *Ann Hematol* 2001; 80:178-9.
- [26] Cendejas-Bueno E, Gomez-Lopez A, Mellado E, Rodriguez-Tudela JL, Cuenca-Estrella M. Identification of pathogenic rare yeast species in clinical samples: Comparison between phenotypical and molecular methods. *J Clin Microbiol* 2010; 48:1895-9.