

## Study of outcome of endovenous laser ablation as a minimally invasive technique for treatment of varicose veins.

<sup>1</sup>Shivaji Pole, <sup>2</sup>Monarch V. Shah, <sup>3</sup>Vivek S. Shah

<sup>1,2,3</sup>(Department of Interventional Radiology, Mahatma Gandhi Missions Medical College and Hospital, Aurangabad, India)

---

**Abstract:** The study was carried out to know the outcomes of endovenous laser ablation as a treatment for varicose veins and to study the effectiveness and safety of the laser fiber 810 nm wavelength used for ablation. 303 patients were diagnosed with varicose veins on color doppler and treated for the same by using a 810 nm diode laser. Foam sclerotherapy with injection Polidocanol was used concomitantly in a few cases. Tumescant anesthesia was delivered perivenously under ultrasonographic guidance prior to ablation. Immediately after the procedure a color doppler was performed to confirm occlusion of the ablated vein and to rule out deep vein thrombosis. Patients were then followed up and evaluated clinically and by ultrasound at 1 week, 1 month, 3 months, 6 months and yearly thereafter to exclude recurrence of varicose veins & to look for any adverse reactions. Successful occlusion of the veins was seen in 100% cases at 1 month. 1.5% of the patients had recurrence at 1 year follow up. 78.02% of patients had a sensation of tightness along the course of the veins and bruising was seen in 35.03% limbs. 2 patients had deep vein thrombosis. There have been no cases of skin burns, phlebitis or pulmonary embolism. Varicose veins can thus be treated by this modality under local anesthesia with low complication rates.

**Keywords:** varicose, endovenous, chronic venous insufficiency, ablation.

---

### I. Introduction

Lower venous insufficiency secondary to saphenous vein insufficiency is a common medical condition that decreases a patients quality of life (1,2). The best way to accomplish this was with ligation of the saphenous vein at its deep vein junction and removal of the abnormal saphenous vein segments i.e. high ligation and stripping (HL/S). Endovenous laser ablation (EVLA) is a newer technique which is minimally invasive and is a day care procedure. It eliminates reflux with less morbidity, improved cosmetic results and high patient satisfaction (2). In patients of varicose veins with ulcers, healing can be accomplished with ablation of both great saphenous and incompetent perforator veins (3). In 1999, Dr. Bone reported delivery of endoluminal laser energy (4). Endovenous laser treatment, which received approval from the US Food and Drug Administration in January 2002, allows delivery of laser energy directly into the blood vessel lumen. Nonthrombotic vein occlusion is accomplished by heating the vein wall with 810 nm wavelength laser energy delivered via a 600 µm laser fiber. Maximal contact between the laser fiber and the vein wall is necessary to cause sufficient damage to the vein resulting in wall thickening with eventual contraction and fibrosis of the vein (4). Anatomic success rates of EVLT have been reported between 85-100% (5). Endovenous Laser Ablation is one of several potential treatment options for patients with superficial venous insufficiency. It can safely, effectively, and durably eliminate reflux in truncal veins using only local anesthesia (5). Longterm results available in 499 limbs treated with endovenous laser demonstrate a recurrence rate of less than 7% at 2 - year follow - up (6). Compared with traditional open surgery, patients who undergo endovenous treatment experience less pain and recover more quickly (7).

### II. Materials and methods

This prospective study included patients who underwent endovenous laser ablation from December 2011 to December 2014 and was performed after due consent from the institutional ethics committee . Patients presenting to us with symptomatic varicose veins and also patients who were referred by other practitioners to us were examined. A general examination was performed which included history, physical examination, color Doppler and of lower limb veins. The following points were included in color Doppler examination of the lower limb venous system - a. Deep vein status b. Saphenofemoral junction reflux (Grade 1 - 4) c. Superficial veins - Great Saphenous Vein (dilated / not dilated) d. Saphenopopliteal Junction reflux e. Short Saphenous Vein (dilated / not dilated) f. Perforators (competent / incompetent) g. Deep venous system patency. Informed consent about the procedure was taken from the patients.

Inclusion Criteria - Patients with varicose veins caused by saphenofemoral junction (SFJ) incompetence with great saphenous vein (GSV) reflux and / or saphenopopliteal junction (SPJ)

incompetence or perforator incompetence as demonstrated by color doppler were included. Patients with symptomatic varicose veins (symptoms - pain, swelling, itching, skin discolouration, bleeding, etc.) and the ones with asymptomatic varicose veins (cosmetic purpose) were included. Patients with recurrence of varicose veins following surgery and ones with non healing venous ulcers were also included.

Exclusion criteria - Patients with Deep vein thrombosis and pregnant females were excluded from the study.

Description of technique - After clinical and imaging studies patients were taken for the procedure. Color Doppler examination was performed on table to confirm all findings. All aseptic precautions were taken. Local anesthesia in the form of 2% Lignocaine was given and ultrasonography (USG) guided puncture of the dilated superficial vein was done. After free backflow of blood into the needle a guidewire was passed into the vein and pushed upto the SFJ. Then a long sheath 4 Fr was pushed over the guide wire and the guide wire was then removed. Correct positioning of the sheath and the inserted laser fibre within was done under USG guidance i.e. 2cm away from SFJ to avoid deep vein ablation. Tumescence anesthesia i.e. 15 cc of 2% Xylocaine + 10 cc of sodium bicarbonate + 5 cc sensorcaine in 300 ml normal saline was given around the vein under USG guidance. Using appropriate energy and power, ablation of the veins was done. Residual varicosity even after ablation, if any as confirmed by USG, were treated by sclerotherapy using Polidocanol. Post ablation USG was done to confirm complete occlusion of dilated veins, incompetent perforators and to check patency of deep veins. Class II compression stockings (i.e. one with a gradient of 30 - 40 mm Hg) were applied to the limb upto the groin and the patients were asked to walk for 10 - 15 minutes post procedure. After observation for 30 minutes patients were discharged with medications and were asked to follow up at 1 week, 1 month, 6 months, 1 year and then yearly. Patients were instructed to wear the stockings for 48 hours continuously and thereafter in day time and during physical activity for a period of 6 months.

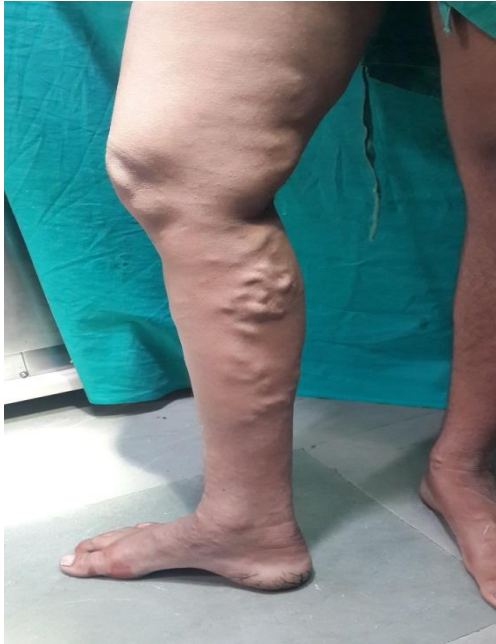### III. Results

Table 1. Baseline Characteristics

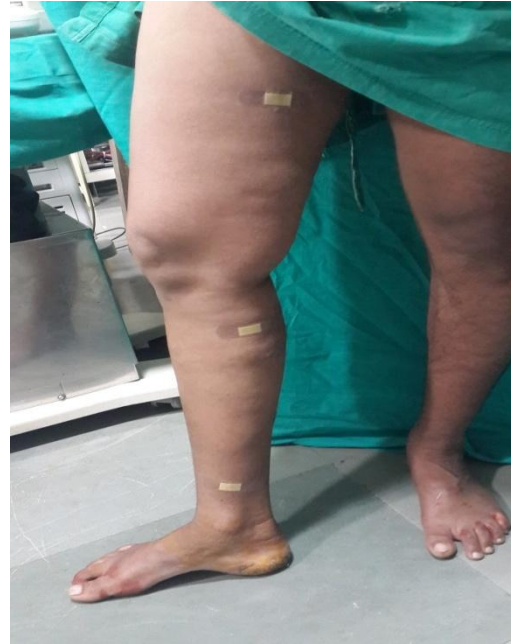|  |     |
|--|-----|
| Patients                                   | 303 |
| Male                                       | 221 |
| Female                                     | 82  |
| Total Limbs                                | 314 |
| Venous ulcers                              | 59  |
| Bleeding Varicose veins                    | 8   |
| Recurrent varicose veins following surgery | 4   |
| Cosmetic Purpose                           | 2   |
| Incompetent Great Saphenous Veins          | 300 |
| Incompetent Short Saphenous Veins          | 45  |
| Incompetent Perforators                    | 186 |

Pain and swelling over the limbs were the most common complaints with which the patients presented and were seen in 96.17% (302 of 314) of patients. Skin discoloration was seen in 17.19% (54 of 314) of patients. 18.78% (59 of 314) patients presented with venous ulcers and 2.54% (8 of 314) presented with bleeding varicose veins. 5 patients had partial deep vein thrombosis on color Doppler examination. 4 patients had history of undergoing varicose vein surgery in the past.

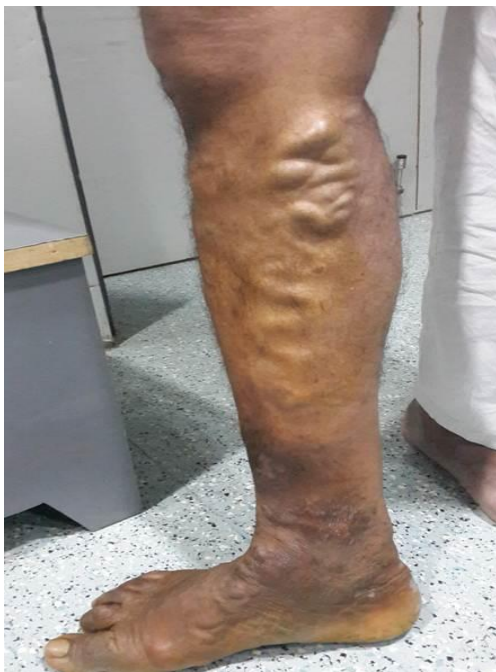Post ablation, occlusion was seen in 100% (314 of 314) of the cases. Sclerotherapy was performed in 6.6% (21 of 314) limbs.



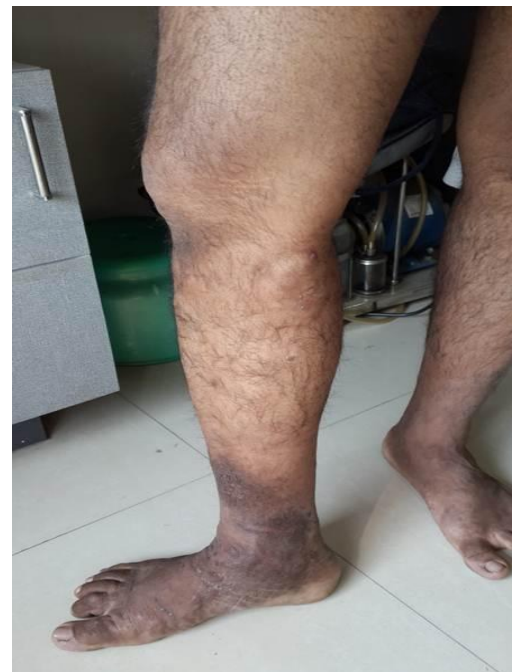a.



b.



c.



d.

Figure.(a) Varicose veins in the right lower thigh and leg prior to procedure. (b) No varicosity seen in right lower limb immediate post laser treatment. (c) Tortuous varicosities in right leg of a 40 year old male patient with skin discolouration prior to treatment (d) No varicosities seen in the right leg immediate post laser treatment.

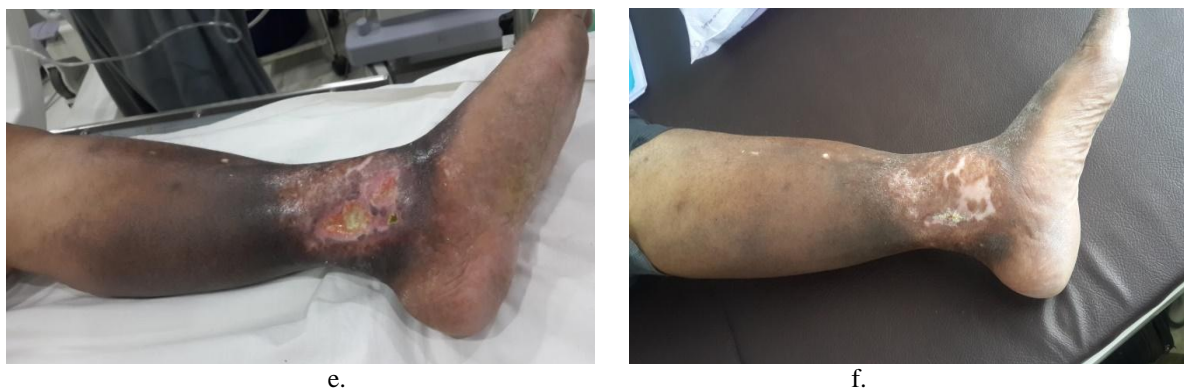


Figure.(e) Non healing venous ulcer on the left lower limb of a 63 year old male patient around the ankle with dermatosclerosis and skin blackening. (f) 6 weeks after laser treatment left lower limb showing healing of the ulcer with significantly reduced skin blackening.

Table 2. Outcomes at 1 week.

|                          |              |
|--------------------------|--------------|
| Legs                     | 314 ( 100%)  |
| Occlusion                | 314 ( 100%)  |
| Adverse Outcomes:        |              |
| Paresthesia              | 6 (1.91%)    |
| Tightness                | 245 (78.02%) |
| Bruising (ecchymoses)    | 110 (35.03%) |
| Deep Vein Thrombosis     | 2 (0.63%)    |
| Phlebitis                | 0            |
| Pulmonary Embolism       | 0            |
| Skin burns               | 0            |
| Recurrent varicose veins | 0            |

1 year follow up of patients showed a recurrence of varicose veins in 1.5% (5 of 314) limbs.

#### IV. Conclusion

Endovenous laser in treating GSV reflux has impressive results at 3 years. Foam sclerotherapy is effective in dealing with perforators and accessory venous channels. It can be repeated safely when required. Concomitant use of both modes limits the need of subsequent procedure. A limitation of this study is that we have not compared EVLA with other newer modern modalities of treatment. Also the results have been obtained using laser wavelength of 810 nm only. The popularity of endovenous laser is not only based on its safety and efficacy but also due to a high acceptance and satisfaction of patients. Large meta-analysis studies with an average follow-up up to 32 months demonstrated high success rates for endothermal procedures– 94% for EVLA and 84% for radiofrequency ablation (8). Early methods of intraluminal delivery of high-frequency alternating-current radiofrequency energy to treat GSV reflux were complicated by skin burns, saphenous nerve and peroneal nerve injury, phlebitis, and wound infection (9). Ablation of the vein by endovenous laser therapy is a newer procedure that is less invasive than surgery and has a lower complication rate with high success rate. The procedure is well tolerated by patients and produces good clinical and cosmetic results thereby improving quality of life of the patient.

#### References

- [1]. Bailey & Love's short Practice of surgery - 25th Edition; page 927 - 33
- [2]. Journal of Diagnostic And Interventional Radiology, Ankara, Turkey;2012;18(4):417-22.
- [3]. Annals of Vascular Surgery. 2013;27(7): 932-9
- [4]. Endovenous laser ablation of varicose veins. J casrdiovascurg 2005;46:395-405
- [5]. Welte. F. J et. al. J Vasc Interv Radiol 2010; 21:14–31
- [6]. Neil M. Khilnani, M.D.1 and Robert J. Min, M.D. J. Vasc Interv Radiol. 2003 Aug;14(8):991
- [7]. S. D. Goode et. al. Cardiovasc Intervent Radiol (2009) 32:988–991
- [8]. Van den Bos R, Arends L, Kockaert M, et al. Endovenous therapies of lower extremity varicosities: a meta-analysis. J Vasc Surg 2009; 49: 230–239.
- [9]. Politowski M, Zelazny M. Complications and difficulties in electrocoagulation of varices of the lower extremities. Surgery 1966; 59:932–934.