

Morphological Changes Induced By Aqueous Extract of Areca Nut (Areca Catechu) On the Oesophagus of Adult Wistar Rats

Adediji, J. A.¹, Eze, G. I.², Ehimigbai, A. O.²

¹(Centre for Training Community Health Officers, University of Benin Teaching Hospital, Benin City, Nigeria.)

²(Department of Anatomy, Faculty of Basic Medical Sciences, University of Benin, Benin City Nigeria.)

Abstract: Twenty-four (24) male and female adult Wistar rats weighing between 190 kg – 240 kg were randomly divided into four (4) groups: the Control group (A) received pelletized growers mesh and distilled water for four weeks while groups B, C and D were administered 400 mg/kg, 800 mg/kg and 1200 mg/kg of aqueous extract of areca nut respectively for four (4) weeks consecutively. The animals were sacrificed following 24 hours of fasting using chloroform anaesthesia. The oesophagus from each rat in each group were immediately harvested and processed for histological observations. In the histological assessment of the oesophagus, the aqueous extract of areca nut induced hyperplasia of the oesophageal mucosa at step-wise degrees, as the dosage increased with papillary projection of the mucosa into the sub mucosa region. The results of this study generally revealed that aqueous extract of areca nut caused morphological distortion in the oesophageal mucosa of Wistar rats.

Keywords: Areca nut, Aqueous Extract, Oesophagus, Morphological, Wistar rat.

I. Introduction

The word ‘Areca’ is derived from the word adakka or from adakeya, the Indian equivalent¹. Areca nut is believed to have originated from Sri Lanka and Malaysia. It is cultivated in South-East Asia, in India and in some regions of Central Africa². The areca palm is used as an ornamental and interior landscaping plant. Areca palm is usually been used in hotels and malls³.

The common names of Areca nut are Adike, Areca, Betel nut, Pinlang, Betel palm, Fobal, Tuuffel, Goorrecanut palm, Gouvaka, PaanSupari, Kamuku, Mak, Sopari, Tambul⁴. After adequate research, I have named Areca nut as “EKURO OYINBO” which means palm kernel of the whites, in the dialect of the Yoruba speaking part of Nigeria.

Areca nut is chewed regularly by at least 10% of the world population and it is the fourth most widely used addictive substance⁵.

It contains water 30 %, protein 5 %, fat 3 %, carbohydrate 47 %, and total alkaloids with arecoline been the major alkaloid constitute 0.2 % – 0.7 %.

The active alkaloid compounds present in areca nuts are guvacine, arecaidine, guvacoline, and arecoline. Arecoline is the principal alkaloid found in Areca catechu, while the other three alkaloid compounds are available in small quantities².

The husk fibres of areca catechu (areca nut) has been reported to be used for cleaning of teeth⁶.

Drugs that are cholinergic like areca nut produce series of side effects including excessive salivation, urinary and faecal incontinence, sweating, vomiting and diarrhoea.⁷

The lethal dose (LD50) of raw areca nut extract in healthy male and female wistar rats was found to be 2321.96 mg/kg and 2257.52 mg/kg, respectively.⁸

Areca nut also exerts a direct antimicrobial effect towards bacteria, including *Streptococcus salivarius*, *Streptococcus mutans*, and several other micro-organisms in the buccal cavity¹.

The National Institutes of Health links regular betel nut chewing to cancers of the mouth. Additionally, compounds in betel nut can encourage the growth of cervical, oral, liver, prostate, lung, and stomach cancers⁷.

Sarodeet al., 2013 hypothesized that only areca nut chewing cannot cause oral sub mucous fibrosis and oesophageal cancer⁹.

The oesophagus is a muscular tube that takes food from the pharynx to the stomach. No digestion takes place here. Peristalsis of the oesophagus propels food in one direction and ensures that food gets to the stomach even if the body is horizontal or upside down.¹⁰ Oesophagus is a muscular tube lined by a mucous membrane. It has four distinct functional layers: mucosa, muscularispropria, submucosa, and adventitia.¹¹

1.1 AIM

To investigate the morphological changes induced by aqueous extract of Areca nut (*Areca Catechu*) on the oesophagus of adult Wistar rats.

1.2 Objectives

To investigate the effects of aqueous extract of Areca nut on the cytoarchitecture of the oesophagus of adult Wistar rats.

II. Materials and Methods

II.I Materials

The materials used for this investigation included twenty four (24) adult Wistar rats weighing 190 – 240 kg. Areca nut was obtained within the Ugbowo campus of University of Benin. The pelletized growers mash was obtained from Livestock feed factory in Benin City. Distilled water was also obtained from University of Benin Enterprise. The following equipment were used during the course of this study: rotary microtome, Leica brand of automated tissue processor, refrigerator, mettler balance, embedding machine, British milling machine, chromatography jar, evaporating dish, water bath, bowl, white man paper, wax, dissecting set, needle and syringe, oral cannula, specimen (universal) bottles. The analytical grades of reagents used in this study include formal saline, ethanol, xylene, H & E stain, DPX, and chloroform.

II.II Plant Collection

Areca nut (*Areca Catechu*) used in this study were collected within the premises of University of Benin (Ugbowo Campus) and identified by Mr.Nweke Sunday who is the head of herbarium unit of the Department of Pharmacognosy of University of Benin, Benin City.

II.III Preparation of Extract

The extract was processed and prepared in the Department of Pharmacognosy, University of Benin, Benin City. The fresh matured seeds of Areca nut were collected and air-dried at room temperature (to prevent solar leaching). The husks of Areca nut was removed and discarded. The seeds of the areca nut was ground into 4.0 kg of powdered form of Areca nut using British Milling Machine. Two hundred and fifty (250) grams of powdered areca nut was dissolved in 1.5Litres of distilled water using a chromatography jar for 24 hours. The mixture of powdered Areca nut and distilled water was then filtered using filter paper. The residue obtained was discarded while the filtrate was poured into the evaporating dish. This evaporating dish containing filtrate of Areca nut was placed on a water bath at 40⁰C for three (3) days to convert the filtrate to concentrate after series of evaporation had taken place. The concentrate was further heated on the water bath till it became dry and was stored at room temperature for use.

II.IV Animal Grouping and Experimental Design

Twenty-four (24) adult Wistar rats were randomly divided into four (4) experimental groups of six (6) rats each.

The rats in the Control group A, were orally fed with pelletized growers mesh and distilled water only, for four (4) consecutive weeks. The rats in Group B were administered orally with 400 mg/kg body weight of aqueous extract of Areca nut, pelletized growers mash and distilled water daily, for four (4) consecutive weeks. The rats in Group C were orally administered with 800 mg/kg body weight of aqueous extract of Areca nut, pelletized growers mash and distilled water daily, for four (4) consecutive weeks. The rats in Group D were orally administered with 1200 mg/kg body weight of aqueous extract of Areca nut, pelletized growers mash and distilled water daily, for four (4) consecutive weeks.

The administration of aqueous extract of Areca nut was done using orogastric tube. After the fourth consecutive week of administration of aqueous extract of Areca nut, the animals were fasted for 24 hours to ensure that they were at normal metabolic rate before been sacrificed.

The animals were sacrificed after 24 hours of fasting using chloroform anaesthesia. The abdomen was excised and the oesophagus from each rat in each group were immediately harvested for tissue processing.

III. Results

The section of the oesophagus in control group (A) showed stratified keratinized squamous cell epithelium, basement membrane and sub-epithelial zone (Fig. 1.1a & 1.1b).

When compared to control, section of the oesophagus of the rats in group B which received 400 mg/kg of aqueous extract of Areca nut for four (4) weeks showed focal projection of the lower epithelial layer (papillary) into the sub-epithelial zone and mild chronic inflammatory infiltrates (Fig. 1.2a & 1.2b).

When compared to control, section of the oesophagus of the rats in group C which received 800 mg/kg of aqueous extract of Areca nut for four (4) weeks showed mild projection of the lower epithelial layer (papillary) into the sub-epithelial zone and mild chronic inflammatory infiltrates (Fig. 1.3a & 1.3b).

When compared to control, section of the oesophagus of the rats in group D which received 1200 mg/kg of aqueous extract of Areca nut for four (4) weeks showed moderate thickening of the stratified squamous epithelium (hyperplasia), with finger-like projection of the lower layers of the epithelium into the sub-epithelial zone (papillary projection). The section also showed moderate chronic inflammatory infiltrates (Fig. 1.4a & 1.4b).

IV. Figures

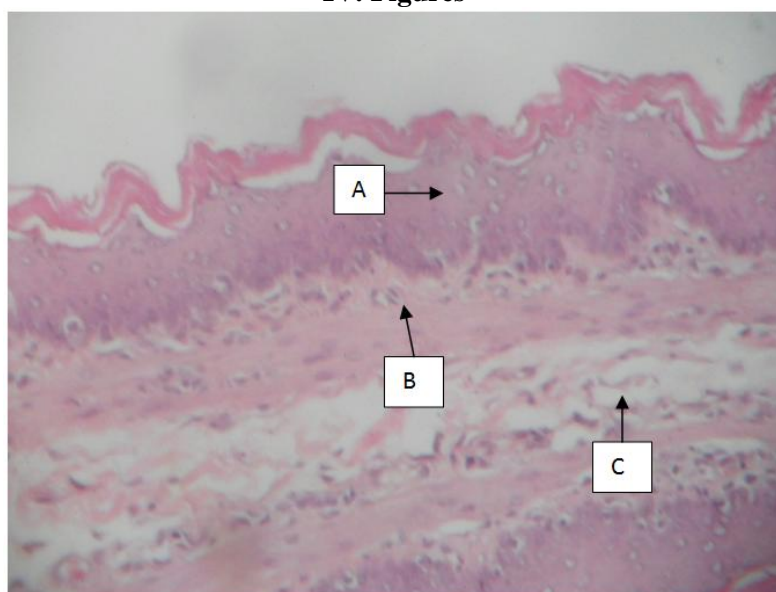


Fig. 1.1a: Lower magnification of Section of the oesophagus of Control Group (A)rat composed of Stratified Keratinized Squamous cell epithelium = A; basement membrane = B; and Sub-epithelial zone = C (H&E x 100).

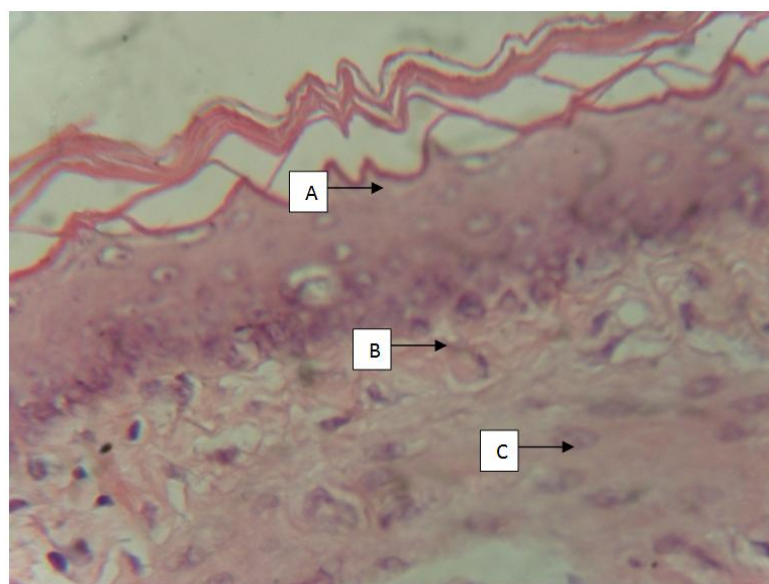


Fig.1.1b: Higher magnification of Section of the oesophagus of Control Group (A)rat composed of Stratified Keratinized Squamous cell epithelium = A; basement membrane = B; and Sub-epithelial zone = C (H&E x 400).

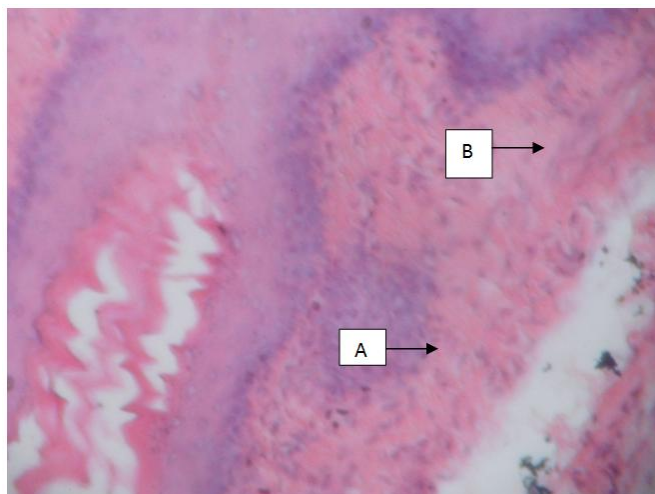


Fig.1.2a: Lower magnification of Section of the oesophagus of Group (B)rat treated with 400mg/kg Areca catechu for four weeks showing focal projection of the lower epithelial layer (papillary) into the Sub-epithelial zone= A; inducing mild chronic inflammatory infiltrates = B (H&E x 100).

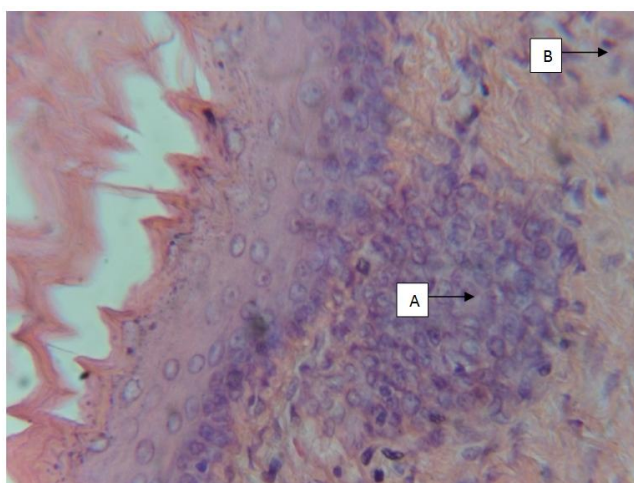


Fig.1.2b: Higher magnification of Section of the oesophagus of Group (B)rat treated with 400mg/kg Areca catechu for four weeks showing focal projection of the lower epithelial layer (papillary) into the Sub-epithelial zone = A; inducing mild chronic inflammatory infiltrates = B (H&E x 400).

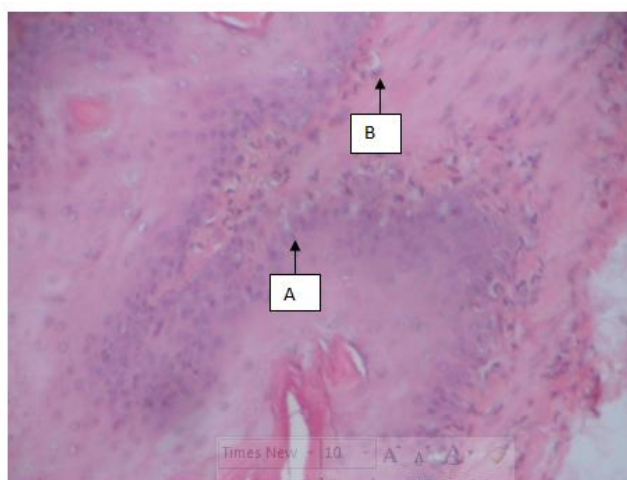


Fig.1.3a: Lower magnification of Section of the oesophagus of Group (C)rat treated with 800mg/kg Areca catechu for four weeks showing mild projection of the lower epithelial layer (papillary) into the Sub-epithelial zone = A; inducing mild chronic inflammatory infiltrates = B (H&E x 100).

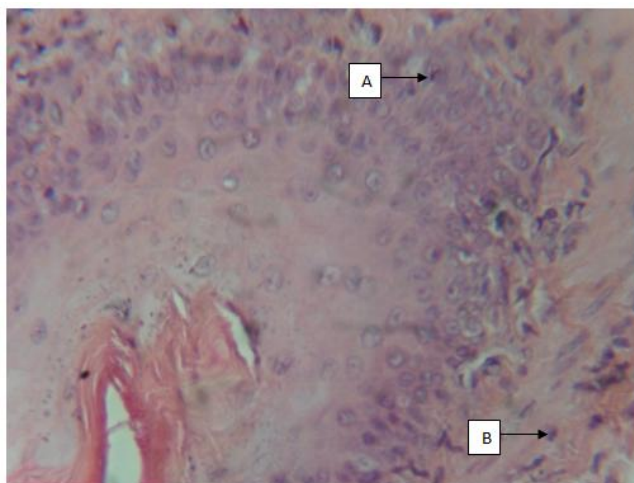


Fig. 1.3b: Higher magnification of Section of the oesophagus of Group (C)rat treated with 800mg/kg Areca catechu for four weeks showing mild projection of the lower epithelial layer (papillary) into the Sub-epithelial zone = A; inducing mild chronic inflammatory infiltrates = B (H&E x 400).

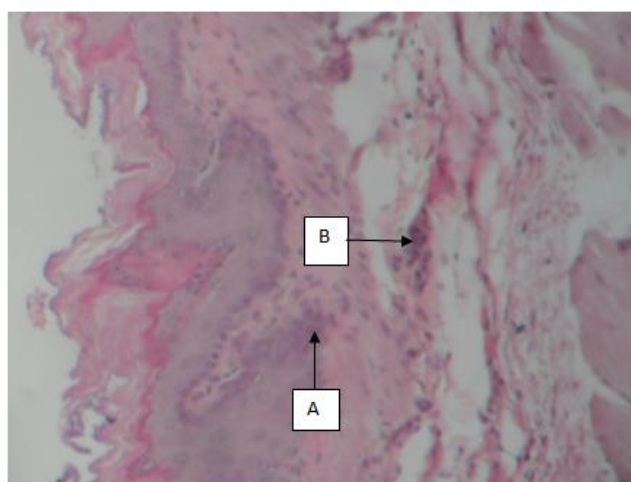


Fig. 1.4a: Lower magnification of Section of the oesophagus of Group (D)rat treated with 1200mg/kg Areca catechu for four weeks showing moderate projection of the lower epithelial layer (papillary) into the Sub-epithelial zone = A; inducing moderate chronic inflammatory infiltrates = B (H&E x 100).

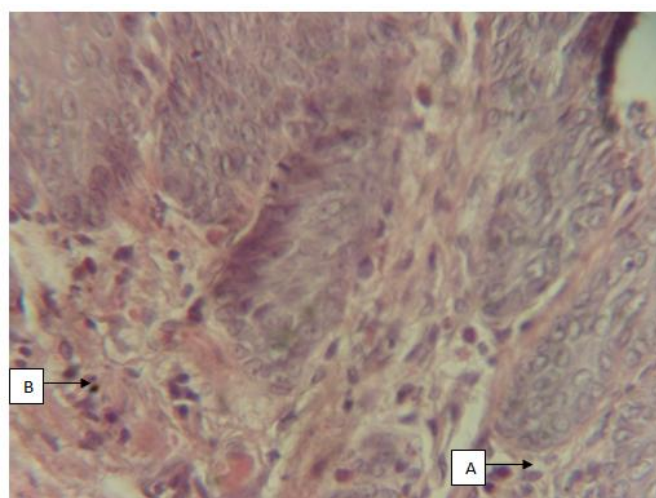


Fig. 1.4b: Higher magnification of Section of the oesophagus of Group (D)rat treated with 1200mg/kg Areca catechu for four weeks showing moderate projection of the lower epithelial layer (papillary) into the Sub-epithelial zone = A; inducing moderate chronic inflammatory infiltrates = B (H&E x 400).

V. Conclusion

Histologically, administration of graded doses (400 mg/kg, 800 mg/kg and 1200 mg/kg) of aqueous extract of Areca nut to the rats induced focal, mild, and moderate thickening of the keratinized stratified squamous epithelium (hyperplasia), with finger-like projection of the lower layers of the epithelium into the sub mucosal zone (papillary projection), with increasing severity thus provoking severe chronic inflammation compared with the control. This shows that aqueous extract of Areca nut induces morphological distortion in the oesophagus of adult Wistar rats.

References

- [1] L.Ashok,N.Deepika, G. P.Sujatha, and P. S.Shiva,Areca nut: to chew or not to chew? E-Journal of Dentistry. 1(3), 2011, 56-50.
- [2] G.A. Lord, C.K. Lim,S.Warnakulasuriya, and T.J. Peters, Chemical and analytical aspects of areca nut. Journal of Addiction Biology. 7. 2002, 99-102.
- [3] S. Warnakulasuriya, Areca nut use following migration and its consequences. Journal of Addiction Biology. 7, 2002, 127-132.
- [4] C. Ratsch,TheEncyclopedia of Psychoactive Plants: Ethnopharmacology and its Applications. Rochester, Park Street Press, 1998, 57 58.
- [5] B.J. Boucher and N. Mannan, Metabolic effects of the consumption of Areca catechu. Journal of Addiction Biology. 7, 2002, 103-110.
- [6] J. Maji, B.C. Maria,P.Vidya,V.Ipe, and S. Manjula, Antimicrobial Properties of Areca Catechu (Areca Nut) Husk Extracts against Common Oral Pathogens. International Journal of Research in Ayurveda Pharmacy 3 (1), 2012, 81-84.
- [7] R. Juniper, The Effects of Chewing Betel Nut. Published at www.livestrong.com/article/129158.2013. Assessed on 2nd of August 2014 at 6:05am.
- [8] T.S. Lohith, N.B.Shridhar, K. Jayakumar,M.L.Sathyanarayana, S.M. Dilip, andK.H.Gowda, Acute Oral Toxicity of Raw Areca Nut Extracts in Rats. Indian Journal of Animal Research. 47(5), 2013, 431-434.
- [9] S.C. Sarode, A.Mahuli, G.S. Sarode, and S. Mahuli, Why only areca nut chewing cannot cause oral sub mucous fibrosis. Journal of Medical Hypotheses. 81(1), 2013, 47-49.
- [10] C.S. Valerie, and S. Tina,Essentials of anatomy and physiology. 5th edition. F. A. Davis Company, 1915 Arch Street, Philadelphia, PA 19103. 2007, Page 373.
- [11] Y. Barbara, S.L. James, S. Alan, and W.H. John,Wheater's Functional Histology. A text and colour atlas. 5th edition. 2010 pg. 267, 288 & 289.