

Efficacy of Arthrocentesis in Internal Derangement of Temporomandibular Joint

Dr. Syed Wakeel, Dr. Ajaz Shah, Dr. Shahid Hassan, Dr. Irshad Ahmad,
Dr. Shahijahan, Dr. Shajah, Dr. Israr Khaliq
Department of Oral and Maxillofacial Surgery, Govt. Dental College & Hospital, Srinagar

Abstract:

Objective: The study aims to evaluate the efficacy of arthrocentesis in the treatment of internal derangement of the temporomandibular joint (TMJ).

Study Design: Fifty patients with TMJ internal derangement underwent arthrocentesis using ringer lactate. Pain using visual analog scale, maximum mouth opening, joint noises and mandible deviation were documented pre-operatively and post-operatively. Patients were followed for 6 months. Statistical analysis of pain and maximum mouth opening was done by calculating P value (ANOVA).

Results: The mean pre-operative pain was 6.5 ± 1.52 and post-operatively at 6th month was 0.46 ± 1.14 with an average decrease of 6.0 ($P = 0.000$). The mean maximal mouth opening pre-operatively was 26.14 ± 4.12 mm and post-operatively 38.9 ± 3.23 mm at 6 month. The mean increase in the mouth opening was 12.7 mm ($P = 0.000$).

Conclusion: Arthrocentesis is an intermediate procedure between non-surgical and surgical treatment of TMJ internal derangement. It is minimally invasive procedure with less risks and complications and significant benefits in patients with TMJ internal derangement.

Keywords: Temporomandibular joint, Internal derangement, Arthrocentesis

I. Introduction

Temporomandibular disorders (TMD) represent a wide range of functional changes and pathological conditions affecting both the jaw joint itself and the chewing muscles and, ultimately, all the other components of the oromaxillofacial system. In recent years, TMD have become an increasingly frequent cause of seeking medical assistance. Characteristic symptoms of temporomandibular joint disorders are pain, changes in the mobility of the lower jaw (in the sense of restricted opening of the mouth – hypomobility, or by contrast, hypermobility), and sound phenomena (clicking, grinding).

Internal derangement of the temporomandibular joint (TMJ) is characterized by displacement of the intra-articular disc, resulting in clicking and popping sounds. However, the displacement of the articular disc does not always cause a mechanical obstruction. These conditions may be painless or they may be associated with pain, especially during function. The most common causes are trauma, which results in an immediate displacement of the disc, or chronic parafunction, which results in degenerative changes in the articular surfaces, increased friction, and gradual disc displacement.

TMJ internal derangement has always presented as therapeutic challenge to the maxillofacial surgeons. Up to 25% of the entire population has internal derangement of TMJ and usually they are treated with nonsurgical methods such as medications, physiotherapy and occlusal splints in the initial period [1]. When these methods are unsuccessful, they are often managed by surgical methods. The mainstay of surgical treatment is based on changing the morphology or position of the disc, or removal of the disc with or without replacement. There are variable reports of success with the open surgical methodologies and are associated with surgical risks and potential long term sequelae [2].

New insights into the joint pathology of internal derangement were provided by the observations made during TMJ arthroscopic lysis and lavage and outcomes after such treatment. The physical action of lysis and lavage in the superior joint space, rather than disc repositioning, is believed to be responsible for the success of arthroscopic surgery [3, 4]. This has led to the use of TMJ arthrocentesis as a relatively less invasive alternative to reduce the inflammation in the superior joint space and restore normal range of motion [3]. The study aims to discuss the role of arthrocentesis in the treatment of internal derangement of the TMJ and present clinical data relating to the efficacy of arthrocentesis.

II. Material And Methods

This prospective clinical study on fifty patients with internal derangement of TMJ . Criteria for selection of the patients was based on history and clinical findings characteristic of internal derangement⁵. All these patients were initially treated with non-surgical methods and failed to respond to these conservative treatments. A screening TMJ view radiograph was taken in all of them to rule out gross degenerative joint diseases. The patients with degenerative joint diseases such as osteoarthritis, rheumatoid arthritis, gout etc. causing temporomandibular joint dysfunction and patients with previous surgical intervention in TMJ were excluded from the study. A total of 50 patients with TMJ internal derangement with failed conservative management, of whom 20 had nonreducing disc displacement and 16 had reducing disc displacement and 14 had reducing disc displacement with intermittent locking which were subjected to TMJ arthrocentesis.

Under aseptic precautions, arthrocentesis was performed in the superior joint space. With patient seated at 45° angle, the points of needle insertion were marked on the skin according to the method suggested by Mc. Cain. A line(holomlund hellsing) was drawn from the middle of the tragus to the outer canthus. Entry points were marked along this canthotragal line(fig 1). The first point corresponding to glenoid fossa was marked 10 mm from the midtragus and 2 mm below the line and second point corresponding to articular eminence was marked 10 mm from the first point and 10 mm below the line. 2 ml of 2% Lignocaine was injected to anesthetise the articular branch of auriculotemporal nerve. Patients were asked to open the mouth wide and mandible was held in the protruded position. A 19 gauge needle was then introduced at the first point and 2 ml of Ringer lactate was injected through this needle to distend the joint space. Another 19 gauge needle was then inserted at the second point to establish a free flow of the solution through the joint space(fig 2). A syringe filled with Ringer lactate was injected under pressure into the superior joint space through the first needle and second needle provided the outflow for the Ringer lactate. A total of 50–100 ml solution was used to lavage the superior joint space and the needles were removed. Patient’s lower jaw was gently manipulated in the vertical, protrusive and lateral excursions to free up the disc. Postoperatively , NSAIDS and muscle relaxants were advised for 1week..

The pre-operative and post-operative clinical assessment was done by a single clinician for signs and symptoms of TMJ disorders which included pain, mouth opening, joint noises and jaw deviation. Pain was assessed using a visual analog scale (0–10). Mouth opening was measured as the maximum interincisal distance in millimeters using a scale. The patients were assessed for all the parameters pre-operatively, and post-operatively on day 1, 1 week, 1 month ,3rd month and then at 6th months a. All results were calculated using the mean value and standard deviation for each of the parameters considered and checked for statistical significance .

III. Results

50 patients with age range of 18-60 years ,the mean age of patients 28.96 ± 11.034 years and 36 were females and 14 male patients.

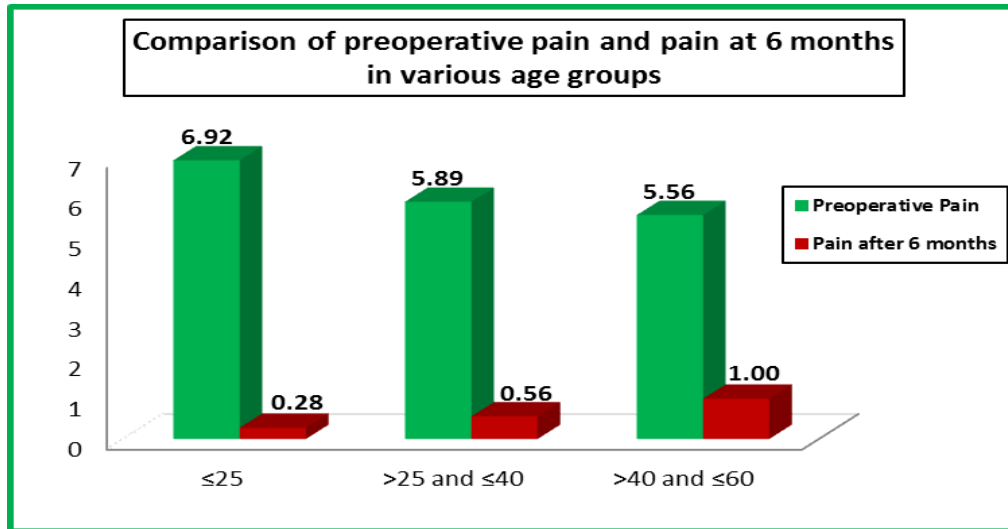
Mean preoperative pain of patients on VAS scale were 6.5±1.56 ,There was statistically significant improvement at every follow up. At 6th month follow up after arthrocentesis mean pain score of patients on VAS scale were .46±1.147 with mean difference of 6.03 from preoperative VAS score(table1).There was significant improvement in pain in both males and females and in all age groups.In every age group there was significant improvement in pain. In age group ≤25 shows preoperative pain score was highest among all groups and postoperative pain was lowest among all age groups (table 2)

Time Interval	Mean	SD	P-value (ANOVA)	Comparison	Mean difference	P-value
Preop (1)	6.49	1.560	<0.001 (SSD)	-	-	-
1 Week (2)	2.52	0.953		1 vs 2	3.97	<0.001 (SSD)
1 Month (3)	1.44	1.053		1 vs 3	5.05	<0.001 (SSD)
3 Months (4)	0.64	1.083		1 vs 4	5.85	<0.001 (SSD)
6 Months (5)	0.46	1.147		1 vs 5	6.03	<0.001 (SSD)

SSD: Statistically significant difference

Table 2: Comparison of preoperative pain and pain at 6 months in various age groups

Age group	Preoperative Pain		Pain after 6 months		P-value
	Mean	SD	Mean	SD	
≤25	6.92	1.283	0.28	1.114	<0.001 (SSD)
>25 and ≤40	5.89	1.833	0.56	1.130	<0.001 (SSD)
>40 and ≤60	5.56	1.74	1.00	1.225	<0.001 (SSD)



Mean of preoperative maximum vertical opening is 26.14±4.969mm. 23 patients have MVO <25mm and 27 patients have >25mm. There was statistically significant improvement in maximum vertical opening on every follow up. At 6th month follow up after arthrocentesis mean maximum mouth opening of patients were 38.9±3.3mm with mean difference of 12.78mm from preoperative MVO (table 3)

Table 3: Comparison of MVO at different time intervals with preoperative MVO

Time Interval	Mean	SD	P-value (ANOVA)	Comparison	Mean difference	P-value
Preop (1)	26.14	4.969	<0.001 (SSD)	-	-	-
1 Week (2)	35.32	3.235		1 vs 2	-9.18	<0.001 (SSD)
1 Month (3)	36.46	3.085		1 vs 3	-10.32	<0.001 (SSD)
3 Months (4)	37.68	3.377		1 vs 4	-11.54	<0.001 (SSD)
6 Months (5)	38.92	3.392		1 vs 5	-12.78	<0.001

Out of 50 patients only 20 have deviation of mouth opening and among these only 25% showed improvement in deviation. Out of 50 patients only 20 have joint noise and among those only 23.3% showed improvement.

There were no serious postoperative complications. Immediate postoperative swelling was encountered in majority of patients. But the swelling subsided overnight in all the cases. Transit temporal branch palsy resulting in inability to close upper eyelid also occur in some cases but it is self-limiting (table 4)

Table 4 complication associated with arthrocentesis

Complication	No. of cases	percentage
Preauricular swelling	27	54%
Inability to elevate upper eyelid	12	24%
Bleeding In preauricular are	6	12%
Auditory complication	0	0
Extradural haematoma	0	0

IV. Discussion

There is clinical evidence supporting the existence of disc displacement in TMJ internal derangement. However, current concept suggests that a change in the position of the disc is not a primary factor in TMJ pain and dysfunction but alterations in joint pressure (negative intra-articular pressure), a variety of biochemical substances, constituents of the synovial fluid (and thereby failure of lubrication) may lead to clicking and derangement of the TMJ^{3,6,7}. The presence of inflammatory cells and inflammatory mediators, including

arachidonic acid metabolites and cytokines were demonstrated in symptomatic TMJs^{6,7} Lavage of the upper joint space reduces pain by removing inflammatory mediators from the joint, increasing mandibular mobility by removing intra-articular adhesions, eliminating the negative pressure within the joint, recovering disc and fossa space and improving disc mobility, which reduces the mechanical obstruction caused by the anterior position of disc.⁸⁻¹¹

Arthrocentesis has developed as a natural consequence of the success of arthroscopic lavage and lysis for the treatment of internal derangements⁴. Nitzan et al. first described arthrocentesis as the simplest form of surgery in the TMJ, aiming to release the articular disc and to remove adhesions between the disc surface and the mandibular fossa by means of hydraulic pressure from irrigation of the upper chamber of the TMJ^{8,10,12}

Studies done to know whether the effect of arthrocentesis on internal derangements are merely palliative or it provides long term relief of the associated symptoms have shown that arthrocentesis can produce long term relief of pain and dysfunction in patients with internal derangements of the TMJ^{2,13} Arthrocentesis is 91% effective in treating patients with anterior disc displacement without reduction^{9,14,15}

Mean pre-operative pain score of patients on VAS scale is 6.5 ± 1.56 and maximum pre operative vertical opening is 26.14 (Mean \pm SD= 26.14 ± 4.969 mm) There was statistically significant improvement at every follow up. At 6th month follow up after arthrocentesis mean pain score of patients on VAS scale were $.46 \pm 1.147$ with mean difference of 6.03 from preoperative follow up and maximum MVO were 38.9 ± 3.3 mm with mean difference of 12.78mm from preoperative opening.²¹

In this study 84% showed significant reduction in pain with arthrocentesis. The pain reduction is attributed to the high pressure irrigation which washes away inflammatory mediators and providing pain relief. Failure in pain relief in one case may be due to pain originating from causes other than internal derangement.

Arthrocentesis under sufficient pressure can also remove adhesions, widen the joint spaces and improve mouth opening^{3,16,17} In patients who presented with limited mouth opening, significant improvement was seen in the immediate post-operative period and with reduction in pain, mouth opening further increased from third to sixth months. The mean increase in the mouth opening was 12.78 mm. Marginal improvement was observed with jaw deviation and clicking. Assessment of these parameters will require a larger sample and longer followup.

In cases where TMJ arthrocentesis fails to achieve the desired outcome, a number of factors should be considered. Appropriate case selection is important, as this technique is not effective in certain conditions such as with bony changes, fibroankylosis and perforation of the disc^{12,16} Even when the indications are apparent other associated factors such as muscle spasm must be brought under control prior to arthrocentesis. Cases where arthroscopy or open joint surgery is indicated but the clinician is uncertain of the diagnosis, arthrocentesis may be used as a simple interim measure that can confirm the need for more invasive procedure^{10,18}

A major disadvantage of arthrocentesis is the failure to directly observe intra-articular pathology, the ability to biopsy pathological tissue and difficulty in treating more mature adhesions¹⁹. Sweeping and other non-operative arthroscopic manoeuvres which can be performed with arthroscopic lysis and lavage are not possible with arthrocentesis. Transient facial paresis due to the local anaesthetic or swelling of the neighboring tissues caused by perfusion of solution may occur during arthrocentesis²⁰ 24% patients in this study complained of transient altered motor function on the side of arthrocentesis which resolved of its own.²¹

V. Conclusion

Arthrocentesis is a simple and intermediate procedure between medical and open surgical treatment. It is a minimally invasive procedure with less intraoperative and postoperative complications. Lavage of superior joint space with ring lactate results in insignificant reduction in pain and improvement in mouth opening. These observations make arthrocentesis a proposed line of treatment for patients with TMJ internal derangements before advocating aggressive joint surgery.

References

- [1]. Barkin S, Weinberg S. Internal derangements of the TMJ: the role of arthroscopic surgery and arthrocentesis. *J Can Dent Assoc.* 2000;69:199–203.
- [2]. William A, Carvagal Daniel M, Laskin Long term evaluation of arthrocentesis for the treatment of internal derangements of the temporomandibular joint. *J Oral Maxillofac Surg.* 2000;58:852–855.
- [3]. Franklin Dolwick M. Intra articular disc displacement part I: its questionable role in temporomandibular joint pathology. *J Oral Maxillofac Surg.* 1995;53:1069–1072.
- [4]. David Frost E, Barry Kendall D. “The use of arthrocentesis for treatment of temporomandibular joint disorders” *J Oral Maxillofac Surg.* 1999;57:583–587
- [5]. Truelove EL, Sommers EE, LeResche L, Dworkin SF, Von Korff M. Clinical diagnostic criteria for TMD. New classification permits multiple diagnosis. *J Am Dent Assoc* 1992;123:47-54
- [6]. Alpaslan C, et al. Effect of arthrocentesis and sodium hyaluronate injection on nitrite, nitrate, and thiobarbiturate acid- reactive substance levels in the synovial fluid. *Oral Surg Oral Med Oral Pathol.* 2000;89:686–690.
- [7]. Nishimura M, Segami N, Kaneyama K, Sato J, Fujimura K. Comparison of cytokinin level in synovial fluid between successful and unsuccessful cases in arthrocentesis of temporomandibular joint. *J Oral Maxillofac Surg.* 2004;62(3):284–287

- [8]. Dorrit W, Nitzan, et al. Temporomandibular joint arthrocentesis simplified treatment for severe, limited mouth opening. *J Oral Maxillofac Surg.* 1991;49:1163–1167.
- [9]. Kaneyama K, Segami N, Nishimura M, Sato J, Fujimura K, Yoshimura H. The ideal volume for removing bradykinin, interleukin-6 and protein from the temporomandibular joint by Arthrocentesis. *J Oral Maxillofac Surg.* 2004;62(6):657–661.
- [10]. Moses J, et al. The effect of arthroscopic surgical lysis and lavage of the superior joint space on temporomandibular joint disc position and mobility. *J Maxillofac Surg.* 1989;47:674–678.
- [11]. Dimitroulis G, Dolwick MF, Martinez A. TMJ arthrocentesis and lavage for the treatment of closed lock. *Br J Oral Maxillofac Surg.* 1995;33:23–27.
- [12]. Kirk L, Fridrich, et al. Prospective comparison of arthroscopy and arthrocentesis for temporomandibular joint disorders. *J Oral Maxillofac Surg.* 1996;54:816–820.
- [13]. Alpaslan C, Dolowick MF, Heft MW. "Five year study of retrospective evaluation of temporomandibular joint arthrocentesis" *Int J Oral Maxillofac Surg.* 2003;32:263–267.
- [14]. Dorrit W, Nitzan The use of arthrocentesis or the treatment of osteoarthritic temporomandibular joint. *J.Oral Maxillo Surg.* 2001;59:1154–1159.
- [15]. Emshoff R. "Clinical factors affecting the outcome of arthrocentesis and hydraulic distention of temporomandibular joint" *oral surgery, oral medicine, oral pathology, oral radiology. Endodontics.*2005;100(4):409–414
- [16]. Yura S, et al. Can arthrocentesis release intracapsular adhesions? Arthroscopic findings before and after irrigation under sufficient hydraulic pressure. *J Oral Maxillofac Surg.* 2003;61:1253–1256.
- [17]. Yura S, Totsuka Y. Relationship between effectiveness of arthrocentesis under sufficient pressure and condition of temporomandibular joint. *J Oral Maxillofac Surg.* 2005;63(2):225–228.
- [18]. Howard Israel A, et al. The relationship between temporomandibular joint synovitis and adhesions: pathologic mechanisms and clinical implications for surgical management. *J Oral Maxillofac Surg.* 2006;64:1064–1074.
- [19]. Dorrit W, Nitzan "Arthrocentesis–incentives journal for using this minimally invasive approach for temporomandibular disorders" *Oral Maxillofac Surg Clin North Am.* 2006;18:311–328.
- [20]. Gokhan H, Alpaslan C, Alpaslan Efficacy of temporomandibular joint arthrocentesis with and without injection of sodium hyaluronate in treatment of internal derangements. *J Maxillofac Oral Surg.*2001;59:613–618
- [21]. Arati S. Neeli, Meenaxi Umarani, S. M. Kotrashetti, and Shridhar Balig:Arthrocentesis for the treatment of internal derangement of the temporomandibular joint. *J Maxillofac Oral Surg.* 2010;9(4):350-4.

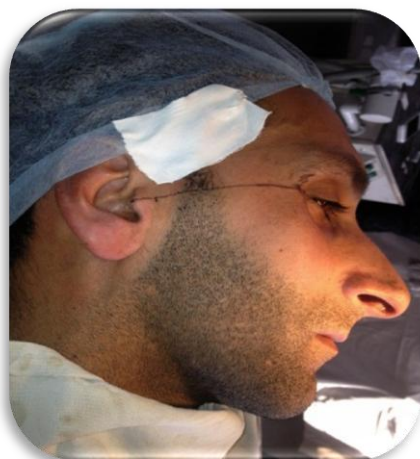

Fig 1: Canthotragal Line

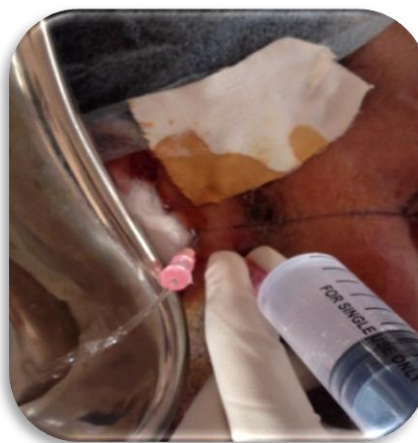

Fig 2: Lavage