

## Piezoelectric Osteotomy: A New Technique for Impacted Third Molar Surgery

<sup>1</sup>Dr. Tasveer Fatima, <sup>2</sup>Dr. Hemant Gupta, <sup>3</sup>Dr. Deepak Kumar

<sup>1,2,3</sup>Department of Oral and Maxillofacial Surgery, Babu Banarsi Das College of Dental Sciences, Babu Banarasi Das University, Lucknow, India

---

### **Abstract:**

**Introduction:** Removal of impacted wisdom teeth is a commonly performed procedure in oral and maxillofacial surgery, but there is a considerable debate among the surgeons, regarding the technique used for osteotomy

**Objective:** To Study the efficacy of piezoelectric device in impacted mandibular third molar surgery.

**Material and methods:** Special designed performa was used to collect the data, conducted in Department of Oral and Maxillofacial Surgery, Babu Banarsi Das College of Dental Sciences, Babu Banarasi Das University, Lucknow

**Results:** The present study found that, the Age of patients ranged from 18-35 years. In both the groups, majority of patients were aged 21-30 years 66% in group A and 62% in group B. There were 15 (30%) females in Group A and 18 (36%) females in Group B. All the patients presented with pain. In Group B, 6% patients each also had carious teeth and complained of food lodgement. Food lodgement was also reported by 2% patient of Group A. Maximum number of cases in both the groups were categorized as moderately difficult. There were 32% cases in Group A and 34% in Group B who were categorized as very difficult. Maximum pain was reported on day 1 after procedure in both the groups which gradually diminished to reach the score 0 by day 30. None of the patients reported of pain at one month and three month. Tragus to corner of mouth (Mc) measurements in Group B were significantly higher as compared to that in Group A from postoperative day 1 till day 7. From day 1 till day 7 post-operative intervals, mouth opening in Group A was significantly higher as compared to that in Group B.

**Conclusion:** Comparing the overall outcome in both our study groups, we observed significantly less pain, trismus and facial swelling with a better patient's perception of quality of life after third molar extraction using the piezotome.

**Key Words:** Third Molar surgery, Piezotome, Distoangular, Horizontal, Post Operative

---

### I. Introduction

The surgical removal of impacted mandibular third molars produces a significant degree of trauma to the soft tissues and bony structures of the oral cavity, potentially resulting in a significant inflammatory reaction. The latter produces the usual postoperative signs and symptoms of pain, oedema, and limited mouth opening due to muscle spasm<sup>1,2</sup>.

Ultrasound osteotomy is a new surgical technique used in oral and maxillofacial surgery to section hard tissue without damaging adjacent soft tissue. Piezosurgery was developed by Italian oral surgeon Tomaso Vercellotti in 1988 to overcome the limits of traditional instrumentation in oral bone surgery by modifying and improving conventional ultrasound technology<sup>3</sup>

Removal of impacted wisdom teeth is a commonly performed procedure in oral and maxillofacial surgery, but there is a considerable debate among the surgeons, regarding the technique used for osteotomy. For this generally requires certain degree of bone removal to facilitate delivery of tooth from its position. Various bone cutting tools, both rotatory and hand cutting have been used extensively to accomplish the same. Piezosurgery is a new and revolutionary osteotomy technique utilizing the microvibration of scalpels at ultrasonic frequency<sup>4,5</sup>.

The piezoelectric effect was discovered in 1880 by Jacques and Pierre Curie<sup>6</sup>. This is the phenomenon whereby an electric potential develops across certain crystalline materials when they are compressed; and these materials become deformed in an electric field. If the polarity of the applied field alternates, the crystal transduces this alternation into an oscillation of its surface, and this movement is transmitted to adjacent matter. The vibrations thus obtained are amplified and transferred on to the insert of a drill<sup>4</sup>.

### II. Aims And Objective:

- To Study the efficacy of piezoelectric device in impacted mandibular third molar surgery.

### **III. Material and Methods:**

I. Necessary approval from the Institutional Ethics Committee was obtained before initiating the study.

#### **II. Study site**

Department of Oral and Maxillofacial surgery, Babu Banarasi Das College of Dental Sciences Lucknow

#### **III. Study design**

Prospective Observational study

IV. **Sample size:** 50 Sample

#### **V. Patient selection**

##### **• Inclusion criteria:**

- Patients of impacted third molar teeth between 18-35 years of age having at least two previous episodes of pericoronitis .
- Patients of impacted mandibular third molar having horizontal and distoangular impactions.
- Patients having moderate and very difficult Pederson difficulty index mandibular molars.

##### **• Exclusion criteria**

- Acute infection in relation to third molar,
- Periapical pathology,
- Severe periodontal disease,
- Uncontrolled systemic disease,
- Debilitating disease,
- Patients having minimum difficult Pederson difficulty index mandibular molars.

#### **VI. Study Methods**

Out of the 50 molars, osteotomy was done by Piezosurgery unit (group A) in 25 cases and by using rotary instruments (group B) in remaining 25 cases. . All patients meeting the inclusion criteria and who gave informed consent to participate were enrolled for the study. After recording a detailed medical and dental history, orthopantomogram (OPG) and intra-oral peri-apical radiographs of impacted teeth were done. Assessment by intraoral periapical and orthopantomogram (OPG) radiography included WAR line assessment and Pederson difficulty index calculations.

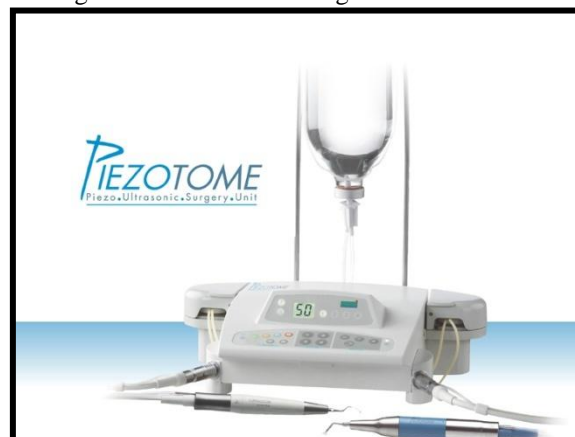#### **The removal of an impacted mandibular third molar using piezotome:-**

A Standard Ward's incision or Modified Ward's incision was given to expose the impacted tooth. Following incision Osteotomy for third molar removal was done with Piezotome in both the groups.

An ultra-sharp robust saw tips, intended for in-depth cutting of cortical bone were used. The vibration frequency was maintained between 28 to 36 KHz and microvibration amplitude between 30 and 60  $\mu\text{m}/\text{sec}$  and peristaltic pump flow rate 5 to 80 ml/min.  $\pm 10\%$  depending on the mode used to create a osteotomy lines along the buccal side and the distal surface of tooth with the help of back and forth movement.

With the help of piezotome Both mesial and distal osteotomy lines were joined with the third horizontal osteotomy line in order to remove the collar of bone on the buccal aspect of third molar. Sectioning of tooth if required was done using rotary handpiece in cases where the roots had conflicting lines of withdrawal or third molar crown locking existed (in both group A and B). After obtaining adequate haemostasis, the wound was closed without tension, with 3-0 black silk sutures.

Fig Shows: Schematic Diagram of Piezotome



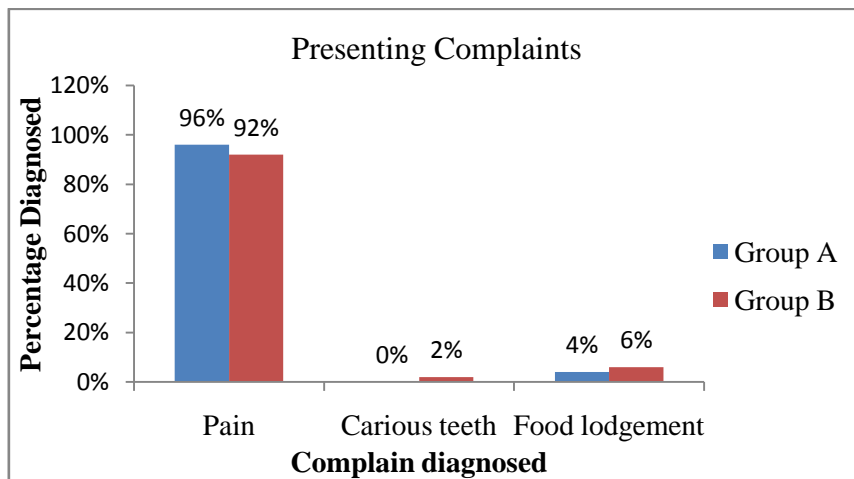
**IV. Results:**

The present study was carried out at Department of Oral and Maxillofacial Surgery, Babu Banarsi Das College of Dental Sciences, Babu Banarasi Das University, Lucknow with an aim to evaluate and compare the Piezoelectric impacted third molar surgery. For this purpose a total of 50 patients were enrolled in the study and were randomly allocated to one of the following two groups Out of 50 patients enrolled in the study who underwent third molar extraction by Piezosurgery, the 50% were enrolled for Distoangular group (Group A) while the remaining 50% taken for Horizontal group.

**Table 1:** Demographic Of study

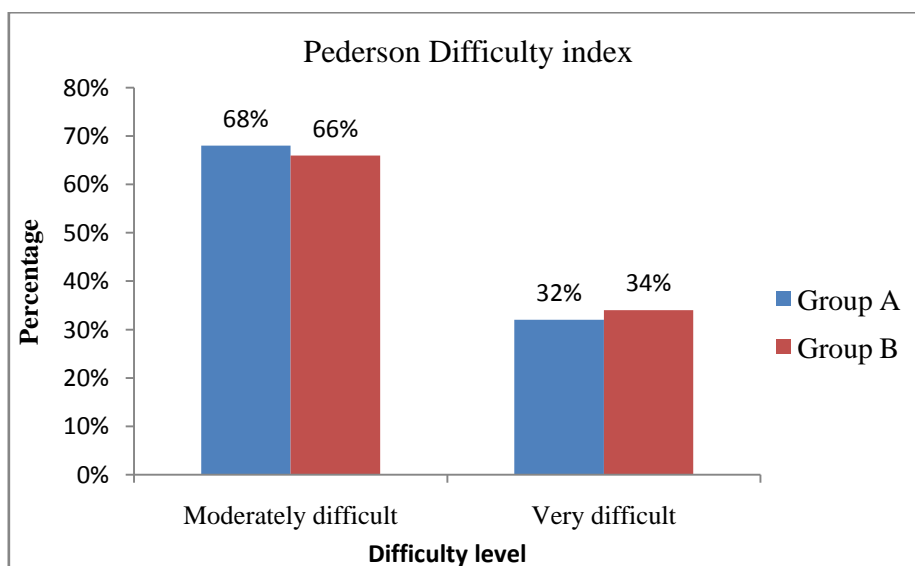
SN	Parameter	Results
1	Total Sample	50
2	Distoangular Group (A)	(25)50%
3	Horizontal group (B)	(25)50%

The present study found that, the Age of patients ranged from 18-35 years. In both the groups, majority of patients were aged 21-30 years 66% in group A and 62% in group B. In Group A minimum number of patients were aged  $\leq 20$  years (14%) whereas in Group B minimum number of patients were aged 31-35 years (12%). Mean age of patients in Group A was 25.7 Majority of patients irrespective of their group were males. There were 15 (30%) females in Group A and 18 (36%) females in Group B.



**Fig 1:** Distribution of patients on the basis of Presenting Complaints

All the patients presented with pain. In Group B, 6% patients each also had carious teeth and complained of food lodgement. Food lodgement was also reported by 2% patient of Group A.



**Fig 2:** Distribution of patients in two groups according to difficulty level

Maximum number of cases in both the groups were categorized as moderately difficult. There were 32% cases in Group A and 34% in Group B who were categorized as very difficult and a total of 68% in Group A and 66% in Group B were characterized as moderately difficult.

**Table 2: postoperative pain at different follow up intervals in two groups**

SN	Follow up interval	Group A (n=25)	Group B (n=25)
1	Day 1	2.89±1.29	5.92±1.59
2.	Day 3	2.86±1.19	4.21±1.12
3.	Day 5	1.28±0.99	3.84±1.48
4.	Day 7	0.08±0.44	1.80±1.14
5.	Day 15	0.02±0.14	0.44±0.73
6.	One month	0.00±0.00	0.00±0.00
7.	Three month	0.00±0.00	0.00±0.00

Maximum pain was reported on day 1 after procedure in both the groups which gradually diminished to reach the score 0 by day 30. None of the patients reported of pain at one month and three month.

**Table 3: postoperative swelling(Tragus to corner of mouth measurements) at different follow up intervals in two groups**

SN	Follow up interval	Group A (n=25)	Group B (n=25)
1	Day 1	2.89±1.29	5.92±1.59
2.	Day 3	2.86±1.19	4.21±1.12
3.	Day 5	1.28±0.99	3.84±1.48
4.	Day 7	0.08±0.44	1.80±1.14
5.	Day 15	0.02±0.14	0.44±0.73
6.	One month	0.00±0.00	0.00±0.00
7.	Three month	0.00±0.00	0.00±0.00

Tragus to corner of mouth distance (Mc) measurements in Group B were significantly higher as compared to that in Group A ( $p < 0.05$ ) from postoperative day 1 till day 7. Maximum mean value was observed on day 1.

**Table 4: Mouth opening (mm) at different follow up intervals in two groups**

SN	Follow up interval	Group A (n=25)	Group B (n=25)
1	Preoperative	4.25±0.51	4.41±0.43
2.	Day 1	3.73±0.54	2.36±0.54
3.	Day 3	3.88±0.47	3.18±0.44
4.	Day 5	4.09±0.50	3.67±0.43
5.	Day 7	4.21±0.48	4.02±0.45
6.	Day 15	4.28±0.51	4.32±0.47
7.	One month	4.29±0.51	4.47±0.40
	Three month	4.27±0.50	4.46±0.40

From day 1 till day 7 post-operative intervals, mouth opening in Group A was significantly higher as compared to that in Group B ( $p < 0.05$ ).

## V. Discussion

The present study was undertaken to clinically assess the effectiveness of piezoelectric device during the surgical removal of impacted mandibular third molar (distoangular vs horizontal) in terms of postoperative sequelae.

In present study, the age of patients ranged from 18-35 years with mean age being 24 and 25 years in group A and Group B respectively. The reported median age of eruption of mandibular third molars ranges from 18.9 to 19.7 years among females and 18.0 to 22.5 years among males (Olze *et al.*, 2010)<sup>7</sup>. In a study by Goyal *et al.* (2012)<sup>8</sup>, the age of patients presenting with impacted mandibular third molar has been reported to be ranging between 22 to 36 years with a mean age of 29 years. However, Tsai *et al.* (2012)<sup>9</sup> reported the age of their patients to be between 18 to 28 years with a mean age of 21.5 years. These findings suggest that impacted mandibular third molar cases might present clinically in late adolescence to early maturity states.

In present study, both Group A and B managed patients had higher number of males (70% and 64% respectively) as compared to females (30% and 36% respectively). The male to female ratio of present study was 2.03:1 which was in accordance with study by Goyal *et al.* (2012)<sup>8</sup> and Patil *et al.* (2013)<sup>10</sup> who reported it to be 1.5:1 and 1.8:1 respectively. However, it is difficult to say that these figures are indicators of any gender predilection in prevalence of impacted mandibular third molar as other studies indicate an equal distribution in both the genders. A possible reason for this could be the social set-up of the society where female tends to visit hospital less as compared to males for initial problems.

In present study showed equal Distribution of type of impacted mandibular third molars as horizontal and distoangular whereas according to Morris (1971)<sup>11</sup> mesioangular was commonest and distoangular was more common than horizontal. In present study majority of cases in both the groups B patients 60% were having moderately difficult where as 40% were having very difficult Pederson difficulty index while in group A( distoangular) all the patients were having very difficult difficulty index.

The present study also evaluates the, Maximum pain was reported on day 1 after procedure in both the groups which gradually diminished to reach the score 0 by day 30. None of the patients reported of pain at one month and three month. Postoperative swelling from Tragus to corner of mouth (Mc) measurements in Group B were significantly higher as compared to that in Group A ( $p < 0.05$ ) from postoperative day 1 till day 7.

The piezotome delivers an extremely micrometric cut involving minimum surface area; this may represent one of the factors that contribute to the positive results obtained. Also the management of flap through careful tissue manipulation might explain our findings for pain, swelling and trismus. The main advantage of piezosurgery is its selective cut that recognizes tissue hardness and works only on the mineralized structures, therefore causing no soft tissue damage (mucous membrane, nerves & vessels etc.)

## **VI. Conclusion:**

Comparing the overall outcome in both our study groups, we observed significantly less pain, trismus and facial swelling with a better patient's perception of quality of life after third molar extraction using the piezotome. In spite of increased duration of surgery and cost of equipment, the final outcome suggests piezosurgery is a valuable alternative method for third molar extraction.

## **References:**

- [1]. Grossi GB, Maiorana C, Garramone RA, et al. Assessing postoperative discomfort after third molar surgery: A prospective study. *J Oral Maxillofac Surg.* 2007; 65:901
- [2]. Baqain ZH, Karay AA, Sawair F, et al: Frequency estimates and risk factors for postoperative morbidity after third molar removal: A prospective cohort study. *J Oral Maxillofac Surg.* 2008; 66: 2276
- [3]. Beziat JL, Bera JC, Lavandier B, Gleizal A. Ultrasonic osteotomy as a new technique in craniomaxillofacial surgery. *Int J Oral Maxillofac Surg.* 2007 Jun;36(6):493-500.
- [4]. Sivoilella S, Berengo M, Scarin M, Mella F, Martinelli F. Autogenous particulate bone collected with a piezo-electric surgical device and bone trap: A microbiological and histomorphometric study. *Archives of oral biology.* 2006;51(10); 883-891.
- [5]. Gruber RM, Kramer FJ, Merten HA, et al. Ultrasonic surgery – An alternative way in orthognathic surgery of the mandible. A pilot study. *Int J Oral Maxillofac Surg.* 2005; 34:590
- [6]. Anne Pederson. Interrelation of complaints after removal of impacted mandibular third molars. *Int J Oral Surg.* 1985; 14; 241-244
- [7]. Olze A, Pynn V, Kraul V, et al. Dental age estimation based on third molar eruption in first nations people of Canada. *J Forensic Odontostomatol.* 2010;28(1):32-38.
- [8]. Goyal M, Marya K, Jhamb A, Chawla S, Sonoo PR, Singh V, Aggarwal A. Comparative evaluation of surgical outcome after removal of impacted mandibular third molars using a Piezotome or a conventional handpiece: a prospective study. *British Journal of Oral and Maxillofacial Surgery* 2012; 50: 556–561.
- [9]. Tsai S-J, Chen Y-L, Chang H-H, Shyu Y-C, Lin C-P. Effect of piezoelectric instruments on healing propensity of alveolar sockets following mandibular third molar extraction. *Journal of Dental Sciences* 2012; 7: 296-300.
- [10]. M. Robiony, F. Polini, F. Costa, T. Vercellotti and M. Politi. Piezoelectric bone cutting in multipiece maxillary osteotomies. *J Oral Maxillofac surg.* 2004; 62; 759-761
- [11]. Morris CR, Jerman AC. Panoramic radiographic survey: a study of embedded third molars. *J Oral Surg.* 1971;29:122–5.