

## A rare case of scalp defect with exposed brain matter

Dr. Naga Prasad.N<sup>1</sup>, Dr. Praveen Harish.G<sup>2</sup>, Dr. Sreenivasa Rao Pavuluri<sup>3</sup>,  
Dr. Ravindranath.B<sup>4</sup>, Dr. Sreekar.N<sup>5</sup>, Dr. Rasheeqa.G<sup>6</sup>

<sup>2,3,4:</sup> Assistant Professor, Department of Plastic surgery, Osmania General Hospital, Hyderabad 500001, India

<sup>1:</sup> Professor and HOD, Department of Plastic Surgery, Osmania General Hospital, Hyderabad 500001, India

<sup>5,6:</sup> Senior Residents, Department of Plastic Surgery, Osmania General Hospital, Hyderabad 500001, India

### I. Introduction

Reconstruction in patients with scalp and/or calvarial defects can be simple or complex. Over the past several decades, an improved understanding of the blood supply of local flaps, has greatly contributed to the ability of plastic surgeons to repair these defects.<sup>1</sup>

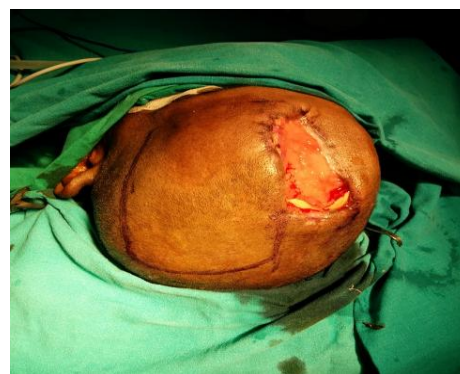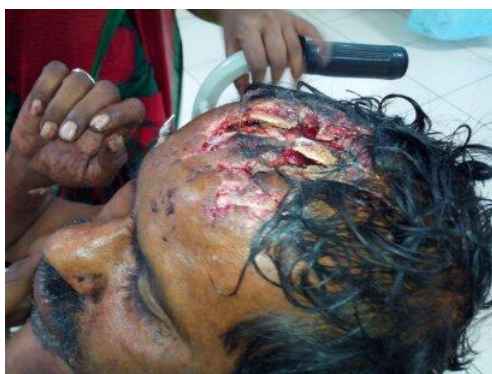As with reconstructions at other locations, the reconstructive “ladder” applies to scalp and calvarial reconstruction. Primary closure is the first choice when feasible. Other methods of reconstruction, in ascending order of complexity, are skin grafts, local flaps with or without tissue expansion, occasionally regional flaps and free flaps.<sup>1</sup> a carefully planned local transposition or rotation flap may be equally effective, and the technical difficulties and donor-site problems associated with microsurgical tissue transfer are then avoided.<sup>2</sup> this case report is about one such rare case with complete calvarial and scalp defect.

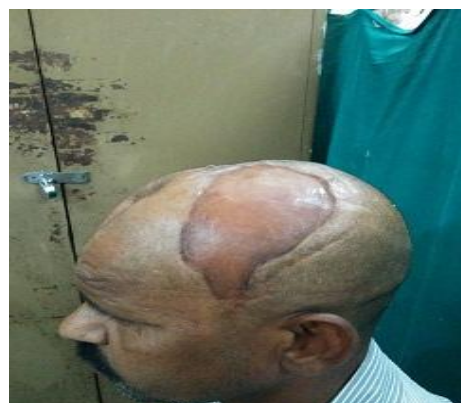
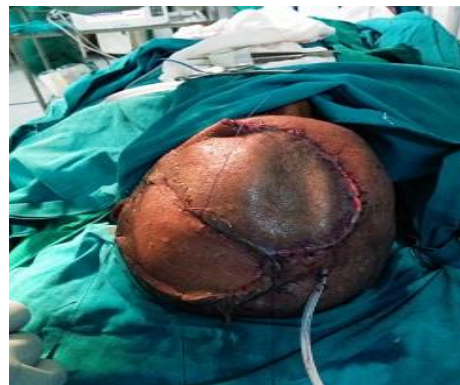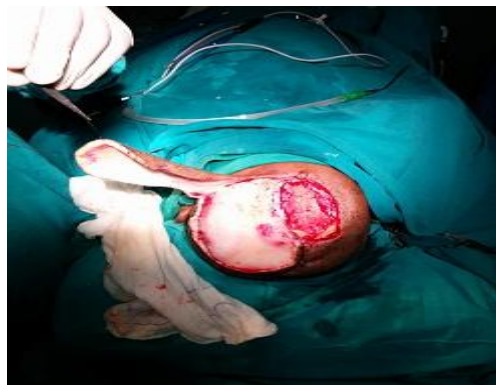### II. Case report

A 35 year old male, a worker in a bakery, was brought in the emergency by his wife on the eve of New Year with a history of having fallen down from the 3rd floor of a building while delivering some New Year cakes.

On examination the patient was conscious but disoriented and had a full thickness scalp and calvarial defect with visible exposed pulsatile brain matter. He was immediately admitted in the neurosurgical department and stabilized. A CT scan showed minor sub arachnoids bleed. Patient was stabilised further with higher antibiotics and IV fluids and local wound care and he gained back his orientation on 4th day. He was then shifted to plastic surgery for further management.

After complete work-up, patient was taken up for surgery on the 7th day (local flap cover). General anaesthesia was given and a transposition flap was marked on the left lateral aspect of the wound. Haemostatic sutures were taken. Flap was raised and insetted into the defect. Donor area of the flap was covered with split thickness graft from the left thigh. Post operative period was uneventful and the patient was discharged on the 6th post op day with a plan for cranioplasty subsequently.





### III. Discussion

The management of scalp defects remains a continuous challenge to the reconstructive surgeon worldwide.<sup>3</sup> This becomes even so in many centers in developing countries where presentation and dearth of personnel and equipment's remains the norm. The timing of reconstruction depends on many factors including the condition of the patient, associated injuries, and the size and nature of the underlying defect.<sup>4</sup>

Skull defects in the parietal and occipital areas may represent less of a problem from a cosmetic point of view but may still require cranioplasty for protective purposes. Defects in the temporal region are less obvious, being somewhat protected by the overlying temporalis muscle, and thus less frequently require cranioplasty. Defects in the frontal region warrant cranioplasty for both cosmetic and protective reasons.<sup>5</sup> A carefully planned local transposition or rotation flap may be equally effective, and the technical difficulties and donor-site problems associated with microsurgical tissue transfer are then avoided.<sup>2</sup>

### IV. Conclusion

In our case, the patient faced life threatening situation with exposed brain matter and had to be stabilised first in order to save his life. Our plan was a local transposition flap because the patient was the only earning member of the family and had to get back to work as soon as possible. Owing to the limited facility of microvascular surgery in our government set up and the known technical difficulties and morbidity of the donor sites, a local transposition flap worked out as the best option for this patient with subsequent plan for cranioplasty after the flap is well settled.

### References

- [1]. Samuel J. Lin, M.D., Matthew M. Hanasono, M.D., and Roman J. Skoracki, M.D. Scalp and Calvarial Reconstruction. *Semin Plast Surg.* Nov 2008; 22(4): 281–293.2
- [2]. Lesavoy, Malcolm A. M.D.; Dubrow, Terry J. M.D.; Schwartz, Robert J. M.D.; Wackym, Phillip A. M.D.; Eisenhauer, Donna M. M.D.; McGuire, Michael M.D. Management of Large Scalp Defects with Local Pedicle Flaps. *Plastic and reconstructive surgery American Society of Plastic Surgeons* April 1993 - Volume 91 - Issue 5
- [3]. Freund, R.M. Scalp, calvarium and forehead reconstruction. In: *Grab and Smith's Plastic Surgery*, 5th edition. Edited by Aston S.J., Beasley R.W. and Thorne C.H.M. Lippincott-Raven Publishers, Philadelphia 1997; 473-478
- [4]. McGregor I. A. *Fundamental Techniques of Plastic Surgery*, 8th edition. Churchill Livingstone. 1990; 119-124.
- [5]. Jurkiewicz, M. J. and Hill, H. L. Open wounds of the scalp: an account of methods of repair. *J. Trauma.* 1981; 21:769-77.