

## Intraseptal Supernumerary Tooth: A Case Report

Roohie Singh<sup>1</sup>, Jeevan R Galagali<sup>2</sup>

<sup>1</sup>(Consultant ENT surgeon, Military Hospital, Jodhpur, India)

<sup>2</sup> (Consultant ENT surgeon and HOD , Command Hospital, Pune, India)

**Abstract:** Ectopic eruption of tooth within dentate region of jaw is often noticed in clinical practice. But, in non dentate region, it is rare and scantily documented. We present a case of intraseptal ectopic supernumerary tooth in which the principle complaint was unilateral nasal obstruction . Ectopic tooth could be a cause for deviated nasal septum. Great suspicion is essential for clinician to consider this matter in patient with nasal obstruction..

**Keywords:** ectopic tooth, intraseptal, Supernumerary

### I. Introduction

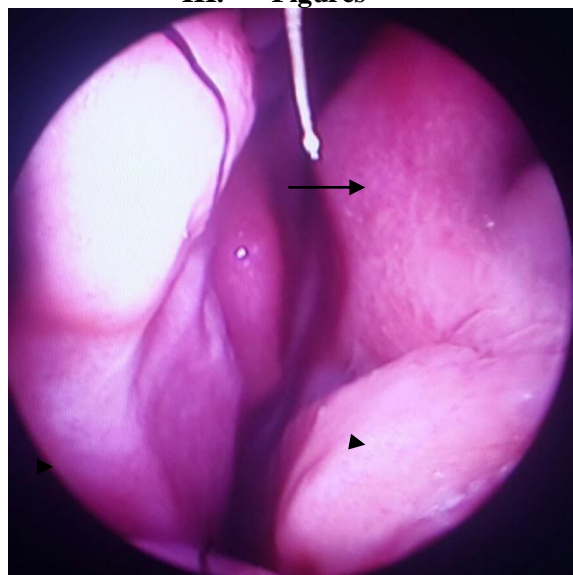
Extra teeth are usually termed supernumerary but some authors reserve this term to describe extra teeth that are ill formed while reserving the term supplemental for extra teeth that have the shape and size of a normal tooth .[1] The incidence of supernumerary teeth generally affects 0.1 to 1.0 percent of the population, and of these cases only a small percentage develop intranasal tooth.[2] We present a case of intraseptal nasal tooth with nasal obstruction as presenting complaint.

### II. Case Report

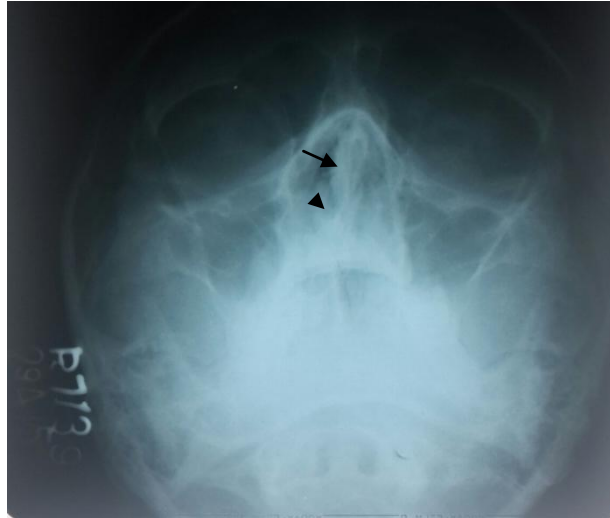
A 22 years male presented with history of right nasal obstruction since 3 months. There was no history of nasal discharge, facial pain or pressure and bleeding from nose. General physical examination of patient was normal. Anterior rhinoscopy revealed an inferior nasal spur on right side anteriorly with high DNS (deviated nasal septum) to right posteriorly. This was further confirmed by rigid nasal endoscopy (Fig 1). X ray Paranasal sinuses (PNS) revealed DNS to right and some density in floor of nasal septum that was noted on second look (Fig 2). Rest of Otorhinolaryngological examination was normal.

The patient underwent Septoplasty under local anesthesia. Freer's incision was given on left side of septum and mucoperichondrial flap elevated. While dissecting septal quadrilateral cartilage, a white hard slightly mobile object was noticed in floor of nasal septum anteriorly ( Fig 3). It was then pulled out after septal floor osteotomy. To our surprise, it was a supernumerary tooth with partially developed root (Fig 4). On oral examination, dental count was normal. The septoplasty was then completed and post-op course was uneventful.

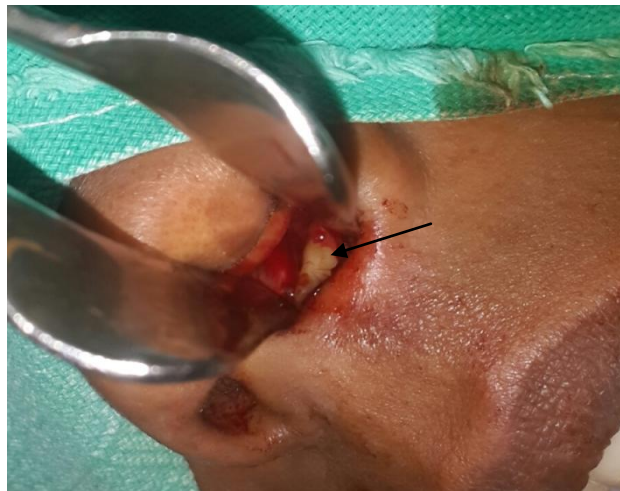### III. Figures



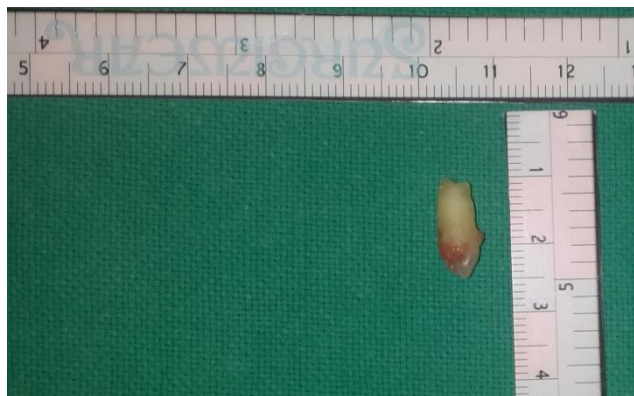**Figure 1:** Rigid nasal endoscopic view showing anteroinferior spur on right side (arrowhead) and posterior high DNS to right (arrow)



**Figure 2:** X ray PNS showing DNS to right (arrow) and density in nasal floor (arrowhead)



**Figure 3:** Intra-op picture showing tooth in floor of nasal septum (arrow)



**Figure 4:** Extracted supernumerary tooth (15 mm length)

#### **IV. Discussion**

Nasal teeth are rare form of supernumerary teeth. The most common location is the upper incisor area known as mesiodens. [2,3] The age and diagnosis of intranasal teeth ranges from 3-62 years. There is no sex predilection. Most commonly single ectopic tooth is found but multiple teeth has been reported. [4]

Supernumerary teeth develop either from a third tooth bed that arises from the dental lamina near the permanent tooth bud or possibly from splitting of the permanent bud itself. Another theory is that their

development is a reversion to the dentition of extinct primates, which had three pairs of incisors .[5] Although the cause of ectopic growth is not well understood, it has been attributed to obstruction at the time of tooth eruption secondary to crowded dentition, persistent deciduous teeth, or exceptionally dense bone. Other proposed pathogenetic factors include a genetic predisposition; developmental disturbances, such as a cleft palate; rhinogenic or odontogenic infection; and displacement as a result of trauma or cysts .[6]

The tooth may be asymptomatic at the time of diagnosis and may be noticed on routine clinical or radiological examination. The symptoms include unilateral nasal obstruction, foul smelling rhinorrhea, crusting, localized ulceration, nasal congestion, epistaxis and foreign body sensation. Uncommon symptoms are pain in face and nose , sometimes simulating tic doloreux and nasolacrimal duct obstruction. [7] The complications associated with ectopic teeth include rhinitis caseosa[8], oronasal fistula.[9]

Clinically, an intranasal tooth may be seen as a white mass in nasal cavity surrounded by granulation tissue and debris. The diagnosis is usually not difficult, but may be missed most easily when the tooth is almost completely embedded in the nasal mucosa and is on the nasal floor, where it may be overlooked in the routine examination. On probing, the tooth is hard, usually smooth and slightly mobile. This is helpful to differentiate it from exostosis and odontomas , which are not mobile and from foreign bodies and sequestra, which are usually readily mobile.[7]

Radiologically, the nasal teeth appear as radio-opaque lesion with the same attenuation as that of the oral teeth. The exact relationships of the supernumerary tooth can be studied by the panoramic radiology using an orthopantogram. This can provide a good record of all the teeth present, whether erupted or not.[3] The differential diagnosis of nasal teeth includes radiopaque foreign body; rhinolith;inflammatory lesions due to syphilis, tuberculosis, or fungal infection with calcification; benign tumors, including hemangioma, osteoma, calcified polyps, enchondroma, and dermoid; and malignant tumors, such as chondrosarcoma and osteosarcoma. However, the Computed tomography (CT) findings of tooth-equivalent attenuation and a centrally located cavity are highly discriminating features that help to confirm the diagnosis .[3]

The treatment of ectopic teeth is surgical. Removal of nasal teeth is generally advocated to alleviate the symptoms and prevent complications. When an extra tooth is in the nasal cavity, the procedure is usually minor operation. When a tooth has a bony socket in the floor of nose, it may be extremely difficult to extract.The best time to remove the tooth is after the roots of the permanent teeth have completely formed, to avoid injury during their development.[7]

In case of intraseptal ectopic tooth; because of the complications of septoplasty before completion of growth, like septal perforation and facial growth retardation, early surgical removal is not indicated in uncomplicated cases .[10]

Our patient presented with unilateral nasal obstruction. Clinically findings were suggestive of inferior nasal spur on right side anteriorly with high DNS to right posteriorly. In our case, since the tooth was too close to bone , the discrimination of tooth and bone was difficult and so radiological diagnosis was missed in first look. We did not diagnose the ectopic supernumerary tooth until performing the surgery. All symptoms were relieved after surgery. Hence, surgery was both diagnostic and curative.

## V. Conclusion

An ectopic intranasal tooth can be a cause of septal deviation. The variable presenting complaints make the diagnosis difficult. It is more challenging when tooth is located in the septum. Ectopic tooth should be considered in differential diagnosis of any radio-opaque mass in imaging.

## References

- [1]. Worth HM. Principles and practice of oral radiologic interpretations. (Year book medical publishers Inc, Chicago iii 1968) ; 101-105.
- [2]. Arunkumar JS, Prasad KC, Shanthi N. Nasal Teeth: A Case Report. Indian J Otolaryngol Head Neck Surg.2007;59(2):197-8. [PMC free article] [Pubmed]
- [3]. Chen A, Huang JK, Cheng SJ, Sheu CY. Nasal teeth: Report of Three Cases. Am J Neuroradiol. 2002;23(4):671-3. [Pubmed]
- [4]. Smith RA, Gordoin NC, De-Luchi SF. Intranasal teeth:report of two cases and review of literature. Oral Surg Oral Med Oral Pathol 1979; 47:120-22.
- [5]. Thawley SE, Ferriere KA. Supernumerary nasal tooth. Laryngoscope 1977;87:1770-1773. [Medline](#)
- [6]. Moreano EH Zick DK, Goree JC, et al. Nasal tooth. Am J Otolaryngol 1998;19:124-126 . [CrossRef](#) [Medline](#)
- [7]. J Gulia, S Yadav, A Gupta, A Hooda. Intranasal tooth; Report of an unusual case and review of literature. The Internet Journal of Head and Neck Surgery. 2009 Volume 4 Number1.
- [8]. Abercrombie PH. Eruption of a canine tooth into the nasal fossa attended by rhinitis caseosa. J Laryngol Otol 1925;40:586-9.
- [9]. El Sayed Y. Sino-nasal teeth. J Otolaryngol 1995; 24:180-83.
- [10]. Abhishek Paroliya, M Kundabala, Marisha Dahal, Mandakini Mohan, Manuel S Thomas. Management of supernumerary teeth; J Conserv Dent.2011 Jul-Sep; 14(3): 221-224.