

Pulpitis: A review

Dr Syed Gufaran Ali¹, Dr Sanjyot Mulay²

¹PhD scholar, Faculty of Dental Sciences, Pacific Academy of Higher Education & Research University, Udaipur – 313024

²Professor, PG & PhD Guide, Department of Conservative Dentistry & Endodontics, Dr. D Y Patil Dental College & Hospital, Pune-411018

Abstract: Clinicians must recognize that diseases of the pulp and periapical tissues are dynamic and progressive and thus various modes and methods should be used to get the accurate diagnosis. A key purpose of establishing a proper pulpal and periapical diagnosis is to determine what clinical treatment is needed. This review article briefly describes on how to diagnose the pulpal condition and what are its treatment options.

Keywords: reversible pulpitis, irreversible pulpitis, root canal treatment, local anesthesia

I. Introduction

The dental pulp is a connective tissue consisting of nerves, blood vessels, ground substances, interstitial fluid, odontoblasts, fibroblasts, and other cellular components. Historically, there have been a variety of diagnostic classification systems advocated for determining endodontic disease.¹ Unfortunately, the majority of them have been based upon histopathological findings rather than clinical findings, often leading to confusion, misleading terminology, and incorrect diagnoses.² A key purpose of establishing a proper pulpal and periapical diagnosis is to determine what clinical treatment is needed.^{3,4} For example, if an incorrect assessment is made, then improper management may result. This could include performing endodontic treatment when it is not needed or providing no treatment or some other therapy when root canal treatment is truly indicated.

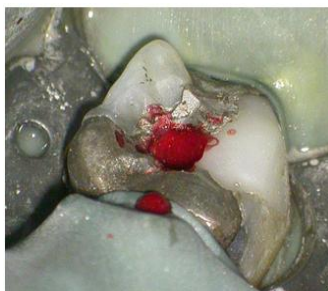

Fig 1: Pulp exposure

Clinicians must recognize that diseases of the pulp and periapical tissues are dynamic and progressive and as such, signs and symptoms will vary depending on the stage of the disease and the patient status. Coupled with this are the limitations associated with current pulp testing modalities as well as clinical and radiographic examination techniques. In order to render proper treatment, a complete endodontic diagnosis must be made on the basis of –

1. Signs and symptoms,
2. Thorough clinical examination and
3. Detailed radiographic examination.

The etiology of pulpitis are:⁵

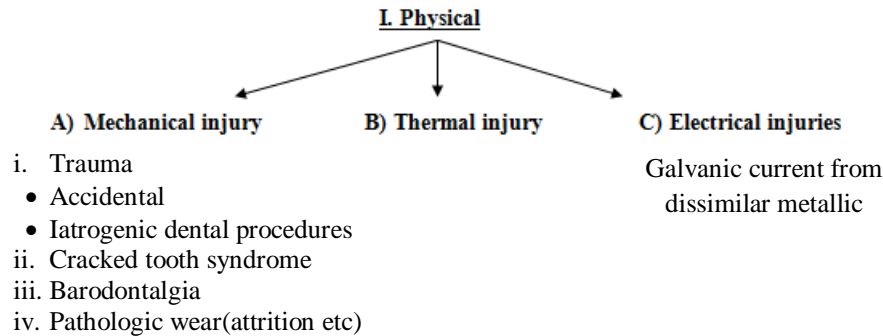
I. Physical

II. Chemical

- a) Phosphoric acid, acrylic monomer
- b) Erosion (Acids)

III. Bacterial

- a) Toxins associated with caries.
- b) Direct invasion of pulp from caries or trauma.
- c) Microbial colonization in the pulp by blood borne microorganisms (Anachoresis)

**A) Mechanical injury****I. Trauma:**

1. Traumatic injury may or may not be accompanied by fracture of the crown or root.
2. More in children than in adults.
3. Habits such as
 - Opening bobby pins with the teeth,
 - Compulsive bruxism,
 - Nail biting etc.
4. In addition certain dental procedures occasionally injure the pulp:
 - Exposure of the pulp during excavation of carious tooth structure.
 - The use of pins for mechanical retention of amalgam or other restoration.
 - Malleting of gold-foil filling without adequate cement base.
 - Rapid separation of teeth by means of a mechanical separator.
 - Too-rapid movement of the teeth during orthodontic treatment.

II. Cracked tooth syndrome

1. Incomplete fractures through the body of the tooth may cause pain of apparently idiopathic origin. This is referred to as the “cracked tooth syndrome”.
2. The patient usually complains of pain, ranging from mild to excruciating, at the release of the biting pressure.
3. The most reliable diagnostic method is to try to reproduce the pain (pain occurs because the fractured segments may separate).
4. Diagnosis of cracked tooth may be done by:
 - i. Dye or transilluminating the cracked tooth.
 - ii. Using tooth slot.
5. Crown restoration immobilizing the fragment. (If the fracture involves only enamel & dentin).

III. Barodontalgia

1. Barodontalgia, also known as aerodontalgia denotes toothache occurring at low atmospheric pressure at high altitude.
2. A tooth with chronic pulpitis can be symptomless at ground level, but it may cause pain at high altitude.
3. Barodontalgia has generally been observed in altitude between 5000-10000feet.
4. Lining the cavity with a varnish or a base of zinc-phosphate cement, with a sub base of zinc oxide-eugenol cement in deep cavities, helps to prevent barodontalgia.
5. Rauch classified barodontalgia according to chief complaint:
 - i. Class I : Acute pulpitis – Sharp pain – Ascent
 - ii. Class II : Chronic pulpitis – Dull throbbing pain – Ascent
 - iii. Class III : Necrosis – Dull throbbing pain – Descent, Asymptomatic – Ascent
 - iv. Class IV : Periapical abscess – Pain with both ascent & descent

VI. Pathologic wear

The pulp may also become exposed or nearly exposed by pathologic wear of the teeth from either abrasion or attrition if secondary dentin is not deposited rapidly enough.

B) Thermal:

1. Heat from cavity preparation.
2. Frictional heat caused by polishing a restoration.

3. Exothermic heat from the setting of cement.
4. Direct conduction of heat and cold through deep fillings without a protective base.

II. Chemical:

1. Arsenic in silicate restorations and desensitization paste are the most frequent cause of pulp death.
2. Key factors that would determine pulpal reaction to restorative material are:
 - i. Acidity (pH of the material).
 - ii. Absorption of water during setting reaction.
 - iii. Poor marginal adaptation of material.

III. Bacterial:

1. In 1894, W.D. Miller suggested that bacteria were a possible cause of inflammation in the pulp.
2. The presence or absence of bacterial irritation will determine the pulp survival once the pulp has been mechanically exposed.
3. The bacteria most often recovered from infected vital pulps are streptococci and staphylococci, but many other micro-organisms, including anaerobes, have also been isolated.
4. Lactobacilli are commonly found in carious dentin, they are seldom recovered from pulp because of their low degree of invasiveness.

Reversible pulpitis:

Reversible pulpitis is a mild to moderate inflammatory condition of the pulp caused by noxious stimuli in which the pulp is capable of returning to the uninflamed state following removal of the stimuli. Discomfort is experienced when a stimulus such as cold or sweet is applied and goes away within a couple of seconds following the removal of the stimulus.⁶

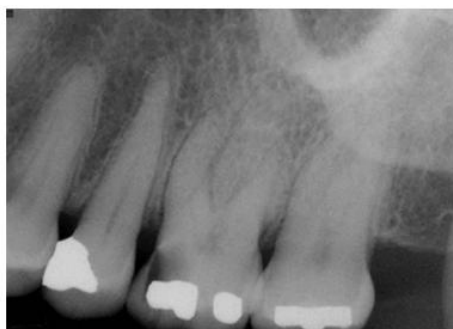

Fig 2: Maxillary left first molar has mesio-occlusal caries and the patient has been complaining of sensitivity to sweets and to cold liquids. There is no discomfort to biting or percussion. The tooth is hyper-responsive to Endo-Ice with no lingering pain. **Diagnosis: reversible pulpitis; normal apical tissues.**

Histopathology:

Reversible pulpitis may range from hyperemia to mild to moderate inflammatory changes limited to the area of the involved dentinal tubules, such as dentinal caries. Microscopically, one may see

- Dilated blood vessel.
- Extravasation of edema fluids.
- Disruption of the odontoblast layer.
- Reparative dentin.
- Acute & Chronic inflammatory cells.

Symptoms:

1. Symptomatic reversible pulpitis is characterized by sharp pain lasting for a moment.
2. It is more often brought on by cold than hot food or beverages and by cold air.
3. It does not occur spontaneously and does not continue when the cause has been removed.

Diagnosis:

1. Diagnosis is based on the symptoms.
2. Pain may become chronic. Although each paroxysm may be of short duration, the paroxysms may continue for weeks or even months.
3. A tooth with reversible pulpitis reacts normally to percussion, palpation, and mobility, and the periapical tissue is normal on radiographic examination.

Differential diagnosis:

1. Irreversible pulpitis.
2. The pain is generally transitory, lasting a matter of seconds. Whereas in irreversible pulpitis, the pain may last several minutes or longer.

Treatment:

1. Best treatment is prevention.
 - Periodic care to prevent the development of caries.
 - Early insertion of a filling if a cavity has developed.
 - Desensitization of tooth neck in case of recession.
2. When reversible pulpitis is present, removal of the noxious stimuli .
3. Once the symptoms have subsided, the tooth should be tested for vitality, to make sure that pulpal necrosis has not occurred.
4. When pain persists despite proper treatment, the pulpal inflammation should be regarded as irreversible, the treatment for which is pulp extirpation.⁶

Prognosis:

The prognosis for the pulp is favorable if the irritant is removed early enough; otherwise, the condition may develop into irreversible pulpitis.

Irreversible pulpitis:

Symptomatic Irreversible Pulpitis is based on subjective and objective findings that the vital inflamed pulp is incapable of healing and that root canal treatment is indicated. Characteristics may include sharp pain upon thermal stimulus, lingering pain (often 30 seconds or longer after stimulus removal), spontaneity (unprovoked pain) and referred pain. Sometimes the pain may be accentuated by postural changes such as lying down or bending over and over-the-counter analgesics are typically ineffective. Teeth with symptomatic irreversible pulpitis may be difficult to diagnose because the inflammation has not yet reached the periapical tissues, thus resulting in no pain or discomfort to percussion. In such cases, dental history and thermal testing are the primary tools for assessing pulpal status.⁶

Asymptomatic Irreversible Pulpitis is a clinical diagnosis based on subjective and objective findings indicating that the vital inflamed pulp is incapable of healing and that root canal treatment is indicated. These cases have no clinical symptoms and usually respond normally to thermal testing but may have had trauma or deep caries that would likely result in exposure following removal.⁶

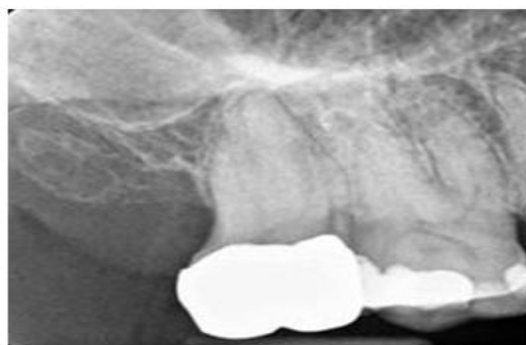

Fig 3: Following the placement of a full gold crown on the maxillary right second molar, the patient complained of sensitivity to both hot and cold liquids; now the discomfort is spontaneous. Upon application of Endo-Ice on this tooth, the patient experienced pain and upon removal of the stimulus, the discomfort lingered for 12 seconds. Responses to both percussion and palpation were normal; radiographically, there was no evidence of osseous changes. **Diagnosis: Symptomatic irreversible pulpitis normal apical tissues.**

Histopathology:

1. Microscopically, one sees the area of the abscess with microorganisms present if in the late carious state, along with lymphocytes, plasma cells, and macrophages.
2. No microorganisms are found in the center of the abscess because of the phagocytic activity of the polymorphonuclear leukocytes.

Symptoms:

1. The pain often continues when the cause has been removed, and it may come and go spontaneously, without apparent cause.
2. The patient may describe the pain as sharp piercing, or shooting, and it is generally severe.
3. The patient may also state that bending over or lying down, that is change of position, exacerbates the pain; changes in intrapulpal pressure may be the cause.
4. When no outlet is present, whether because of a covering of decay or a filling or because of food packed into a small exposure in the dentin, pain can be most intense.
5. The patient may also have pain referred to adjacent teeth, to the temple or sinuses when an upper posterior tooth is involved, or to the ear when a lower posterior tooth is affected.
6. Pain is increased by heat and is sometimes relieved by cold, although continued cold may intensify the pain.
7. Apical periodontitis is absent, except in the later stages, when inflammation or infection extends to the periodontal ligament.

Diagnosis:

1. Inspection generally discloses a deep cavity extending to the pulp.
2. The surface of the pulp is eroded. An odor of decomposition is frequently present in this area.
3. Probing into the area is not painful to the patient until the deeper areas of the pulp are reached.
4. A radiograph may also show exposure of the pulp.

Differential diagnosis:

1. One must distinguish between reversible and irreversible pulpitis.

REVERSIBLE PULPITIS	IRREVERSIBLE PULPITIS
Pain lasts for a moment.	Pain is severe & last longer.
Stimulus requires to elicit the pain.	Spontaneous pain.
Sharp pain	- In later stages – Boring, Gnawing or throbbing - Sharp, piercing or shooting
EPT uses less current than on a controlled tooth.	Asymptomatic stage: Early Symtomatic stage: Less More: current is required than a control tooth.

2. In later stage of irreversible pulpitis, the symptoms may simulate those of an acute alveolar abscess.
3. Abscess has following symptoms which helps in differentiating it from pulpitis:
 - Tenderness on percussion.
 - Tenderness on palpation.
 - Swelling.
 - Mobility.
 - Lack of response to pulp vitality testing

Treatment:

1. Complete removal of pulp / Pulpectomy.
2. In posterior teeth – removal of coronal pulp / Pulpotomy should be performed as an emergency procedure.

Prognosis:

The prognosis of the tooth is favorable if the pulp is removed and if the tooth undergoes proper endodontic therapy and restoration.

Special considerations:

When irreversible pulpitis is present, the teeth that are most difficult to anesthetize are mandibular molars, followed by mandibular premolars, the maxillary molars and premolars, and the mandibular anterior teeth. The fewest problem arise in the maxillary anterior teeth. In some teeth, irreversible pulpitis is the condition in the apical portion of the canals; the tissue in the chamber is necrotic and does not respond to pulp testing. The pulp chamber can be entered easily, but when attempts are made to place a file to length, severe pain results. In such cases supplemental injections are of great help.⁵

Mandibular teeth:⁵

Up until the 1980s, before supplemental intraligamentary and intraosseous injections became popular, clinicians would administer conventional anesthesia. After signs of soft tissue anesthesia became evident, the pain abated and the patient relaxed. Local anesthesia produces the classic soft tissue signs and relieved the painful symptoms. However pain frequently resulted when the access opening was begun or pulp was entered. Currently, this pain has been significantly reduced with supplemental techniques.

Maxillary molar:⁵

The initial anesthetic dose of 2 % lidocaine with 1:100000 epinephrine is doubled (to 3.6 ml) for the buccal infiltration. Although fewer anesthetic problems develop with the maxillary molars and premolars than with the mandibular posterior teeth, the clinician should be aware that they can occur. As an alternative, the clinician can administer the anesthetic and then test the pulp with an EPT or cold refrigerant. If the response is negative, access preparation may proceed. If the response is positive, an intraosseous injection or an intraligamentary injection should be given. The clinician must keep in mind that pulp testing may not guarantee pulpal anesthesia in teeth with irreversible pulpitis. Therefore, if a patient experiences pain despite a negative result on pulp testing, supplemental anesthesia injections should be given.

Infiltration anesthesia does not last as long in maxillary teeth as in mandibular teeth. If the patient experience pain during the later stages of instrumentation, an additional infiltration injection is necessary. Occasionally, pain is experienced in the palatal canals of molars. Infiltration over the palatal apex with 0.5 ml of anesthetic solution enhances pulpal anesthesia and prove helpful, although it is very painful.

References

- [1]. Glickman GN. AAE consensus conference on diagnostic terminology: background and perspectives. *J Endod* 2009;35:1619.
- [2]. Seltzer S, Bender IB, Ziontz M. The dynamics of pulp inflammation: correlations between diagnostic data and actual histologic findings in the pulp. *Oral Surg Oral Med Oral Pathol* 1963;16:846-71;969-77.
- [3]. Berman LH, Hartwell GR. Diagnosis. In: Cohen S, Hargreaves KM, eds. *Pathways of the Pulp*, 11th ed. St. Louis, MO: Mosby/Elsevier; 2011:2-39.
- [4]. Schweitzer JL. The endodontic diagnostic puzzle. *Gen Dent* 2009; Nov/Dec. 560-7.
- [5]. Al Reader, Nusstein J, Hargreaves KM. Local anesthesia in endodontics. *Pathways of the pulp*. 9th ed. St. Louis, Missouri: Mosby/Elsevier 2006.
- [6]. Dabuleanu M. Pulpitis reversible/irreversible. *J Can Dent Assoc* 2013;79:90-94.