

A Rail-Road Technique of Ryle's Tube/Nasogastric Tube Insertion in an Intubated Patient: A Case Report

Yogesh Rathod¹, Suyog Bagade¹, Pratiksha Sagare¹, Nirav Kotak², R D Patel³.

¹Student, MD Anaesthesia 3rd year, Department of Anaesthesiology and Critical Care, Seth G S Medical College & KEM Hospital, Mumbai, India.

²Associate Professor, Department of Anaesthesiology and Critical Care, Seth G S Medical College & KEM Hospital, Mumbai, India.

³Professor, Department of Anaesthesiology and Critical Care, Seth G S Medical College & KEM Hospital, Mumbai, India.

Abstract : Insertion of a nasogastric tube in an unconscious intubated patient may be difficult as they cannot follow the swallowing instructions, and therefore has a high first attempt failure rate. The use of nasogastric tube is desirable for some surgical procedures to keep stomach deflated (like laparoscopic surgeries) or for the short term administration of feeds post-operatively. We had a thirty five-year-old male who was posted for laparoscopic cholecystectomy. Surgery demanded Ryle's tube insertion after creating pneumo-peritoneum because inflated stomach was obscuring their view. We tried for Ryle's tube insertion in our patient through both nostrils but failed. So with the help of Rail-road technique using another endotracheal tube, infant feeding tube/ suction catheter and Magill's forceps we successfully inserted the nasogastric tube without any oropharyngeal trauma to the patient. Patient was hemodynamically stable throughout the procedure.

Keywords – Nasogastric tube (Ryle's tube), Endotracheal tube, Infant feeding tube/Suction catheter, Magill's forceps, Rail-road technique

I. Introduction

Nasogastric (NG) tube insertion is used to deliver nutrition or medication in hospital wards and intensive care units, in operating room intra-operatively and post-operatively too. Patient cooperation by swallowing on instruction while inserting an NG tube is important. So inserting a NG tube in an awake patient is not much difficult. But in an intubated patient, inserting a NG tube is little difficult as we can't instruct an unconscious and intubated patient to swallow. So there are high first attempt failure rates (nearly 50%) while inserting a NG tube in an intubated patient. Also after each unsuccessful insertion attempt, incidences of mucosal bleeding and hemodynamic complication increase. We devised a new technique (Rail-road technique) to insert NG tube in such patients.

II. Case Report

A 35 year old male with 60kg weight, classified under ASA I of American Society of Anesthesiology classification, with no any previous significant medical or surgical history was posted for Laparoscopic cholecystectomy in view of cholelithiasis. Patient is a chronic alcoholic and tobacco chewer since 5-6 years. Patient has adequate neck movements with mouth opening of >3 fingers of her own, Mallampatti Classification Grade I with thyro-mental distance of approximately 6 cm.

1. General examination:

Patient was conscious, oriented with time place and person,

Pulse: 92/min,

Blood Pressure: 140/83 mm of Hg,

2. Systemic Examination:

2.1 Cardiovascular System: S1S2 Heard, no murmur,

2.2 Respiratory system: Air entry bilaterally equal and clear,

2.3 Central nervous system: conscious and oriented

3. Investigations:

Hb-14.2 gm%,

TLC-8600/cmm,

platelets were

4.14 lacs/cmm

with PT-13/13.1 seconds
and INR-0.99.

Rest all investigations were within normal limit.

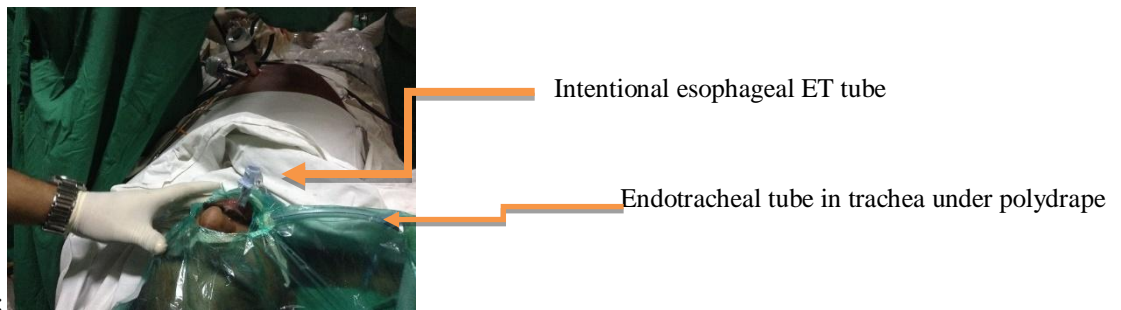
After induction of the patient, surgeon created a pneumo-peritoneum but the inflated stomach was obscuring their view. For a better view insertion of Ryle's tube was necessary to deflate the stomach. We tried insertion of the NG tube via both the nostrils but the attempts were failed. So we devised and used a Rail-road technique to insert the NG tube.

III. Anaesthetic Management And Technique

Here in this technique we used an endotracheal tube, an infant feeding tube / suction catheter and a Magill's forceps. This technique is found to be useful for unconscious and intubated patient.

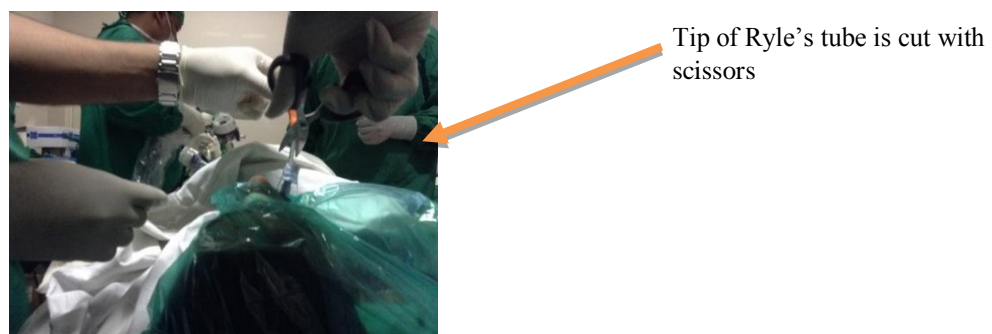
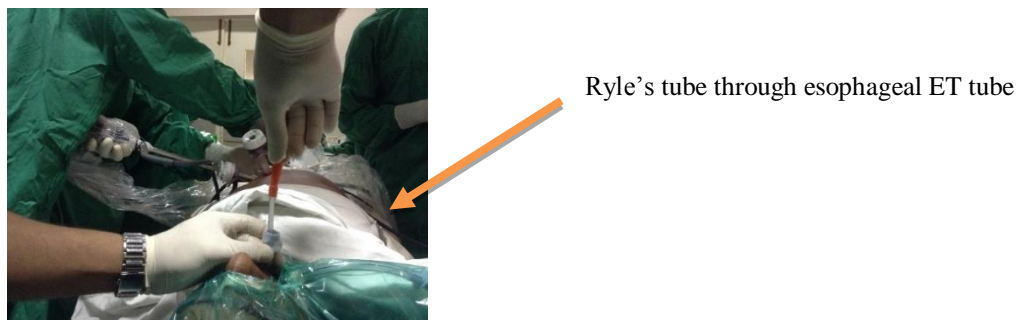
Step 1: (photograph A)

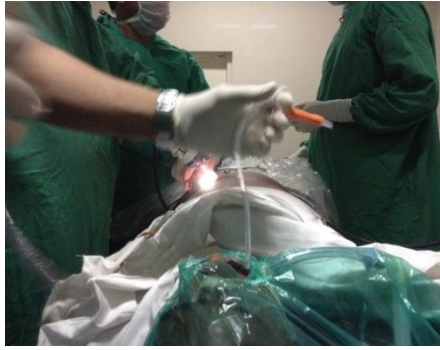An endotracheal tube of size smaller than that one in trachea is taken. In this case we used ETT no.7 and its connector was removed and cuff fully deflated. An intentional esophageal intubation was performed by slowly passing this endotracheal tube beneath the other ET tube (one in trachea)



Step 2: (photograph B,C,D)

A Ryle's tube (of appropriate size) is inserted through this esophageal ET tube, tip of the Ryle's tube is cut and ET tube is removed while simultaneously pushing Ryle's tube. With this we get a RT in stomach through oral cavity. This can be used for temporary purposes like deflation of stomach during laparoscopic procedure, suctioning before extubation to prevent aspiration risk.

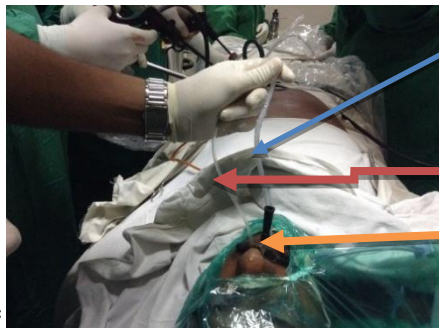



Esophageal ET tube is removed after cutting Tip Of Ryle's tube

Photograph D:

Step 3: (photograph E,F): Now an infant feeding tube/ suction catheter is inserted through nose (of size such that it snugly fits in Ryle's tube) and two fingers are inserted through mouth. It's tip removed through mouth by fingers and passed in Ryle's tube (Rail-roading).

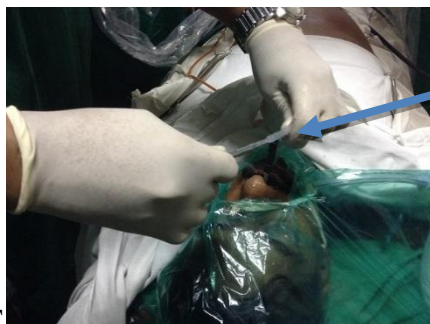

Nasogastric tube through mouth

Infant feeding tube through mouth

Infant feeding tube through nose

Photograph E:

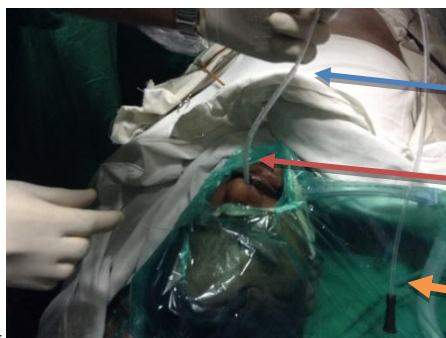


Passing an infant feeding tube through Ryle's tube- Rail-roading

Photograph F:

Here in this step if an infant feeding tube is not fitting snugly in Ryle's tube you can use Magill's forceps to hold the inner end of rail-roaded tubes.

Step 4: (Photograph G,H) : Pull the infant feeding tube back now and Ryle's tube will come out through nose. Attach a 2ml syringe nozzle(plunger removed) to the Ryle's tube and is ready to use.

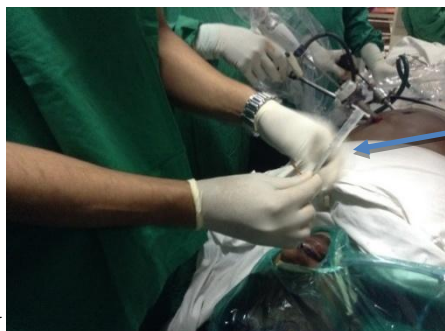

Outer end of rail-roading

Ryle's tube through nose

Infant feeding tube

Photograph G:



2ml syringe with plunger removed attached to Ryle's tube

Photograph H

So by these four steps of Rail-road technique we can insert a nasogastric tube without any trauma and with only few materials which are easily available in every operating room.

IV. Discussion

The modern soft and atraumatic NG tubes are made up of polyurethane which become more soft on exposure to patient's body temperature. Additionally, several non-opposing lateral eyes like opening near the tip make the NG tube more prone for kinking. Moreover, a curved NG tube (when it is in the packet) promotes coiling in the mouth than going straight into the esophagus.

There are few techniques described previously for difficult nasogastric tube insertion. Some have used angiography catheter⁽¹⁾ as a guide through Ryle's tube. But it's difficult to make angiography catheter available every time. Some have used Rusch stylet for insertion of NG tube⁽³⁾. But in our case we used few instruments and materials which are easily available and present in every operation theatre. We think that this Rail-Road technique is useful for difficult nasogastric tube insertion in operation theatres as well as in unconscious intubated patients.

References

- [1]. Tanmoy Ghatak, Sukhen Samanta, and Arvind Kumar Baronia A New Technique to Insert Nasogastric Tube in an Unconscious Intubated Patient N Am J Med Sci. 2013 Jan; 5(1): 68–70.
- [2]. Yohanna M Takwoingi Inadvertent insertion of a nasogastric tube into both main bronchi of an awake patient: a case report Cases Journal 2009, 2:6914
- [3]. Yung-Fong Tsai^{1,2,3}, Chiao-Fen Luo¹, Amina Illias¹, Chih-Chung Lin^{1,2} and Huang-Ping Yu^{1,2*} Nasogastric tube insertion in anesthetized and intubated patients: a new and reliable method BMC Gastroenterology 2012, 12:99 .