

## NON-Specific Granulomatous Prostatitis –Masquerading Carcinoma Prostate

Dr. Shruti Deshpande<sup>1</sup>, Dr. Sabiha Maimoon<sup>2</sup>, Dr. Sadhana Mahore<sup>3</sup>,  
Dr. Pragati Karmarkar<sup>4</sup>

<sup>1</sup>Assistant Lecturer, <sup>2</sup>Professor, <sup>3</sup> Professor & Head, <sup>4</sup> Assistant Professor, Department of Pathology, NKP Salve Institute of Medical Sciences, Nagpur 440019, Maharashtra, India

**Abstract:** Granulomatous prostatitis is a rare benign inflammatory condition of prostate. It is mistaken for prostatic carcinoma. Clinically it presents as hard nodule on digital rectal examination with raised serum prostate specific antigen (PSA) levels and reduced free PSA levels. We report a rare case of non-specific granulomatous prostatitis clinically diagnosed as carcinoma prostate.

**Keywords:** granulomatous prostatitis, non-specific granulomatous prostatitis, prostatic carcinoma

### I. INTRODUCTION

Granulomatous prostatitis (GnP) is an uncommon inflammatory disorder of prostate. It was first discovered by Tanner and McDonald in 1943<sup>[1]</sup> It presents clinically as hard, firm nodule and can be misdiagnosed as prostate cancer<sup>[2,3]</sup> Diagnosis is made by histopathological examination. Non-specific granulomatous prostatitis (NSGnP) is most common type of granulomatous prostatitis.<sup>[4,5]</sup>

### II. CASE PRESENTATION

A 55 year old male presented with high grade fever with chills on and off, dysuria, difficulty in urination since one month. On digital rectal examination a hard nodule was felt. Ultrasonography revealed prostate size of 11.5x5.5x4 cm, prostatic volume was 40cc and grade II prostatomegaly. Serum total PSA levels were 14.2 ng/dl. The free PSA levels 3.4ng/dl. Transurethral resection of prostate (TURP) was done and sent for histopathological examination. On gross examination the TURP chips received weighed 28gms. The total submission of sample was done and processed. Microscopically, the prostatic tissue showed hyperplasia of the acini with corpora amyloacea. The stroma showed many well defined non-caseating granulomas with Langhans type of multinucleated giant cells, lymphocytes, histiocytes (Fig.1 & Fig. 2). Many dilated ducts showed secretions admixed with inflammatory cells consisting of mainly eosinophils, lymphocytes, histiocytes and giant cells (Fig.3). Special stains using Ziel Neelsen and periodic acid Schiff stains did not reveal any acid-fast organism or fungal microorganisms. Other pathological finding showed benign hyperplasia of prostate with prostatic intraepithelial neoplasia grade-I and chronic inflammation (Fig.3 & Fig. 4). Carcinomatous foci were not seen. Final diagnosis of non-specific granulomatous prostatitis was given.

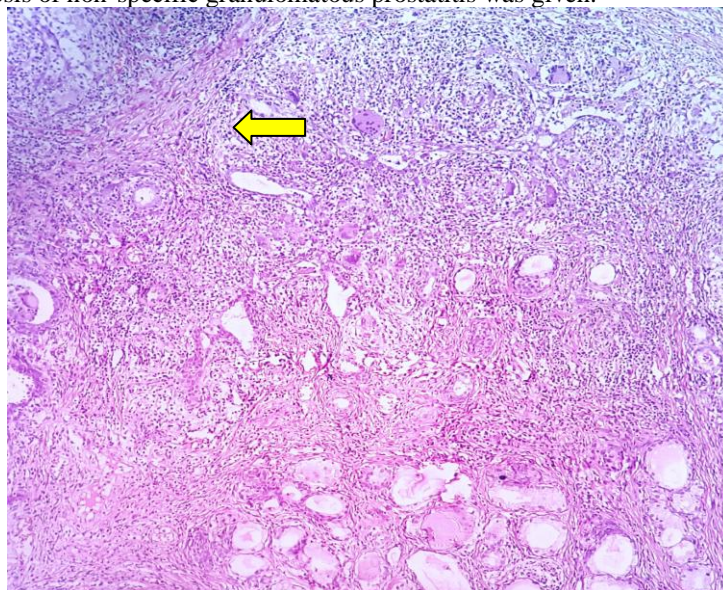


Fig.1. Non-specific granulomatous prostatitis showing granulomas and multinucleated gaint cells (100X).

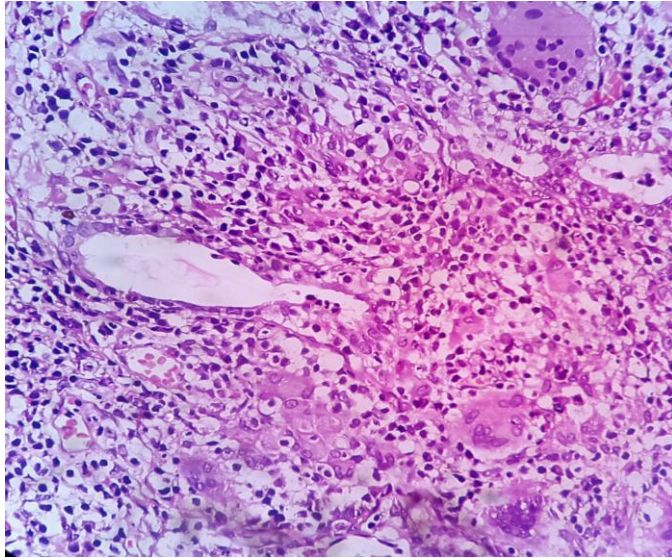


Fig.2. Mmultinucleate giant cells, histiocytes, and epithelioid cells (400X).

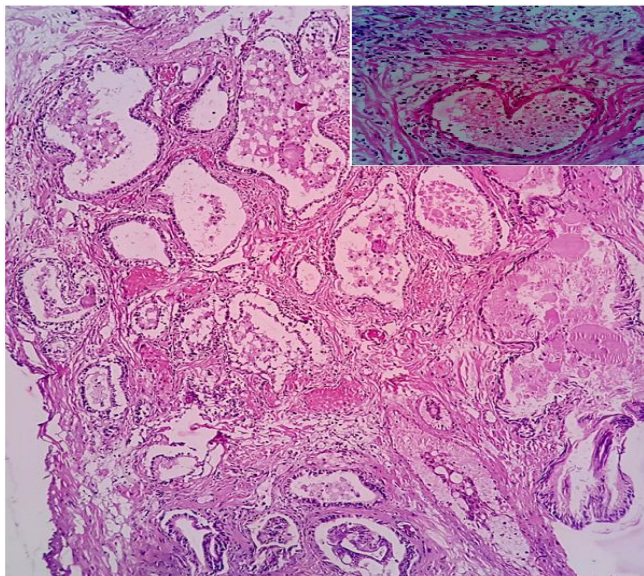


Fig.3. Benign hyperplasia of prostate with dilated ducts containing eosinophils (inset) (100X).

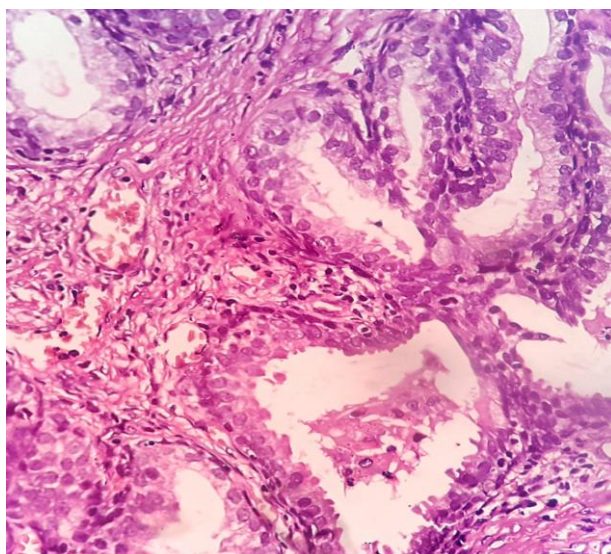


Fig.4. Prostatic intraepithelial neoplasia grade I (PIN I) (400X).

### III. DISCUSSION

In the present case, on digital rectal examination hard nodule was felt. Total PSA (tPSA) levels were minimally raised while its free PSA (fPSA) level was reduced. Usually when tPSA levels are in borderline range (4-10 ng/dl) or minimally raised, the fPSA are reduced, the diagnosis of prostate carcinoma is confirmed.<sup>[6,7]</sup> In our case tPSA levels were minimally raised while fPSA levels were reduced which was in favour of prostate carcinoma. But histopathological examination revealed non-specific granulomatous prostatitis.

Granulomatous prostatitis is a rare entity. It is classified into various types as infectious, iatrogenic, secondary to systemic granulomatous diseases, idiopathic. Rare cases of xanthogranulomatous prostatitis and malakoplakia have been reported.<sup>[2,3,4]</sup>

Non-specific granulomatous prostatitis is the most common type of granulomatous prostatitis.<sup>[2]</sup> The etiology of non-specific granulomatous prostatitis is unclear. It is mostly due to foreign body response to colloidal substances, refluxed urine, bacterial products.<sup>[2,3,4]</sup> It may be due to an immunological response to extraductal prostatic secretions arising from duct obstruction due to hyperplasia.<sup>[2,8]</sup>

Infectious prostatitis is caused by a variety of bacteria, fungi, parasites and viruses. Mycobacterium tuberculosis, Treponema pallidum are the most common bacterial causes of bacterial granulomatous prostatitis. BCG induced granulomatous prostatitis is caused due to instillation of BCG in urinary bladder.<sup>[2,3,9]</sup> Iatrogenic granulomatous prostatitis is caused after surgical procedures like TURP or needle biopsy. It occurs due to reaction to the altered epithelium and stroma due to trauma or surgery. It resolves spontaneously over time.<sup>[2,5,10]</sup>

Xanthogranulomatous prostatitis is caused due to hyperlipidemia. Microscopically foamy histiocytes are seen.<sup>[2,11]</sup> Malakoplakia is an uncommon form of granulomatous prostatitis characterised by presence of Michaelis–Gutmann bodies. Rare instances of adenocarcinoma of prostate associated with granulomatous prostatitis have been noted.<sup>[2,13]</sup>

Granulomatous prostatitis usually presents in the age group of 18- 86 years.<sup>[2,8]</sup> Clinically they present with fever, mild hematuria, frequency of urination. Digital rectal examination reveals a firm to hard nodular mass. Serum PSA levels are raised, while serum free PSA levels are reduced. Thus clinically, it can be mistaken for prostatic carcinoma.<sup>[8]</sup>

Management of the patients with granulomatous prostatitis is difficult. Non-specific granulomatous prostatitis resolves spontaneously. Infectious granulomatous prostatitis requires specific treatment. Surgical management can lead to complications like contracture and needs repeat resection.<sup>[2,14]</sup>

### IV. CONCLUSION

Non-specific granulomatous prostatitis is the most common type of granulomatous prostatitis. Though granulomatous prostatitis is a rare inflammatory disorder should be thoroughly examined as it mimics prostatic carcinoma clinically, biochemically and also by digital rectal examination and ultrasound examination.

### REFERENCES

- [1] Tanner FH, Me Donalds JR. Granulomatous prostatitis: a histologic study of a group of granulomatous lesions collected from prostate glands. Arch Pathology Lab Med 1943; 36: 358-370.
- [2] Punia R, Amanjit, Mohan H, Bawa A S. Granulomatous prostatitis – an infrequent diagnosis: Indian J Urol 2002;19: 16-19.
- [3] Stillwell TJ, Engen DE, Farrow GM. The clinical spectrum of granulomatous prostatitis: a report of 200 cases. J Urol 1987; 138: 320-323.
- [4] Bryan RL, Newman J, Campbell A, Fitzgerald G, Kadow C, O'Brien JM. Granulomatous prostatitis: a clinicopathological study. Histopathology 1991; 19: 453-457.
- [5] Epstein JI, Hutchins GM. Granulomatous prostatitis: distinction among allergic, non-specific and post-transurethral resection lesions. Hum Path 1984; 15: 818-825.
- [6] Alpeshpuri P, Goswami, Dr. G. Rupala, Dr. Nutanbala, N. Goswami, Serum PSA level in Prostatic lesions with histopathological correlation in Gujarat. NJIRM 2011; 2(4): 33-38.
- [7] M Lakhey, R. Ghimire, R. Shrestha, AD bhatta. Correlation of serum free prostate. Specific antigen level with histological findings in patients with prostatic disease. Kathmandu university medical journal (2010) vol 8, no 2 Issue 30: 158-163.
- [8] Alireza Abdollahi. Differentiation of Granulomatous Prostatitis from Prostate carcinoma: Iranian Journal of Pathology 2008-3(4): 208-212.
- [9] Dr. Mandakini B T, Dr Abdul Hakeem, Dr. Zeenath B, Dr. Moinuddin M. A Rare case of Granulomatous Prostatitis: International Journal of Pharmaceutical and Biological Research 2013; vol.4 issue3: 47-51.
- [10] Shanggar K, Zulkifli M Z, Razack A H. Granulomatous Prostatitis: A reminder to clinicians: Med J Malaysia, March 2010, vol 65 no.1: 21- 22.
- [11] Sebo TJ, Bostowick DG, Farrow GM. Prostatic xanthoma: a mimic of prostatic adenocarcinoma. Hum Path 1994; 25: 386.
- [12] Kelalis PP, Greene LF, Harrison EG. Granulomatous prostatitis. a mimic of carcinoma of prostate. JAMA 1965; 191: 287.
- [13] Murugan Paari, Brown Robert, Zhao Bihong. Non Specific Prostatitis with Prostatic Adenocarcinoma: Indian Journal of Pathology And Microbiology 2010, vol.53 issue 1; 152- 154.
- [14] Keuhnlian JG, Guida PM, Pearce JM, Marshall VF. Experiences with granulomatous prostatitis. J Urol 1964; 91: 173.