

Abutment Options for Compromised situation in Esthetic Zone- Case Reports

Dr. Alka Gupta¹, Dr. Deshraj Jain², Dr. Ajay Sangwan³, Dr. Sneha Chhabra⁴
^{1,2,3,4}, (Prosthodontics and Crown and Bridge, College of Dentistry, Indore/ DAVV, India)

Abstract :

Aim- Whenever there is a loss of single anterior tooth the implant retained prosthesis is a preferred option. However, deficient bone in the region of implant placement restricts this modality. With the advancement of techniques and materials the possibility of successfully restoring such compromised cases with implant retained prosthesis is now possible.

Procedure- Customized/ angulated abutments were planned in the following case reports for implant retained restoration due to either the generalized horizontal bone loss or deficient faciapalatal bone (Barely sufficient bone, Division B-w, as per by Misch and Judy)

Results- These case reports describe the use of customized/angulated abutments for implant retained restorations in the esthetic zone.

Conclusion- Moderate to severe bone loss in anterior region presents a challenging situation to the dentists. Therefore, success is not only defined by osseointegration of the implant, but a harmonious and natural blending of the restoration with the surrounding tissues and dentition. Biological, functional and biomechanical parameters must be examined and potential problems have to be identified preoperatively.

Keywords: Angulated Abutment ,Dental implant, Esthetic Zone,UCLA Abutments

I. Introduction

The esthetics of a maxillary anterior single crown on a natural tooth is often one of the most difficult challenges in the restorative dentistry [10]. It is even greater on an implant abutment because the bone is lost first in faciapalatal width, the greater width of implants in this dimension would require bone augmentation. Bone osteoplasty, additional surgical or prosthetic steps and components with varied emergence profiles or angled/customized abutments are often required to render the illusion of a crown on an abutment. Angled abutments are used only to improve the path of insertion of the prosthesis or the final esthetic result (e.g. facially oriented anterior implants). They are often provided in 15- 30 degree angles. The angled abutment, which is loaded along the abutment axis, will transmit a significant moment load to both implant crestal region and abutment screw, proportional to its angle of inclination. As angle increases resistance to fracture decreases because of increased angular load and decreased metal thickness lateral to abutment fixation screw.

Another option is custom abutment which may be fabricated at any length or angulations, though more than 30 degree angulation is not recommended. The esthetic improvement is associated with improved peri implant emergence profile. In addition, appropriately contoured abutments can reduce the likelihood of complications associated with residual luting agent by improving cement margin accessibility [1]. Angulated abutment systems can be supplied as one piece, two piece or three piece. One piece abutment is the abutment of choice for multiple abutments but when angled it is mostly threaded to a wrong direction. Two piece abutment are mostly recommended for single tooth implants and are used as angled abutments [10]. If there is no correlation between the angle of the implant and the flat surface of the internal hex of the implant then select the three-piece. Considerable technical innovation, feasibility and financial investment are required for its use. To allow more versatility in overcoming deeply placed implant and/or angulation and esthetic problems, castable plastic patterns (UCLA abutments) were advocated by Lewis [2] that facilitated integration of the restoration with the abutment [3]. Abutments with customized periimplant emergence form can be fabricated from casting of modified UCLA abutment using lost wax technique by additive methods of waxing and casting [4] or by CAD/CAM technology. By CAD/CAM systems implant abutment can be made using metals such as titanium and titanium alloy and ceramics such as aluminum oxide or zirconium oxide [5,6]. The primary advantage of a cast custom abutment is that it is made specifically for the patient's individual tooth that the corresponding implant replaces [7]. The custom abutment is generally contoured like the preparation of the missing tooth and is thus inherently antirotational. The gingival transition of the custom abutment begins at the implant platform. Therefore, the emergence profile is confluent from the implant to the abutment and to the crown in both the vertical and occlusal planes [8].

II. Case Reports

Case 1: A 53 year old male patient reported to Department of Prosthodontics, with the chief complaint of missing central incisor in the upper left quadrant. The tooth was root canal treated 6 years back and eventually got crown part fractured 6 months back leading to subsequent extraction of root stump. On clinical examination it was observed that the cervicoincisal length of adjacent right central incisor was more as compared to normal length due to recession (Fig.1). For evaluation of availability of bone the OPG was done (Fig.2), showing generalised horizontal bone loss at the alveolar crest region Division B-w (width 2.5 - 4mm wide, by Misch and Judy). Alginate impressions (Algitex Dental Products of India, Mumbai, India) of upper and lower arch were made and poured to get diagnostic casts. The treatment options given to the patient included fixed partial denture, removable partial denture and implant supported prosthesis. The patient wanted fixed replacement of the tooth without involving his adjacent teeth and desired an implant prosthesis. On evaluation of radiographs and diagnostic cast a two stage surgery was planned, an implant of diameter 3.5 mm and length 11.5 mm (Adin, Dental Implant Systems Limited, Israel) was selected. Accordingly a clear acrylic resin surgical template was made on the diagnostic cast which allowed the proper access to the osteotomy site in terms of position, angulation mesiodistally and labiolingually using model based technique of surgical template fabrication (Fig. 3). The ideal angulation for implant insertion is determined on the diagnostic wax up, and the template should relate this position during surgery. A hole was drilled into the planned implant site and a 2mm wide tube was placed around the bur and stabilized with wax and surgical template of clear acrylic fabricated.

The patient was educated to use an aqueous 0.2% chlorhexidine mouth rinse for 1 minute, 3 times daily for 2 weeks for oral disinfection before implant placement. One hour before surgery, the patient took antibiotics (amoxicillin 500 mg, 2 tablets). Surgical protocols of sterilization and disinfection were followed. After the administration of local anesthesia an incision was given crestally. A mucoperiosteal flap was elevated to expose the alveolar crest and surgical template was used for initial osteotomy with 2mm pilot drill. The implant of diameter 3.5 mm/ length 11.5 mm was placed using strict protocol of drill sequence. An IOPA X ray was done to confirm the position of the implant (Fig.4,5). Cover screw was placed and the surgical site was closed with sutures (Vicryl 3-0) and removable partial denture was adjusted at the intaglio surface (Fig.6). The patient was instructed to wear it as less as possible to prevent the possible complication of incision line opening and should not be worn at night. Patient was given prescription for chlorhexidine gluconate and salt water rinses and written postoperative instructions such as adequate rest, application of cold pack (ice) and precautions to be taken to prevent bleeding, suture line opening and pain. After 10- 14 days patient was recalled and the sutures were removed. To expose the implant platform, 4 months later the second stage surgery was performed and cover screw was removed and healing cap was placed to develop the required emergence profile. Three weeks later healing cap was removed which showed healed gingival cuff (Fig.7). To get the implant level impression closed tray technique followed and impression coping was placed. The position of the impression coping was verified with the IOPA radiograph (Fig.8). Addition silicone impression material (Aquasil Ultra- Dentsply, USA) was used for making the impression. The impression coping was retrieved from the implant and joined together with implant analog and seated back in the impression (Fig.9). The impression was poured in die stone and the cast was made using esthetic gingival mask in the implant area. Custom UCLA abutment was planned as abutment option considering the increased inter arch space available with respect to missing tooth and angulation of the implant. The abutment shape was waxed up around the plastic pattern of the UCLA abutment. Wax was added to get emergence profile and desired contour. Customized abutment was placed on the implant analog (Fig.10) and metal ceramic crown was made. The healing cap was removed and customized abutment was placed with 20 Ncm using a torque device and a large hex driver tip (Fig.11). The screw access hole was filled with putty and the metal ceramic crown was cemented with a non eugenol temporary cement (Rely X Temp NE, 3M ESPE, United States). Because of the precise fit between the individualized abutment and the metal ceramic crown, only a minimal amount of cement was needed to place the crown. To date, the restoration has been in service for 24 months without complications (Fig.12,13).

Case 2: A 25 year old male patient reported with the history of trauma 6 years back followed by replantation of the tooth. The tooth underwent internal resorption and hence was extracted. On clinical examination, evaluation of diagnostic cast and OPG there was bone loss both cervico apically and mesio distally (Fig.14). Implant of 3.5 mm diameter and 13mm length (Nobel biocare-Replace select) was selected and surgical template was fabricated using model based technique. Implant was placed using pilot drill followed by sequential use of osteotome and was reinforced by bone graft around the implant. Postoperative IOPA X ray was taken (Fig.15). The patient was given a removable partial denture during the healing period. After 4 months second stage surgery was done, healing abutment was placed for a period of three weeks. Final impression was made using closed tray technique with rubber base impression material and poured. Angulated abutment of 25 degree was selected and modified according to the clinical condition to get the desired emergence profile. The pink porcelain was used to match the adjacent central incisor (Fig.16). An IOPA X ray was taken to check proper fit

of the abutment (Fig.16) and prosthesis was cemented in place. To date, the restoration has been in service without complications (Fig.17,18).

III. Discussion

The esthetic zone of the premaxilla often requires both hard (bone and teeth) and soft tissue restoration. In compromised situations where bone height or width is deficient at the osteotomy site, implant has to be placed more apically or palatally, various treatment options are available to rehabilitate such cases. The most common approach is to modify the narrower division B ridge into another bone division by crestal osteoplasty. Bone augmentation in Division B bone can be done by narrow osteotomy made between the bony plates and bone spreader tapped into edentulous site with subsequent placement of bone graft material (e.g autogenous or demineralized freeze dried bone, synthetic bone substitutes). In the severe cases on lay particulate autogenous graft covered with a membrane for guided tissue regeneration may be required but that needs additional surgical intervention and are expensive. Narrow diameter root form implants with sufficient length may be used but they transfer greater stress to the crestal bone. Thus to avoid additional surgical procedures angulated / Customised abutments may be used. Proper examination, diagnosis and treatment planning, are necessary for esthetic and functional success of anterior single-tooth implants. To achieve prosthetically desired parallelism between implants or teeth, the clinician can place an angled abutment. Angulations of as much as 15 degree are easy to correct with pre angled components. Greater angulation correction may be possible with either pre angled parts or custom made components. The clinician has the choice of either prefabricated or customized abutments. While standard sizes and dimensions are sufficient for posterior restorations, their application in the anterior maxilla may not lead to an optimal esthetic final result. If support of the surrounding tissues is the primary objective, custom made abutments may be necessary for each individual situation[9]. Typically, dentists select either stock or cast custom abutments for implant restorations. A major disadvantage of stock abutments is related to their shape. Most are cylindrical in configuration for the entire length of the component because of which anti rotational facets has to be incorporated by the dentist himself. The custom abutment is generally contoured like the preparation of the missing tooth and is thus inherently anti rotational. A higher placed abutment decreases the amount of crown above the implant abutment, and also provides increased cement resistance and less torque on the cemented region [10]. In comparison to stock abutments, custom UCLA abutments provide better potential than for ideal crown contours and peri-implant soft tissue support leading to optimal esthetic results. A high success rate was reported (4 years: 95.8%). S. Lewis [7].

S. Lewis, J. Beumer reported in a study of 24 months that, 17 patients with 45 implants were restored using the UCLA abutment. No excessive bone loss, fracture of implant components or restorations, or clinical signs of electrogalvanism or electrolytic corrosion have been noted. All patients remained completely asymptomatic. Several soft tissue, hard tissue and implant surgical procedures are required to obtain an ideal result [5].

IV. Figures And Tables

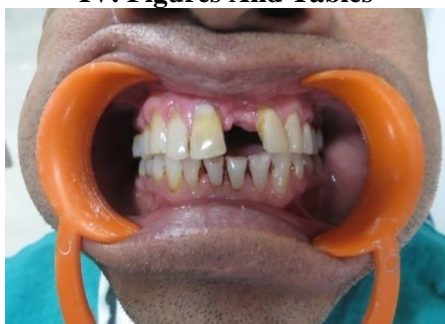

Fig.1 Intraoral picture showing increased cervicoincisal edentulous space in left upper central incisor (Case 1)

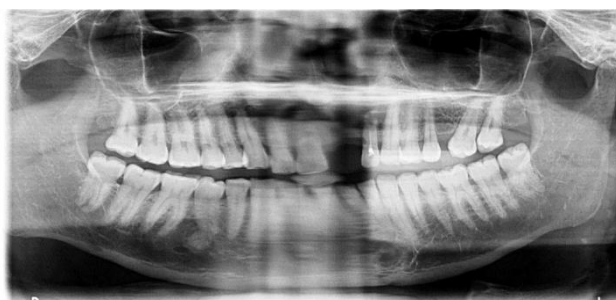

Fig.2 Orthopantogram showing missing left upper central incisor (Case1)

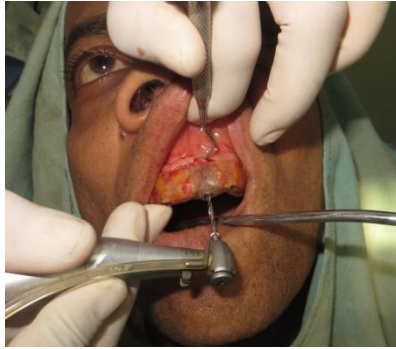

Fig.3 Pilot drill with surgical template (Case1)

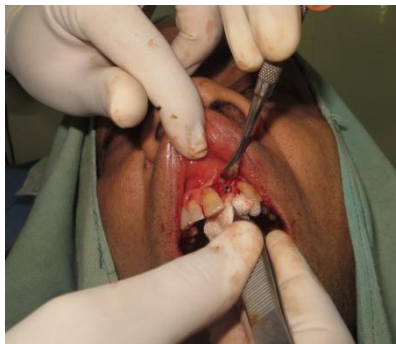

Fig.4 Implant placed at prepared osteotomy site (Case1)

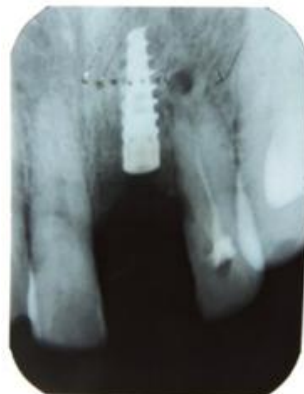

Fig.5 IOPA showing the position of implant (Case1)

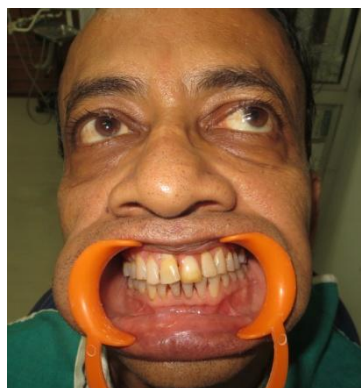

Fig.6 Removable partial denture adjusted after implant placement (Case1)

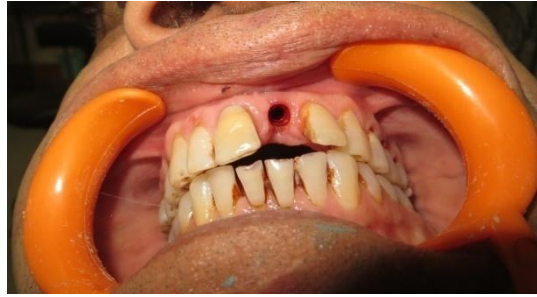

Fig.7 Healed gingival cuff for emergence profile (Case1)

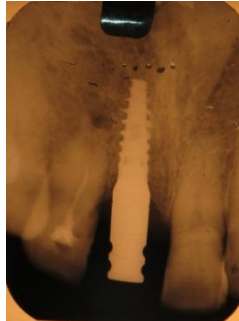

Fig.8 Position of the impression coping verified with IOPA radiograph (Case1)

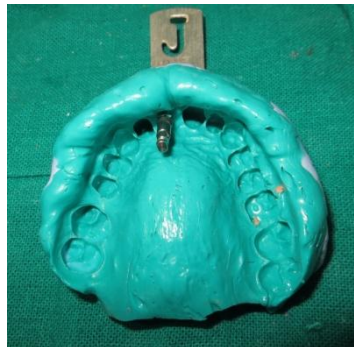

Fig.9 Implant level impression using closed tray technique showing impression coping and implant analog (Case1)

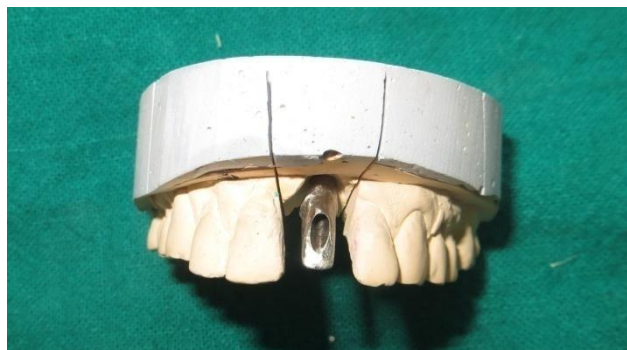

Fig.10 Customised cast abutment using UCLA abutment with gingival mask (Case1)

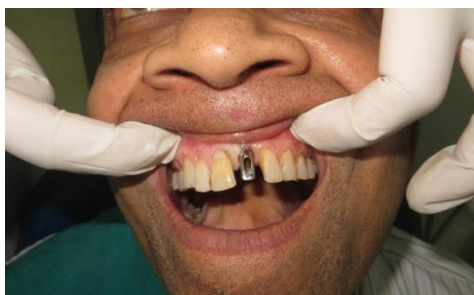

Fig.11 Patient with customised abutment (Case1)

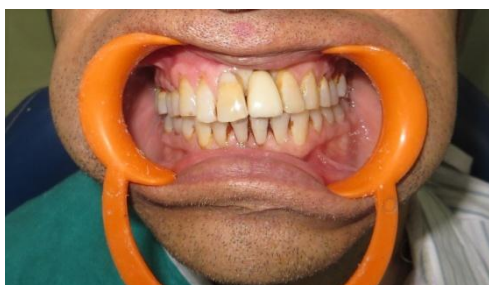

Fig.12 Definitive prosthesis in place (Case1)

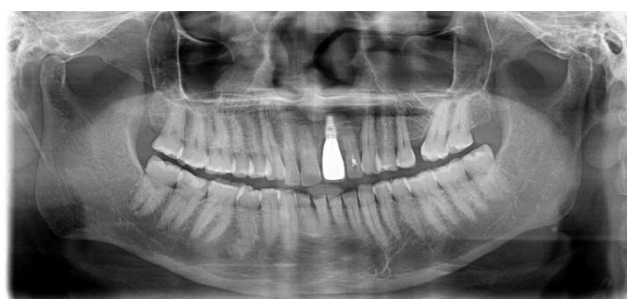

Fig.13 Postoperative IOPA after 2 years of follow up (Case1)

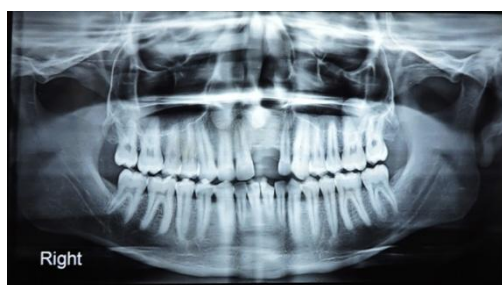

Fig.14 Preoperative Orthopantogram X ray (Case 2)

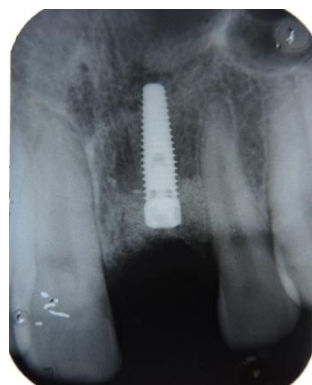

Fig.15 IOPA X ray with implant (Case 2)

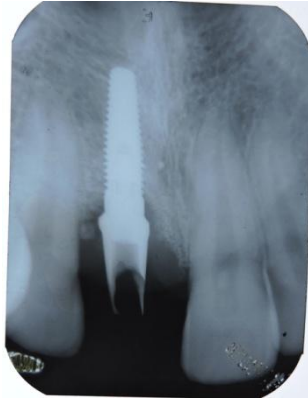

Fig.16 IOPA X ray with modified angulated abutment (Case 2)

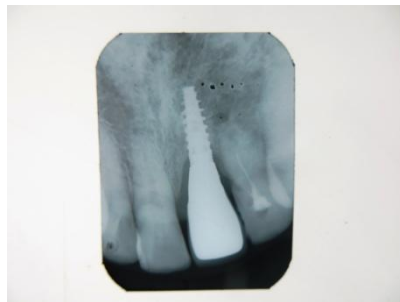


Fig.17 IOPA X ray with prosthesis in situ (Case 2)




Fig.18 Rehabilitated patient (Case 2)

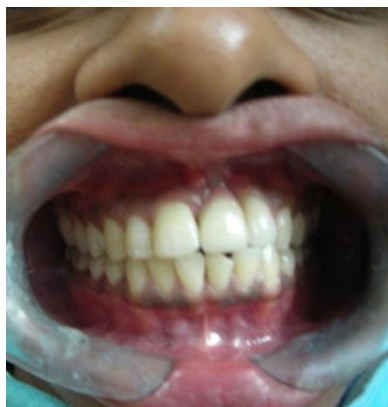

Fig.19 Prosthesis in situ with pink porcelain close up view (Case 2)

V. Conclusion

The anterior implant is successful only if the final restoration is fully integrated within the adjacent dentition. Angled abutments no doubt result in increased stress on implants and adjacent bones but they are within physiologic limits. Customized UCLA implant abutments may be treated like natural abutment teeth and provide excellent esthetic and functional properties for long-term clinical success. These abutment options allowed esthetic restorations to be finished in close proximity to the implant head, overcoming many esthetic dilemmas.

References

Journal Papers:

- [1]. Guess PC, Att W, Strub JR, Zirconia in fixed implant prosthodontics. Clin Implant Dent Relat Res 2012; 14:633-45.
- [2]. Glauser R, Sailer I, Wohlwend A, Studer S, Schibli M, Scharer P, Experimental zirconia abutments for implant-supported single-tooth restorations in esthetically demanding regions: 4-year results of a prospective clinical study. Int J Prosthodont 2004; 17:285-90.
- [3]. Declan Byrne, Frank Houston, The fit of cast and premachined implant abutments. J Prosthet Dent 1998; 80:184-92.
- [4]. Priest G, Virtual-designed and computer milled implant abutments. J Oral Maxillofac Surg 2005; 63: 22-32
- [5]. Lewis S, Beumer J 3d, Hornburg W, Moy P. The "UCLA" abutment. Int J Oral Maxillofac Implants 1988; 3:183-9.
- [6]. Yildirim M, Edelhoff D, Hanisch O, Spiekermann H, Ceramic abutments - a new era in achieving optimal esthetics in implant dentistry. Int J Periodontics Restorative Dent 2000; 20:81-91.
- [7]. Lewis SG, Llamas D, Avera S, The UCLA abutment: A four-year review. J Prosthet Dent 1992; 67:509
- [8]. Papazian S, Morgano SM, A laboratory procedure to facilitate the development of an emergence profile with a custom implant abutment. J Prosthet Dent 1998; 79:232
- [9]. Stefan Holst, Markus B. Blatz, Prosthodontic Considerations for Predictable Single- Implant Esthetics in the Anterior Maxilla. J Oral Maxillofac Surg 2005;63:89-96, Suppl 2

Books :

- [10]. Carl.E.Misch, Contemporary implant dentistry 1993, 3rd edition (Elsevier Health Sciences)