

## Synchronous Papillary Carcinoma of Thyroglossal Duct Cyst and Thyroid managed by a Single Transverse Neck Incision – A Case Report

Sam Scaria<sup>1</sup>, Sivaprasad Pallikkara Vadakke Madamana<sup>1</sup>, Terence Basil Culas<sup>2</sup>

<sup>1</sup>(Final year MBBS student, Government Medical College, Thrissur, India)

<sup>2</sup>(Professor of Surgery, Government Medical College, Palakkad, India)

---

**Abstract:** A rare case of synchronous papillary carcinoma of thyroglossal duct cyst (TGDC) and thyroid gland in a 27 year old lady is presented here. After confirming the diagnosis, total thyroidectomy with appropriate lymph node dissection and excision of the thyroglossal duct cyst including middle third of hyoid bone and excision of the duct up to foramen caecum was done through a single cosmetic neck incision. Post-operatively, radioactive iodine therapy was given for ablation of residual tumor. Follow up till 18 months after the surgery showed no evidence of recurrence.

**Keywords** - single cosmetic neck incision, synchronous papillary carcinoma, thyroglossal duct cyst

---

### I. Introduction

Thyroglossal duct cyst (TGDC) is a rare disease affecting 7 % of the population [1]. TGDC represents a persistence of the tract which descends early in fetal life from the base of the tongue towards its position in the lower neck. The prevalence of carcinoma in the excised cysts is 1-2% [2-5], of which the first case was reported by Uchermann [6]. The incidence of primary thyroid carcinoma, synchronous with TGDC carcinoma has been reported to be between 11 and 33% [5,7,8].

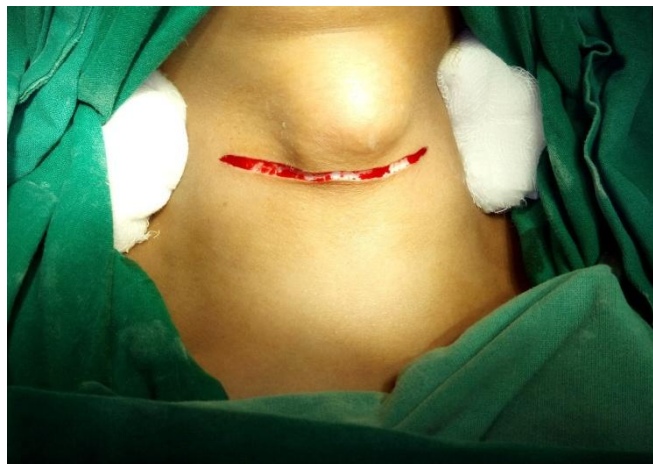### II. Case Report

A 27 year old lady presented to the OPD with a swelling in the upper part of front of neck, which was increasing during the last 3 to 4 years. The swelling was present since birth. Examination revealed an oval swelling of 3×2 cm size, which moved with deglutition. Her thyroid function tests were normal. An ultrasound evaluation revealed a swelling in upper part of neck of dimension 3×2.8×2 cm, showing micro-calcification with increased vascularity indicating the possibility of malignancy in the TGDC. The thyroid showed focal lesions of 9×8 mm and 7×6.5mm in the right and left lobes respectively. Fine needle aspiration cytology (FNAC) of both the TGDC and thyroid lesions revealed papillary pattern clusters including 3-D clusters and individual cells having moderate amount of eosinophilic cytoplasm and round nuclei with powdery chromatin. Nuclear overlapping and grooving were noted. A diagnosis of papillary carcinoma in both TGDC and thyroid gland was made [9]. X-rays of skull and chest appeared normal.

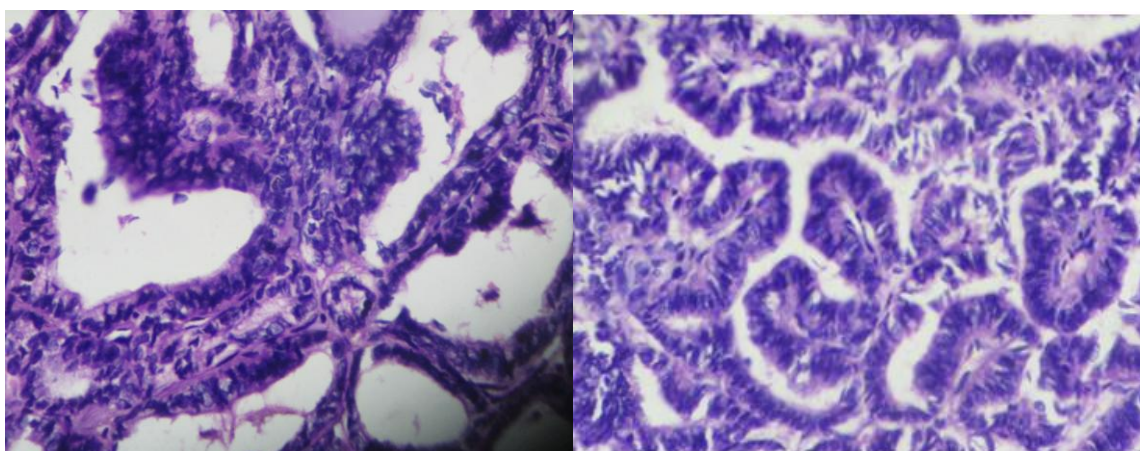
After proper pre-operative evaluation, and after obtaining written informed consent, the patient was taken up for surgery. Under general anesthesia, with the patient supine and the neck extended, an incision was made horizontally over the upper skin crease, approximately 5cm above suprasternal notch (Fig.1). The upper flap was raised up to the upper border of thyroid cartilage. Thyroglossal duct was exposed completely, middle third of hyoid bone excised, and the duct was removed up to foramen caecum along with a rim of adjacent tissue as described by Sistrunk [10]. The lower flap was then raised and total thyroidectomy was done, preserving the recurrent laryngeal and external laryngeal nerves bilaterally along with parathyroid glands. And then, level VI lymph node dissection was done. Blood loss was minimal and the wound was closed with interrupted non-absorbable sutures. Post-operative recovery was uneventful.

Histopathological examination of the excised TGDC and thyroid gland showed thyroid tissue with neoplasm composed of papillary structures lined by cuboidal cells having moderate amount of cytoplasm and ground glass nucleus, confirming papillary carcinoma in TGDC and both the lobes of thyroid gland (Fig.2). None of the lymph nodes showed any deposits. After discharge, the patient was referred to nuclear medicine center for the ablation of residual thyroid with radioactive iodine therapy. She was then placed on replacement dose of thyroxine.

Follow up with thyroid function tests, thyroglobulin assay and nuclear scans up to 18 months revealed no abnormality.



**Figure.1** Single cosmetic neck incision along lower skin crease



**Figure.2** Histopathological examination showing papillary carcinoma in thyroid (left) and TGDC (right)

### III. Discussion

A rare case of synchronous papillary carcinoma of TGDC and the thyroid gland is being reported here. The authors seek to emphasize that in every case of TGDC, ultrasound examination should be done to confirm the presence of normal thyroid tissue and to explore the possibility of malignancy. FNAC of the suspected lesion can be used to confirm the presence or absence of papillary carcinoma. In the presence of synchronous carcinoma, complete excision of TGDC, total thyroidectomy and appropriate lymph node dissection can be accomplished through a single cosmetic incision.

### References

- [1]. Allard RHB, The thyroglossal cyst, *Head Neck Surg.* 5, 1982, 134–136
- [2]. Heshmati HM, Fatourehchi V, van Heerden JA, Hay I.D, Goellner JR, Thyroglossal duct carcinoma: report of 12 cases. *Mayo Clinic Proceedings.* 72(4), 1997, 315–319.
- [3]. Zivaljevic V, Bozic V, Papillary Carcinoma in a Thyroglossal Duct Cyst. *Acta chir belg.* 106, 2006, 252-253
- [4]. Balalaa N, Megahed M, Ashari MA, Branicki F, Thyroglossal Duct Cyst Papillary Carcinoma. *Case Reports in Oncology.* 4(1), 2011, 39-43. doi:10.1159/000324405
- [5]. Weiss SD and Orlich CC, Primary papillary carcinoma of a thyroglossal duct cyst: Report of a case and literature review. *Br J Surg.* 78, 1991, 87–89
- [6]. Uchermann H, Otolaryngologischer Verein in Christiania. *Int Centralbl Laryngol Rhinol Verwandte Wissenschaften.* 31, 1915, 97
- [7]. Park MH, Yoon JH, Jegal YJ, Lee JS, Papillary Thyroglossal Duct Cyst Carcinoma with Synchronous Occult Papillary Thyroid Microcarcinoma. *Yonsei Medical Journal.* 51(4), 2010, 609-611.
- [8]. Aravind R, Neville JF, Senthilkumar R, Malignant thyroglossal duct cyst with synchronous occult thyroid gland papillary carcinoma. *Indian Journal of Endocrinology and Metabolism,* Vol. 17, No. 5, 2013, 936-938
- [9]. Yang YJ, Haghiri S, Wanamaker JR, Powers CN. Diagnosis of Papillary Carcinoma in a Thyroglossal Duct Cyst by Fine-Needle Aspiration Biopsy. *Archives of Pathology & Laboratory Medicine.* 124:1, 2000, 139-142
- [10]. Sistrunk WE, The surgical treatment of cysts of the thyroglossal tract. *Ann Surg.* 71, 1920, 121–122.