

Effect of *Tamarindus indica* (Linn) on the Rate of Wound Healing in Adult Rabbits

M. O. Attah¹, H. B. Ishaya, M. S. Chiroma, D.S. Amaza, S. U. Balogun² and
T.W. Jacks

(Department of Human Anatomy, College of Medical Sciences University of Maiduguri, P.M.B. 1069,
Maiduguri, Borno State, Nigeria)

(Department of Human Anatomy, Kogi State University, Anyigba, P.M.B. 1008, Anyigba, Kogi State, Nigeria)

Abstract: This study was undertaken to determine the effect of tamarind fruit paste on the rate of wound healing. A total of ten rabbits were used for the experiment. These were divided into two groups of five rabbits each. Square wounds were made at the lumbar region of each rabbit and to the wounds of the rabbits in group 2, approximately 5ml of tamarind paste was applied; nothing was applied to the wound of animals in group 1 which served as the control group. The wound in each animal was measured daily by using a vernier caliper and tracing paper for a period of 21 days. The wound areas were approximated by using fine graph paper and by counting the number of square millimeters within the traced areas. Tissue samples were also collected from the wound area at the end of the experiment and processed for routine histological analysis and morphometric measurements. The results showed that wounds treated with tamarind showed a faster rate of wound closure compared to the control group. It was concluded that tamarind fruit paste may play a role in wound healing by accelerating wound closure and increasing epithelial migration and re-epithelialization.

Keywords: Epithelial migration, Rabbits, Re-epithelialization, *Tamarindus indica*, Wound healing.

I. Introduction

A wound can be defined as bodily injury caused by physical means resulting in disruption of normal continuity of structures [1] Wound healing is a complex and dynamic process of restoring cellular structures and tissue layers after destruction. Globally, every person will experience some type of wound in his/her lifetime. Most wounds are due to small injuries and may heal quickly, requiring very little attention. However, many people suffer from chronic or complex wounds that can be very difficult to heal and may cause severe pain and hardship. The part mostly affected is the skin, an organ with well understood functions that ideally should be restored [2] International statistics giving the full picture of the prevalence, disability and impairment of wounds, burns and lymphedema are difficult to acquire [2] however, wound and tissue injury is one of the commonest causes of hospitalization in non-diabetic patients living in sub-Saharan Africa [3]. A wound can significantly affect a person's life and can lead to long periods of pain, discomfort and possibly disability [2] a non-healing wound may become infected if healing is prolonged. Such complex and chronic wounds can lead to complications which may lead to pain, discomfort, limb amputation which has psychological as well as economic ramifications [2] the ultimate goals of wound management are the prevention of wounds, followed by the halting of wound deterioration to achieve rapid healing and prevention of wound-related disabilities. Surgery and pharmacotherapy are the two main approaches used in the treatment of chronic skin ulcers [4]

Tamarindus indica has for a long time played a prominent role in primitive and modern medicine [5] tamarind preparations are universally recognized as refrigerants in fevers and as laxatives and carminatives. In native practice, the pulp is applied for inflammation, gargle for sore throat, to alleviate sunstroke and alcohol intoxication [5] its bark are also masticatory [6].

From available literature, there is no known experiment conducted to determine the effect of *Tamarindus indica* on superficial wound closure. However, related studies have been carried out to determine the effect of tamarind seed polysaccharide (TSP) on the repair of corneal wounds and it was discovered that TSP has a positive effect on cellular adhesion, thus promoting rapid healing [7]. The objective of the present study is to investigate the effect of tamarind fruit pulp on wound healing in rabbits.

II. Materials And Methods

2.1 Preparation of the Paste

The fruit pods used were obtained from the local market and were properly shelled, and a paste was obtained by soaking 50g in 100ml of water. The paste was then strained to remove loose fibers and debris. The paste was refrigerated to prevent fermentation. A fresh paste was prepared every three days.

2.2 Experimental Animals

Ten healthy rabbits weighing between 1.0-2.0kg were obtained from the local market. The animals were housed in adequately ventilated cages and were allowed to acclimatize for a period of two weeks before the commencement of the study. They were fed with carrot leaves, cabbage, dried groundnut leaves and water ad libitum. The animals were further treated against bacterial infection with Ivermectin (Kepromec[®]), and long acting Oxytetracyclin (terramycin L.A[®]) at the dose of 1mg/kg and 20mg/kg using subcutaneous and intramuscular routes, respectively.

2.3 Preoperative Procedures

The preoperative procedures were carried out in the surgical theatre of the small animal clinic, Department of Veterinary Medicine, University of Maiduguri. The surgery was supervised by experts. Each animal had the skin on the dorsal lumbar region shaved and cleaned with antiseptic. Ketamine hydrochloride (7.5mg/kg) and Xylazine hydrochloride (0.15ml/kg) were used to induce and maintain the subconscious state. Diclofenac (1mg/kg) was used for analgesia and procaine penicillin (50,000IU/kg) was used as prophylaxis against infection. All these injections were administered by an intramuscular injection to the left thigh of each animal.

2.4 Operative Procedures

The operative procedure previously described by [8] as modified by [9] and [4] was adopted. The fur from the lumbar region was shaved using a pair of sharp scissors and then a razor blade. A template with a square area of 7.5cm² (3.0cm x 2.5cm) was created using a piece of cardboard paper. This template was placed on the shaved region and traced to ensure that the wound area was not exceeded. An incision was made on the skin, extending to the fascia along the traced skin. The skin was then removed using a pair of dissecting scissors and forceps. The area around the wound was swabbed with antiseptic to ward off flies.

2.5 Post-Operative Procedures

A teaspoon (about 5ml, which contains about 2.5g of tamarind fruit pulp) of tamarind paste was applied topically once daily to the wound area of the animals in group 2. This treatment continued until the scab fell off on post-surgical day [13]. Nothing was applied to the wound area of the animals in group 1. Diclofenac (1mg/kg) was used for analgesia and procaine penicillin (50,000IU/kg) was also given intramuscularly for the first three days. The wound area was swabbed twice daily with antiseptic to ward away flies. The wound areas of the animals were measured every other day with a vernier caliper and later with tracing paper when the wound edges started to contract. This method was adopted from [8], [9] and [4]. At the end of 21days, an average measurement determined for each group and the results were tabulated. The rate or wound healing was calculated for each group and a graphical representation of his information was made using Microsoft Excel. Tissue samples were obtained from the healed region, twenty one days after surgery. The tissue samples were fixed in 10% formalin and processed for routine histological analysis.

2.6 Tissue Measurements with the Micrometer

Several parameters were measured on the slides using an ocular micrometer, which had been previously standardized by a stage micrometer for the different objective magnification used. The thickness of the four layers of the epidermis, the thickness of the dermis and the epidermis, the diameter of collagen fibers and the length and diameter of the fibroblasts were parameters that were measured on the slide.

III. Result

The graphical representation of the rate of wound healing in both groups showed that there was an increase in the wound area of animals in both groups on Post Surgery Day (PSD) 2 which was even more marked in group 2. The wound area of both groups showed a rapid decrease especially in PSD 3-15. There was also a period of rapid wound closure in group 2 on PSD 3-15 resulting in an overlap of the two lines on PSD 7-11 as can be observed in GRAPH 1. The rate wound closure for the animals in group 2 remained rapid with the line representing this group tending towards the x- axis at the end of the assessment period. TABLE 1 gives the wound area for both groups.

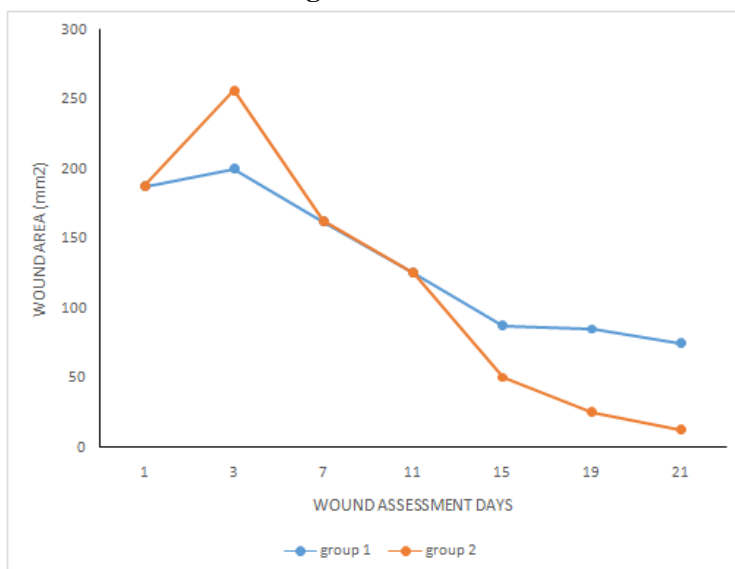
The paraffin sections of group 1 showed a thick epidermis, the different strata of the epithelium could be differentiated: stratum corneum was observed as an irregular layer, stratum granulosum is also observed as a darkly staining region and the cells in stratum spinosum had large and prominent nuclei which is indicative of active protein synthesis. The basal layer was composed of an irregular layer of cells with flattened nuclei (Fig 1) Fibroblasts were scattered within bundles of collagen fibers in the dermis (Fig 2). The measurements of the different layers of the epidermis as well as the components of the dermis are contained in TABLE 2.

Paraffin sections of animals in group 2 showed a thin stratum corneum, stratum granulosum was well defined and the cells found in stratum spinosum had well defined intercellular boundaries and tapering ends. Stratum basale was irregular and had low columnar cells. The layer above the columnar cells were polyhedral in shape. Numerous mitotic figures were also observed. Hair follicles were also seen to erupt in the epidermis (Fig 3). The dermis was packed with fibroblasts and fewer collagen fibers than were found in the dermis of animals in group 1. The cytoplasm of the fibroblasts appeared granular and stained deeply (Fig 4). The measurement of the components of the epidermis and dermis are also found in TABLE 2.

IV. Discussion

The epithelium of animals treated with tamarind paste was thicker and this implied greater epithelial migration and re-epithelialization at the epidermis; compared to animals in the control group. There is also rapid cell division and cellular migration towards the surface of the epidermis. As the epithelium thickens, the cells become more columnar and mitotic activity increases [1]. The dermis is packed with fibroblasts and less collagen fibers compared to group 1. This suggests that treatment with tamarind fruit may be responsible for mobilization of fibroblasts as well as stimulating them to produce collagen. The dermis is also densely packed with deeply staining ground matter which signifies active synthesis of protein, polysaccharides and various glycoproteins that make up the ground substance. Mucopolysaccharides of the ground substance surrounds the fibroblasts and influences the aggregation and orientation of collagen fibers [1]. This serves to increase wound strength. Also, the abundant blood vessels in the dermis of animals treated with tamarind suggests re-growth of blood vessels (angiogenesis).

V. Figures and Tables



Graph 1 comparing the rate of wound healing in groups 1 and 2.

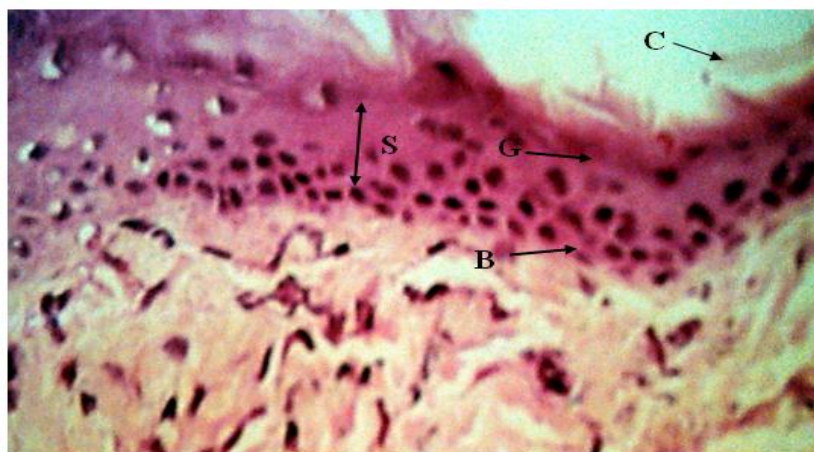


Figure 1; Micrograph of animal from group1 showing the full thickness of the epithelium as well as its strata (C- corneum, G- Granulosum, S- Spinosum, B-Basale) and some part of the dermis. H & E stain X400

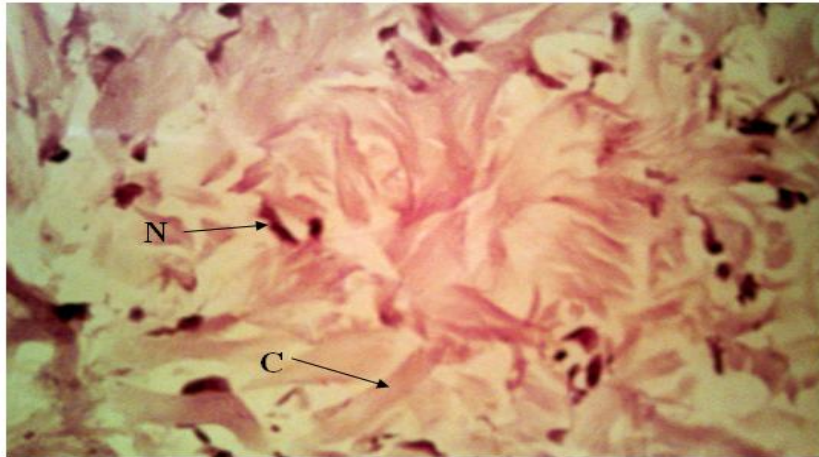


Figure 2; Micrograph of the dermis of animals in group 1 showing fibroblasts nucleus (N) and collagen fibers (C) H&E X400

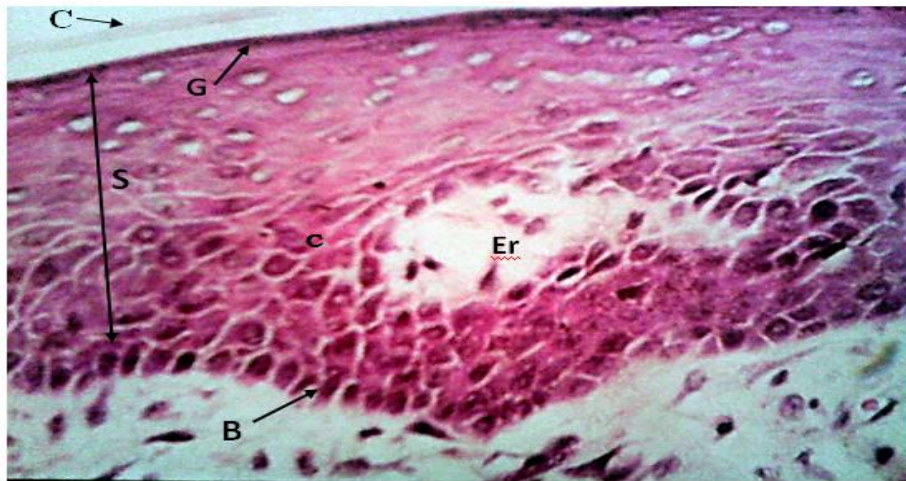

Figure 3; Micrograph of epithelium of animals in group 2 who were treated with tamarind paste showing stratum Corneum (C), Granulosum (G), Spinosum (S) and Basale (B). Also observed is the eruption of a hair follicle (Er) H&E X400

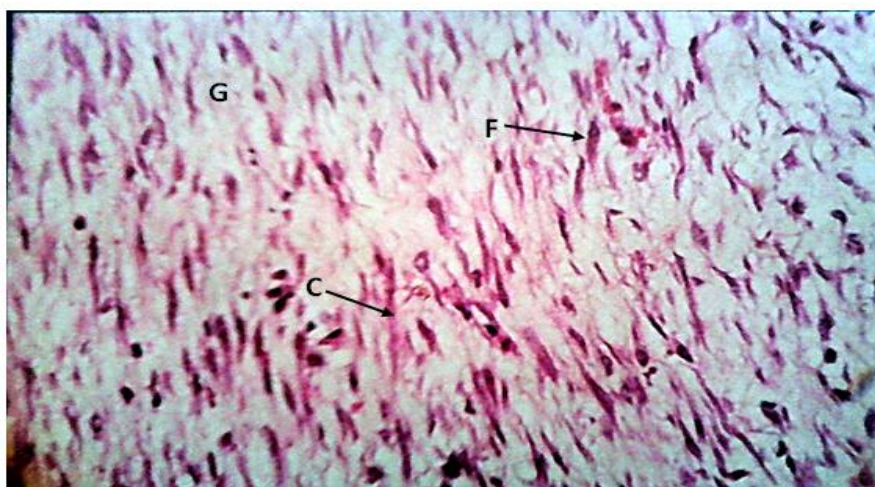


Figure 4; Micrograph showing the dermis of animals treated with tamarind paste showing a dense aggregation of collagen fibers (C) as well as numerous fibroblasts (F). The ground substance (G) is deeply stained. H&E X400

Table 1: Wound areas in Groups 1 and 2.

Post-Surgery Days	Group 1 (wound area in mm ²)	Group 2 (wound area in mm ²)
1	187.5	185.5
3	200	256.25
7	162.5	162.5
11	125	125
15	87.5	50
19	85	25
21	75	12.5

Table 2: Parameters measured on the micrograph

Parameters for Measurement	Group 1	Group 2
Epidermis	109.2µm	145 µm
Dermis	546 µm	1092 µm
Stratum Corneum	-	10.92 µm
Stratum Granulosum	14.5 µm	10.92 µm
Stratum Spinosum	36.4 µm	54.6 µm
Stratum Basale	29.12 µm	76.44 µm
Length of Fibroblast	87.6 µm	29.2 µm

VI. Conclusion

This study was undertaken to investigate the effect of tamarind fruit pulp on wound healing and at the end of the experiment, it was discovered that *Tamarindus indica* facilitated wound healing by increasing the rate of wound contraction and it caused rapid migration of epithelial cells across the wound area. This information is important for treatment of open wounds and ulcers, however, further study is recommended.

References

- [1]. Slatter, H. S., Philadelphia textbook of small animal surgery (W. B. Saunders, Philadelphia, 1985) Vol. 1, pp29-34
- [2]. McDonald, J. and Geyer, (2010) Wound and Lymphoedema Management, World Health Organization Publication, W.H.O. Press, Geneva, Switzerland. pp13-23
- [3]. Onuminya, J. E., and Onuminya, D. S., Results of Open Wound Technique in the Treatment of Post Sequestrectomy Dead Space, South African Journal of Surgery, 46(1), 2008
- [4]. Mawera, G., Mutseekwa, D. and Asala, S. A., Effects of an Ashed (MEND) Powder on Deep Wound Healing: a preliminary Study in Guinea Pigs. East African Journal 74(8) 1994, pp495-498.
- [5]. Morton, J. F., (1958) The Tamarind (*Tamarindus indica* L.) Its Food, Medicinal and Industrial Uses, Florida State Horticultural Society pp203-225.
- [6]. El-Siddig, K., Gunasena, H.M.P., Prasa B.A., Pushpakumara D.K.N.G, Ramana K.V.R., Vijayanand, P and Williams, J.T. (Tamarind-*Tamarindus indica* L. Fruits for the Future. Southampton Center for Underutilized Crops, Southampton, UK, 2006)
- [7]. Burglassi, S., Raimondi, L., Pirisino, R., Bonchelli, G., Boldrini, E. and Saetone, M. F. Effect of Xyloglucan (Tamarind Seed Polysaccharide) on Conjunctiva Cell Adhesion on Corneal Epithelial Wound Healing; European Journal of Ophthalmology, 10(1), 2000, 71-76
- [8]. Kennedy, D. F. and Cliff, W. J. A. (1979) A Systemic Study of Wound Contraction in Mammalian Skin. Pathology. 11:208
- [9]. Horne, R.S.C., Hurley, J.V., Gowe, D.M., Ritz, M., MacO'Brien, B. and Arnold, L. I. (1992) Wound Healing in Foetal Sheep: A Histological and Electron Microscope Study. British Journal of Plastic Surgery, 45:333.