

## Actinomycosis of Tendon Sheath

Nikku Mathew Geevarughese<sup>1</sup>, Edward L Nazareth<sup>2</sup>, Manjeshwar Srinath Baliga<sup>3</sup>, Umashankar T<sup>4</sup>, Bakul Arora<sup>5</sup>, Sam Supreeth<sup>6</sup>

<sup>1</sup> (Junior Resident, Department of Orthopaedics, Father Muller Medical College, India)

<sup>2</sup> (Professor, Department of Orthopaedics, Father Muller Medical College, India)

<sup>3</sup> (Professor And HOD, Department of Research & Development, Father Muller Medical College, India)

<sup>4</sup> (Professor, Department of Pathology, Father Muller Medical College, India)

<sup>5,6</sup> (Senior Resident, Department of Orthopaedics, Father Muller Medical College, India)

---

**Abstract :** Actinomycosis is a chronic suppurative granulomatous disease characterized by multiple abscesses and draining sinuses. It usually manifests as cervico-facial, thoracic or abdominal actinomycosis. Cutaneous actinomycosis is extremely rare. Definitive diagnosis depends upon the clinical triad of painless subcutaneous nodules, sinuses and discharge followed by histological examination. Moreover, treatment can be challenging. Combined antibiotic therapy is preferable to monotherapy to avoid drug resistance and to eradicate residual infection. The purpose of the study was to describe the difficulty in diagnosis and treatment of a rare presentation of actinomycosis of the tendon sheath. A 37 year old male presented with multiple small painless swellings on the great toe. It was initially suspected to be giant cell tumour of the tendon sheath of great toe. However the diagnosis of actinomycosis was made only by histopathology. Two months of oral antibiotics brought the disease under control in this penicillin-allergic patient.

**Keywords** - Actinomycosis, fungal infection, tendon sheath

---

### I. INTRODUCTION

Actinomycosis is a subacute to chronic, suppurative granulomatous disease characterized by induration, multiple abscesses and draining sinuses.<sup>[1]</sup> It usually manifests as cervico-facial, thoracic or abdominal actinomycosis.<sup>[2]</sup> Cutaneous actinomycosis is extremely rare.<sup>[3]</sup> The disease was first reported in humans by Israel in 1878.<sup>[4]</sup> It is most commonly caused by *Actinomyces israelii* in humans. Actinomycosis is an anaerobic, gram positive bacterial infection and exists as a saprophyte.<sup>[5]</sup> Actinomycosis has been called 'the most misdiagnosed disease' even by experienced clinicians, and listed as a 'rare disease' by the Office of Rare Diseases (ORD) of the National Institutes of Health (NIH).<sup>[6]</sup> The purpose of the study was to describe the difficulty in diagnosis and treatment of a rare presentation of actinomycosis of the tendon sheath.

### II. CASE REPORT

We present the case of a 37 year old farmer, who presented with painless small swellings over his left great toe since 5 years. The swellings were insidious in onset, not associated with fever or pain. He attributes his complaints to an injury to his left great toe 5 years back while playing volleyball, though he claims that he did not sustain an open or penetrating injury. He asserts that he had pain and swelling of his first web space lasting for a week, followed by painless residual swellings which did not grow in size. On careful examination, the lateral and plantar aspect of the left great toe appeared lobulated with the skin failing to show any signs of acute inflammation. There were no sinuses or discharge noted. On palpation, non-tender 6 lobules were palpated at the first web space, the largest measuring 1cm x 1cm, and two were palpated on the plantar aspect of the first proximal phalanx. Though extension of the interphalangeal joint was unrestricted, flexion was mechanically but painlessly restricted. Inguinal lymph nodes were not palpable. Haemoglobin and total counts were normal; erythrocyte sedimentation rate and uric acid were also within normal limits. Radiograph of the left great toe was found to show no bone involvement.

On table, a single 8cm x 3cm multi-lobulated mass was identified in the subcutaneous layer encircling the lateral circumference of the left great toe as well as engulfing the lateral digital nerve of the great toe along with the lateral digital artery and vein which had to be sacrificed to excise the mass. The absence of pus and typical presentation of a soft tissue swelling directed our provisional diagnosis towards giant cell tumour of the tendon sheath. After three days of intravenous antibiotics, he was discharged. Histopathologic study of the tissue revealed actinomycosis, substantiated by gram stain and Gomorri Methylamine Silver stain.

After the histopathology report, he was treated with amoxicillin 500mg BD for 15days, followed by oral clindamycin 300mg BD for 5days and oral fluconazole 150mg OD for 20days. One month after surgery, it was noted that he developed a 2cm ulcer over the medial aspect of the left great toe. Local wound care was

given and advised oral fluconazole 150mg OD for 10days. At the conclusion of the therapy, the ulcer healed completely.

### III. DISCUSSION

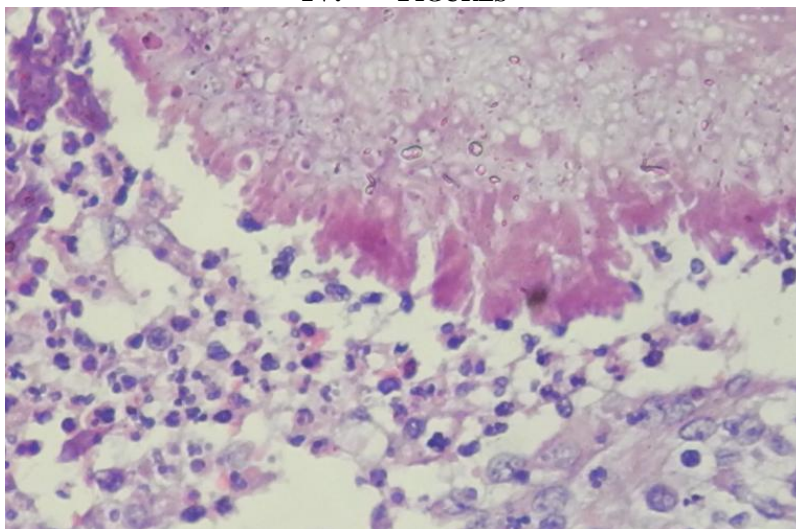
Mycetomas are chronic infections of the skin and subcutaneous tissues that may be caused by true fungi (eumycetoma) or by filamentous bacteria (actinomycetoma). Actinomycetoma are commoner than eumycetoma worldwide and around 75% of mycetomas are actinomycotic in parts of India.<sup>[7]</sup> Actinomycetoma and eumycetoma have the same clinical picture: the affected part, usually an extremity, demonstrates swelling, induration and sinuses that discharge pus with or without granules composed of colonies of the organism.

Actinomyces are non virulent commensal organisms in the oropharynx, gastrointestinal tract and female genitalia, which require a portal of entry to initiate infection.<sup>[8]</sup> The crucial factors for initiation of infection are disruption of the mucosal barrier and alteration of resident microbial flora.<sup>[9]</sup> The male to female ratio of the disease is 3:1, and it usually presents in the fourth to fifth decade of life. Classically, the clinical forms are: cervico-facial (55%), abdomino-pelvic (20%), thoracic (15%), and mixed organ (10%), which includes the skin, brain, pericardium and extremities.<sup>[8]</sup> Primary cutaneous actinomycosis is rare because of the endogenous habitat of the organism.<sup>[10]</sup> Cutaneous localization of the organism occurs by direct inoculation or through hematogenous spread during a septicemic phase of infection.<sup>[11]</sup> It can also occur as a sequelae to human bites and intramuscular injections.<sup>[4]</sup> The skin, subcutaneous tissue, muscle and bone may be involved alone or in various combinations.<sup>[12]</sup> Exogenous cutaneous trauma might have enabled inoculation of bacteria.<sup>[13]</sup>

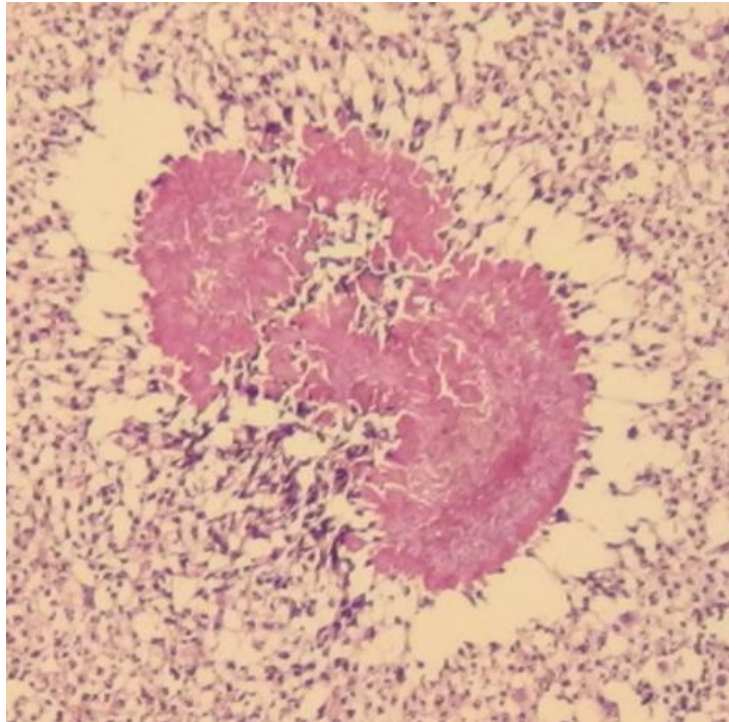
Diagnosis and treatment of actinomycosis is challenging. Definitive diagnosis depends upon the clinical triad of painless subcutaneous nodules, sinuses and discharge followed by histological examination, which shows a diffuse mixed infiltrate with chronic, fistulating, fibrotic and subcutaneous granulation tissue, microabscesses and sinus tract.<sup>[4,14]</sup> Actinomyces appear as gram positive filaments solidified with elements of tissue exudates, resembling a grain of sulfur, which is the diagnostic feature of the infection.<sup>[15]</sup> Correct diagnosis results from specific clinical, microbiological, and histopathological findings.<sup>[16]</sup>

Treatment of mycetomas can be difficult. Eumycetoma may be unresponsive to antifungal therapy. Actinomycetoma respond to antibiotic therapy but prolonged treatment is necessary.<sup>[17]</sup> Several antibiotics have been used in the treatment of actinomycetoma, as they must also include the spectrum of the secondary flora.<sup>[6]</sup> Long-term penicillin therapy has been the classic treatment for actinomycosis, however cotrimoxazole, dapsone, streptomycin, sulfadoxine-pyrimethamine, rifampicin and amoxicillin- clavulanic acid have all been found effective.<sup>[17]</sup> Combined antibiotic therapy is preferable to monotherapy to avoid drug resistance and to eradicate residual infection.<sup>[6]</sup> Several authors recommend a combination therapy including amino penicillins and beta-lactam inhibitors as first-line treatment.<sup>[6,18]</sup> Depending on the synergistic accompanying flora, combination with aminoglycosides or lincosamides could be essential because of their good tissue penetration.<sup>[6,16]</sup> Recently, short-term penicillin therapy has been reported to be effective.<sup>[14]</sup> Numerous other antibiotics including imipenem, chloramphenicol, ceftriaxone, clindamycin, minocycline, doxycycline, macrolides and trimethoprim/sulfamethoxazole have demonstrated an anecdotal clinical efficacy.<sup>[15]</sup> The duration of treatment required to cure actinomycetoma is not clearly defined. Prolonged treatment is recommended to prevent relapses.<sup>[17]</sup>

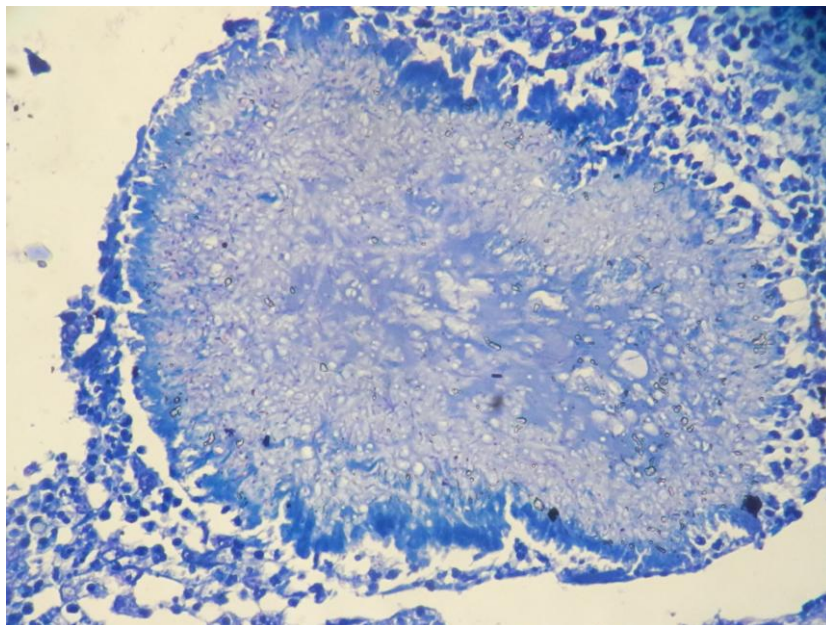
### IV. FIGURES



**Figure 1:** Microscopy revealed bacterial colonies surrounded by amorphous eosinophilic material suggestive of Splendore-Hoeppli phenomenon along with polymorphs and macrophages.



**Figure 2:** Bacterial colonies surrounded by amorphous eosinophilic material suggestive of Splendore-Hoeppli phenomenon.



**Figure 3:** Histopathology of the tissue revealed actinomycosis, substantiated by gram stain.

## V. CONCLUSION

This case report depicts an exceptional presentation of actinomycosis of the tendon sheath of the great toe, the difficulty in diagnosis this ever-elusive condition and the complexity in treating actinomycosis of the tendon sheath.

## REFERENCES

- [1] Sudhakar SS, Ross JJ. Short-term treatment of actinomycosis: two cases and a review. *Clin Infect Dis.* 2004; 38(3):444-7.
- [2] Khandelwal R, Jain I, Punia S et al. Primary actinomycosis of the thigh - a rare soft tissue infection with review of literature. *JRSM Short Rep.* 2012; 3(4):24.
- [3] Metgud SC, Sumati H, Sheetal P. Cutaneous actinomycosis: a rare case. *Indian J Med Microbiol.* 2007; 25(4):413-5.
- [4] Mirza M, Sarwar M. Recurrent cutaneous actinomycosis. *Pak J Medical Sci* 2003; 19(3):230-232.

- [5] Patil D, Siddaramappa B, Manjunathswamy BS et al. Primary cutaneous actinomycosis. *Int J Dermatol.* 2008; 47(12):1271-3.
- [6] Schall KP. Actinomycosis, Actinobacillosis and related diseases. Topley and Wilson's Microbiology and Microbial Infections. 9<sup>th</sup> edition. Vol. 3. Bacterial Infections. Great Britain. Arnold. 1998:777–98
- [7] Chaudhuri BN, Maiti PK, Sil J. Antibiotic sensitivity patterns of actinomycetes isolated from patients of actinomycetoma. *Indian J Med Res.* 1997; 105:162-6.
- [8] Santos JW, Zambenedetti RM, Mann KC et al. Thoracic actinomycosis: report of a patient with advanced-stage disease. *Braz J Infect Dis.* 2007; 11(1):157-9.
- [9] Pulverer G, Schütt-Gerowitt H, Schaal KP. Human cervicofacial actinomycoses: microbiological data for 1997 cases. *Clin Infect Dis.* 2003; 37(4):490-7.
- [10] Roy D, Roy PG, Misra PK. An interesting case of primary cutaneous actinomycosis. *Dermatol Online J.* 2003; 9(5):17.
- [11] Fazeli MS, Bateni H. Actinomycosis: a rare soft tissue infection. *Dermatol Online J.* 2005; 11(3):18.
- [12] Kargi E, Akduman D, Güngör E et al. Primary extremity actinomycosis causing osteomyelitis of the hand. *Plast Reconstr Surg.* 2003; 112(5):1495-7.
- [13] Cocuroccia B, Gubinelli E, Fazio M et al. Primary cutaneous actinomycosis of the forehead. *J Eur Acad Dermatol Venereol.* 2003; 17(3):331-3.
- [14] Bartell HL, Sonabend ML, Hsu S. Actinomycosis presenting as a large facial mass. *Dermatol Online J.* 2006; 12(2):20.
- [15] Stewart AE, Palma JR, Amsberry JK. Cervicofacial actinomycosis. *Otolaryngol Head Neck Surg.* 2005; 132(6):957-9.
- [16] Al-Niaimi F, Patel A, Blessing K et al. Cutaneous actinomycosis presenting as chronic mastitis. *Clin Exp Dermatol.* 2010; 35(2):149-51.
- [17] Ramam M, Bhat R, Garg T et al. A modified two-step treatment for actinomycetoma. *Indian J Dermatol Venereol Leprol.* 2007; 73(4):235-9.
- [18] Smith AJ, Hall V, Thakker B et al. Antimicrobial susceptibility testing of *Actinomyces* species with 12 antimicrobial agents. *J Antimicrob Chemother.* 2005; 56(2):407-9.