

Lateral Incisor Morphology In Patients With Impacted Canine: A CT Study

MU Dr. Ivana Dubovská¹, MU Dr. Jan Heřmánek²,
MU Dr. Wanda Urbanová Ph.D.³, MU Dr. Pèter Borbèly⁴,
MU Dr. Přemysl Krejčí Ph.D.¹, MU Dr. Martin Kotas Ph.D.¹

¹(Institute of Dentistry and Oral Sciences, Faculty of Medicine and Dentistry, Palacký University, Olomouc, Czech Republic)

²(Department of Orthodontics, Faculty of Medicine and Dentistry, Charles University, Hradec Králové, Czech Republic)

³(Department of Orthodontics and Cleft Anomalies, 3rd Medical Faculty, Charles University, Prague, Czech Republic)

⁴(Department of Orthodontics, Private practice, Budapest, Hungary)

Abstract: The aim of the study was to investigate a potential relationship between the lateral incisor morphology and palatal canine impaction on 3D CBCT images. This retrospective study was based on the treatment records of 34 patients with one or both canines palatally impacted and 30 patients without canine impaction. The following morphometric parameters were evaluated in each patient on the upper lateral incisors: crown and root length, length ratio of the crown and root, mesiodistal and labiolingual width at the cemento-enamel junction, and mesiodistal and labiolingual width at the middle of the root. The lateral incisors on the side of the impacted canine are shorter in the group of patients with impaction in comparison with the control group without impaction. The lateral incisor roots on the side of the impaction as well as on the opposite nonaffected side are on average 0.4 mm narrower labiolingually and mesiodistally. Lateral incisor root length is 1.5 mm shorter in patients with unilateral canine impaction than in those with bilateral canine impaction. Major differences were found in lateral incisor root lengths and widths. Lateral incisor roots were on average 0.5 mm shorter and 0.4 mm narrower labiolingually and mesiodistally in the group with impaction than in the control group.

Keywords: CBCT, impacted canine, lateral incisor, root width

I. Introduction

A palatally displaced canine is an orthodontic anomaly with an autosomal dominant trait with low penetrance and variable expressivity. Environmental factors might also play an important role in the aetiology of impacted canines [1].

A dentition with palatally displaced canines is characterised by delayed tooth development [2], their size reduction [3], particularly reduced mesiodistal crown width of maxillary and mandibular incisors [4], morphological anomalies of lateral incisors (small, peg-shaped or missing lateral incisors), and an increased prevalence of third molar and second premolar agenesis [5, 6, 7].

The presence of anomalous lateral incisors in patients with palatally impacted canines was confirmed by many authors [8, 9, 10]. In the general population, 93% of lateral incisors were of normal size and shape. Only 52% of lateral incisors of normal size and shape were present in the patients with palatally impacted canines according to the study of Brin on 2,440 adolescents [10]. Lateral incisor agenesis occurs three times more frequently, small lateral incisors six times and peg-shaped nine times more frequently in the group of patients with impacted canines than in the general population.

The relationship between mesiodistal crown width and root length of the lateral incisor was also confirmed [11, 12]. Small and peg-shaped lateral incisors have a shorter root than those of a normal size.

Teeth smaller in sizes generally exhibit delayed eruption. According to Becker [13], when the lateral incisor root should guide the canine in the beginning of eruption, it is too small for guidance.

The width of the lateral incisor root is another factor that can cause failure of eruption. By using CBCT it is possible to measure not only mesiodistal, but also labiolingual root width. One of the few studies using CBCT was conducted by Liuk et al. [12]. He found significantly narrower labiolingual width of lateral incisor roots in patients with impacted canines. CBCT brings the third dimension to research and makes it possible to investigate the morphology of lateral incisors in patients with impacted canines in all three planes [16]. Moreover, CBCT measurements are more accurate. Now it is possible to investigate the root morphology without distortion and overlapping. The aim of our study was to find potential differences in lateral incisor

morphology in the case of unilateral or bilateral canine impaction and to compare it with lateral incisors in the group of patients without impaction.

II. Materials and Methods

This retrospective study was based on the treatment records of patients who were treated at the Department of Orthodontics and Periodontology. One hundred and eighty-four patients with palatally impacted maxillary canines were identified among the patients seeking orthodontic treatment. CBCT scans were obtained for 52 patients, of whom 34 patients with one or both canines impacted palatally met the selection criteria. To create a control group of patients without canine impaction, eighty-two patients were identified among those undergoing implant therapy in the posterior segment at the Department of Periodontology. Thirty patients met the selection criteria. Patients with a high resolution CBCT scan and proper visible contours of the measured teeth were included in the study. There was no limitation for dental class or skeletal pattern. Patients excluded from the study were those without finished development of the roots of upper incisors and canines, those with a congenital anomaly of hard dental tissues (amelogenesis imperfecta, etc.) or with causeless general root shortening, and those with incisor crown deformation because of a trauma, filling or prosthodontic work. The mean age of the patients with canine impaction was 22.4 years; in the control group it was 28.0 years. CBCT scans were done under the same conditions using the same equipment: CBCT PaX-Duo3D (Vatech & E-WOO). The field of view was set individually for every patient according to the investigated region, most commonly 12 x 8.5 in the Occlusion mode.

Measurements were performed in the Multiplanar Reconstruction. The setting of the coronal and axial planes was through the long axis of the measured lateral incisor (Fig. 1). The tooth length was measured by the "Panoramic curve" function in the sagittal plane (Fig. 2). With this function it is possible to set the beginning and the end of the lateral incisor with good precision.

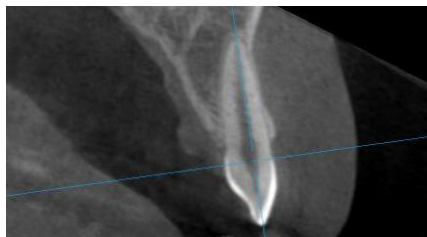


Fig. 1: Setting of the coronal and axial planes through the long axis of the measured lateral incisor.

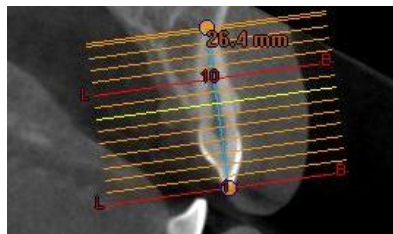


Fig. 2: Tooth length measured by "panoramic curve" in the sagittal plane.

The length of tooth was measured directly from the "panoramic curve" after the incisal and apical borders had been set in axial slices (Fig. 2). The distances between slices were 0.5 mm. The slice of each border was determined as the latest slice into which the lateral incisor was projected. Apical and incisal border establishment and its control are shown in Fig. 3 and Fig. 4.

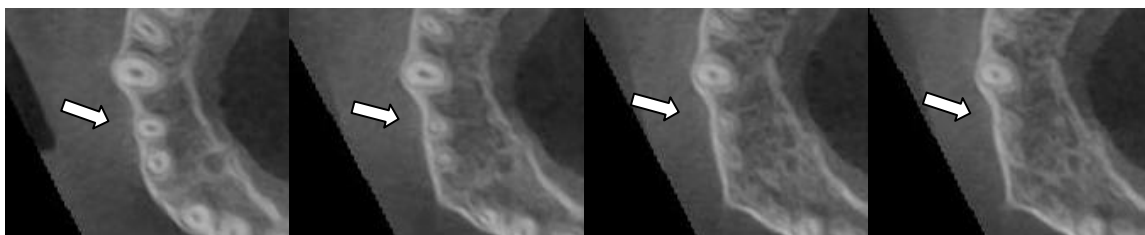


Fig. 3: Apical border establishment and its control.

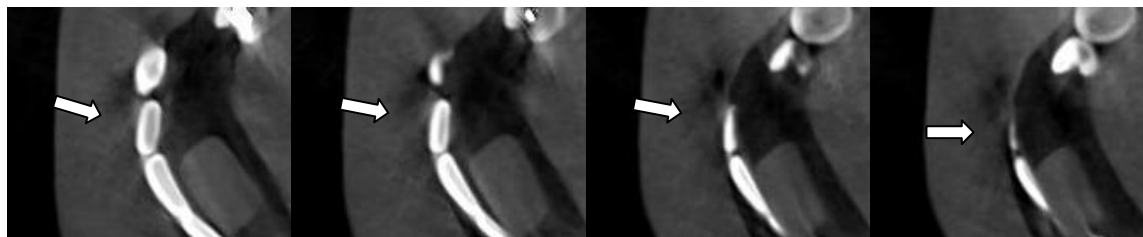


Fig. 4: Incisal border establishment and its control.

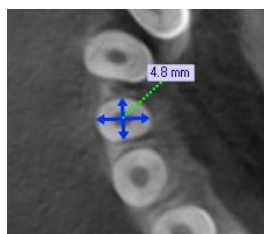


Fig. 5: Measurement of the mesiodistal and vestibulo-oral width at the cemento-enamel junction.

The following morphometric parameters were evaluated in each patient: lateral incisor length, crown length, root length, mesiodistal and labiolingual width at the cemento-enamel junction, and mesiodistal and labiolingual width at the middle of the root. For general teeth size comparison of the canine impaction group and the control group, upper and lower incisors were measured and compared. Statistical analysis was performed by using the Minitab 16 2-sample t-test to compare potential differences in the observed characteristics in intergroup comparison between the group with canine impaction, that with unilateral canine impaction, that with bilateral canine impaction, lateral incisors in the side of impaction, lateral incisors on the opposite side of impaction, and the group of patients without impaction. A paired t-test was used to compare intergroup differences in the lateral incisors on the side of the impaction and on the opposite side. Error of measurement was assessed by the Dahlberg's method [14]. For the measured traits, the error of measurement fluctuated between 0.1 and 0.2 mm.

III. Results

1. There was no significant difference in the general tooth size (dentition size) between the study and the control group as measured on the upper and lower central incisors. There was no significant difference in the central incisor crown and root width or length.
2. Differences in the measured morphometric traits of lateral incisors in the patients with a palatally impacted canine and in the control group without impaction:

Experimental data are summarised in Table 1, which presents the value and significance of intergroup differences. Patients with palatal canine impaction have shorter lateral incisors on the side of the impaction than those in the control group without canine impaction. The average shortening of the lateral incisor crown was 0.5 mm in patients with unilateral canine impaction and 0.7 mm in bilateral canine impaction patients.

In the group of patients with an impacted canine, all upper lateral incisors had on average 0.4 mm narrower roots in the mesiodistal and vestibulo-oral dimensions than those in the group of patients without impaction. There was no difference in lateral incisor width on the side of the impaction and on the opposite side. In the group of patients with bilateral canine impaction, the upper lateral incisor roots were even narrower vestibulo-orally, 0.6 mm on average. In the unilateral canine impaction group, no difference was found in the lateral incisor root width or tooth length depending on the side of the impaction or on the opposite side.

The lateral incisor roots were on average 1.5 mm shorter in connection with the bilateral canine impaction than in the unilateral canine impaction patients. There were no differences in the lateral incisor root widths between the groups with unilateral and bilateral canine impaction.

Table 1: Intergroup differences of the measured signs of the upper lateral incisors: average differences in [mm] and statistical significance (highlighted in red).

			incisor_length	crow_n_length	root_length	CEJ_LL	CEJ_MD	half_LL	half_MD
Ret (+/-)	vs	Con	-1.09 (**)	-0.53 (**)	-0.55 (ns)	-0.25 (**)	-0.26 (**)	-0.44 (***)	-0.39 (***)
Ret (+)	vs	Con	-1.32 (**)	-0.61 (**)	-0.71 (*)	-0.28 (*)	-0.22 (*)	-0.49 (***)	-0.37 (***)
Ret Bi	vs	Con	-2.14 (***)	-0.68 (**)	-1.45 (**)	-0.42 (*)	-0.20 (ns)	-0.57 (**)	-0.35 (**)
Ret Uni (+/-)	vs	Con	-0.56 (ns)	-0.46 (*)	-0.11 (ns)	-0.17 (ns)	-0.29 (**)	-0.37 (**)	-0.40 (***)
Ret Uni (+)	vs	Con	-0.50 (ns)	-0.53 (ns)	-0.04 (ns)	-0.14 (ns)	-0.24 (ns)	-0.42 (*)	-0.39 (**)
Ret Uni (-)	vs	Con	-0.63 (ns)	-0.38 (ns)	-0.25 (ns)	-0.20 (ns)	-0.34 (*)	-0.33 (*)	-0.42 (**)
Ret Uni (+)	vs	Ret Uni (-)	0.13 (ns)	-0.15 (ns)	0.28 (ns)	0.06 (ns)	0.10 (ns)	-0.09 (ns)	0.03 (ns)
Ret Uni (+)	vs	Ret Bi	1.64 (**)	0.15 (ns)	1.49 (**)	0.29 (ns)	-0.04 (ns)	0.16 (ns)	-0.04 (ns)
Ret Uni (+/-)	vs	Ret Bi	1.64 (**)	0.15 (ns)	1.49 (**)	0.29 (ns)	-0.04 (ns)	0.16 (ns)	-0.04 (ns)

Measure is [mm]. *** p < 0.001; Con** p < 0.01; * p < 0.05; ns = p > 0.05.

Ret (+/-) = canine impaction: no consideration of impaction side

Ret (+) = canine impaction: only lateral incisor on the side of impaction

Ret Bi = bilateral canine impaction: both upper lateral incisors

Ret Uni (+/-) = unilateral canine impaction: both upper lateral incisors

Ret Uni (+) = unilateral canine impaction: only lateral incisor on the side of impaction

Ret Uni (-) = unilateral canine impaction: only lateral incisor on the opposite side of impaction

Con = control group without canine impaction (both upper lateral incisors)

IV. Discussion

The coincidence of lateral incisor anomalies with palatally impacted canines has been confirmed by many authors [8, 9, 10]. Most of these studies were carried out on the casts or an orthopantomographic x-ray, which is the reason why none of the authors measured root widths. The measurement of root width, particularly the vestibulo-oral root width, had not been possible before the 3D diagnostic method came in use. CBCT has opened new possibilities in dental research.

On the basis of previously cited studies it has been found out that a smaller mesiodistal width of the lateral incisor crown is associated with a shorter root length. A shorter lateral incisor root is one of the critical factors for the guidance theory of palatal canine displacement [11]. Our study confirms that the root of the lateral incisor is not only shorter, but also narrower.

The difference between the crown or root size of upper lateral incisors on the side with impaction and on the opposite side in the group of patients with unilateral impacted canine was not proved. These results are dissimilar to those of Becker obtained in 1981 [8], who measured the mesiodistal size of the upper lateral incisor crown in patients with unilateral canine impaction on plaster casts. The outcome of his research is that the lateral incisor crowns are narrower on the side of the impaction. On the other side, Černočová [15] in her paper published in 2010 failed to prove any difference in the crown size of lateral incisors on the side of the impaction and on the opposite side. The size of the upper lateral incisor was evaluated only in terms of the relationship between upper and lower lateral incisor by both authors. The upper lateral incisor was described as microdontic only when its mesiodistal size was smaller than that of the lower incisor. In 2000, Langberg and Peck [3] compared incisor widths in the upper and lower jaws in patients with and without canine impaction. When compared to the control group, incisor sizes were smaller. These data are coincident with our results.

In our experiment, the width of the lateral incisor root on the cemento-enamel junction and in the middle of the root in the patients with unilateral and bilateral palatal canine impaction was the main observed morphological feature.

In our study, both mesiodistal and vestibulo-oral widths of the upper lateral incisor roots in the group with impaction were smaller than in the control group. In the bilateral canine impaction patients, vestibulo-oral root widths were even narrower than in unilateral impaction patients. This may imply that the vestibulo-oral root width of the lateral incisor can play an important role during canine eruption – incisor root contact and guidance to a correct eruption path. It brings the third dimension to the guidance theory – the vestibulo-oral root width. If the vestibulo-oral root width of the upper lateral incisor is sufficient, the possibility of canine and incisor root

contact is very high. On the other hand, vestibulo-orally narrower width of the lateral incisor root can cause failure of contact between the canine crown and the incisor root. It was also confirmed by Liuk et al. [12] in 2013. This is one of the few CBCT researches on lateral incisors in the patients with palatally impacted canines.

In patients with canine impaction, the lateral incisor exhibited shorter length. It was caused by a shorter root, on average 0.6 mm shorter in the group of patients with unilateral impaction and 1.5 mm in the group with bilateral impactions. Crown narrowing was not so significant, at most 0.6 mm on average. In the studies of Liuk [12] and Becker [11], tooth shortening was 2.1 mm more than in the control group. It is 0.9 mm (42%) more than in our study. Becker performed his measurements on OPG where the general tooth length was 6 mm longer than in the CBCT study done by Liuk.

The patient groups were not gender homogeneous; there were 75% and 27% of women in the group with canine impaction and in the control group, respectively. The mesiodistal tooth width in women is smaller according to Becker [4]. A gender nonhomogeneous group can cause bias in research results. That was the reason why we measured the width of the upper and lower central incisors. No differences in the size of incisors were found between the groups with and without canine impaction.

V. Conclusion

1. Lateral incisor crowns on the side of the impacted canine are shorter in the group of patients with canine impaction than in the control group without impaction. They are 0.5 mm shorter in the patients with unilateral impaction and 0.7 mm shorter in the patients with bilateral impaction.
2. Lateral incisor root length is 0.6 mm shorter in the group of patients with unilateral impaction and 1.5 mm shorter in the patients with bilateral canine impaction than in the control group without impactions.
3. Lateral incisor roots on the side of the impaction as well as on the opposite side are 0.4 mm labiolingually and mesiodistally narrower in the group with canine impaction than in the control group. Lateral incisor roots in patients with bilateral canine impaction are even narrower labiolingually, 0.6 mm on average.
4. There is no difference in tooth length or root width between lateral incisors on the side of canine impaction and on the opposite side.
5. Lateral incisor root length is 1.5 mm shorter in patients with unilateral canine impaction than in those with bilateral canine impaction. There is no difference in lateral incisor root width between the unilateral and bilateral impaction groups.

References

- [1]. Camillieri S, Lewis CM, McDonald F. Ectopic maxillary canines: segregation analysis and a twin study. *J Dent Res* 2008; 87: 580-3
- [2]. Newcomb MR. Recognition and interception of aberrant canine eruption. *Angle Orthodont.* 1959; 29:161-168
- [3]. Langberg BJ, Peck S. Tooth-size reduction associated with occurrence of palatal displacement of canines. *Angle Orthodont.* 2000; 70:126-128.
- [4]. Becker A, Sharabi S, Chaushu S. Maxillary tooth size variation in dentitions with palatal canine displacement. *Eur. J. Orthodont.* 2002; 24:313-318.
- [5]. Leifert S, Jonas IE. Dental anomalies as a microsymptom of palatal canine displacement. *J. orofac. Orthop.* 2003; 64:108-120
- [6]. Peck S, Peck L, Kataja M. Prevalence of tooth agenesis and peg-shaped maxillary lateral incisor associated with palatally displaced canine (PDC) anomaly. *Amer. J. Orthodont. Dentofacial Orthop.* 1996; 110:441-443
- [7]. Peck S, Peck L, Kataja M. Concomitant occurrence of canine malposition and tooth agenesis: evidence of orofacial genetic fields. *Amer. J. Orthodont. Dentofacial Orthop.* 2002;122:657-660
- [8]. Becker A, Smith P, Behar R. The incidence of anomalous maxillary lateral incisors in relation to palatally-displaced cuspids. *Angle Orthodont.* 1981; 51:24-29.
- [9]. Miller BH. Influence of congenitally missing teeth on the eruption of the upper canine. *Dent. Practit. Dent. Rec.* 1963; 13:497-504.
- [10]. Brin I, Becker A, Salhav M. Position of the maxillary permanent canine in relation to anomalous or missing lateral incisors: a population study. *Eur. J. Orthodont.* 1986; 8:12-16.
- [11]. Becker A, Zilberman Y, Tsur B. Root length of lateral incisors adjacent to palatally-displaced maxillary cuspids. *Angle Orthodont.* 1984; 54:218-225.
- [12]. Liuk WI, Olive J R, Griffin M, Monsour P. Associations between palatally displaced canines and maxillary lateral incisors, *Amer. J. Orthodont. Dentofacial Orthop.* 2013; 143: 622-632.
- [13]. Becker A. *Orthodontic treatment of impacted teeth.* London: Martin Dunitz, 1998.
- [14]. Dahlberg, G.: *Statistical methods for medical and biological students.* New York: Interscience Publications, 1940.
- [15]. Černochová, P.: *Poruchy prořezávání horního stálého špičáku,* Habilitační práce, Brno, 2010.
- [16]. Kishnani R.; Bharat R: A New Approach in Diagnosis of Palatally Impacted Maxillary Canine in Orthodontic Patient by Cone Beam Computed Tomography (CBCT) - A Case Report, *IOSR – JDMS.* 2014; 13:48 – 51.