

## Role of Advancement Flaps in Excision of Pilonidal sinus

Dr. Poornachandra Thejeswi<sup>1</sup>, Dr. Vamsi Krishna<sup>2</sup>, Dr. Shivananda Prabhu<sup>3</sup>,

Dr. Rahul Bhat<sup>4</sup>

<sup>1</sup>. MS Gen Surg Associate Professor, <sup>2</sup>. MS Gen Surg Resident

<sup>3</sup>. MS Gen Surg Professor, <sup>4</sup>. MS Gen Surg Associate Professor

Department of Surgery. Kasturba Medical College .Mangalore .Manipal University.

**Abstract :** 38 cases of sacrococcygeal Pilonidal Sinus underwent wide excision and closure by advancement Flaps .Lesser pain, hospital stay ,good healing, lower SSI and wound related complications and no recurrence was noted in the study population .The results are gratifying from our experience . Rhomboid flap should be considered in all cases undergoing excision of pilonidal sinus as the first choice.

**Key words:** Pilonidal Sinus , Limberg Flap .

### I. Introduction

Pilonidal Sinus is commonly encountered in General surgery Practice .The initial presentation can be the sinus or sometimes an abscess which arises from the sinus tract.The sacrococcygeal pilonidal sinus is common in men in third or fourth decade of life. Local trauma, poor hygiene, excessive hairiness, and presence of deep natal cleft. The presence of excess hair contributes to infection and inflammation and formation of sinus over a period of time. Surgical techniques include laying the track open, wide excision with open wound, wide excision with marsupialisation, excision with primary midline or asymmetric closure and techniques involving various flaps procedures. (1)The Major concern with simple excision is recurrence and delayed closure of the wound if the area of the tract is larger.In our centre we have tried Romberg flap for closure following excision of Pilonidal Sinus.

### II. Methods

38 cases of primary pionidal sinus and 6 cases of Recurrent pilonidal sinuses were included in our study .18 cases had presented with abscess or had history of abscess or purulent discharge at the sinus site and underwent incision and drainage followed by excision and flap closure.6 cases were Diabetics and were under strict Glycemic control at the time of Surgical procedure. Advancement flaps were taken from the Gluteal region after ensuring complete excision of the sinus in rhomboid fashion.Surgical procedure were done under cover of Antibiotics.Romovac drain was used in all cases for a period of minimum of 48 hrs & removed when drainage were serous and scanty. Skin was closed with 3- 0 Ethilon. All patients were advised to regularly shave in the sacro gluteal region after wound healing.

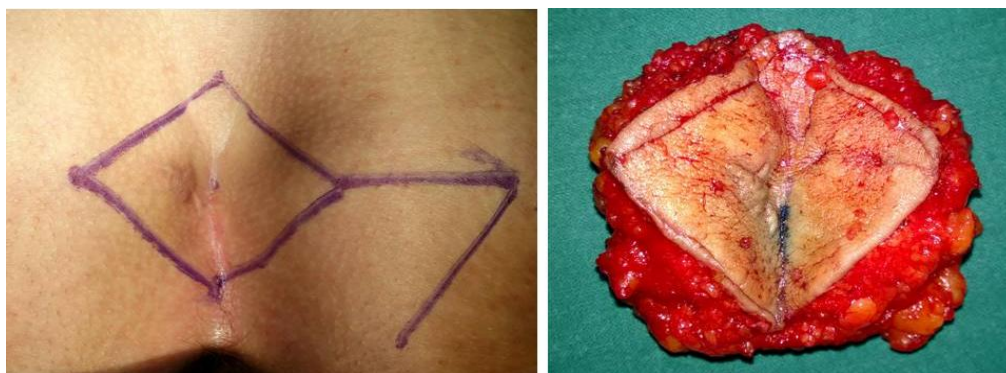
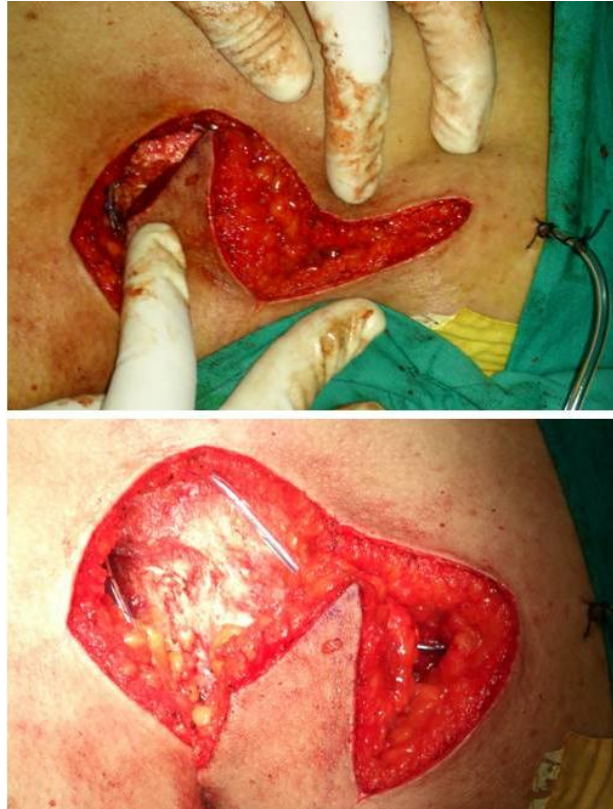
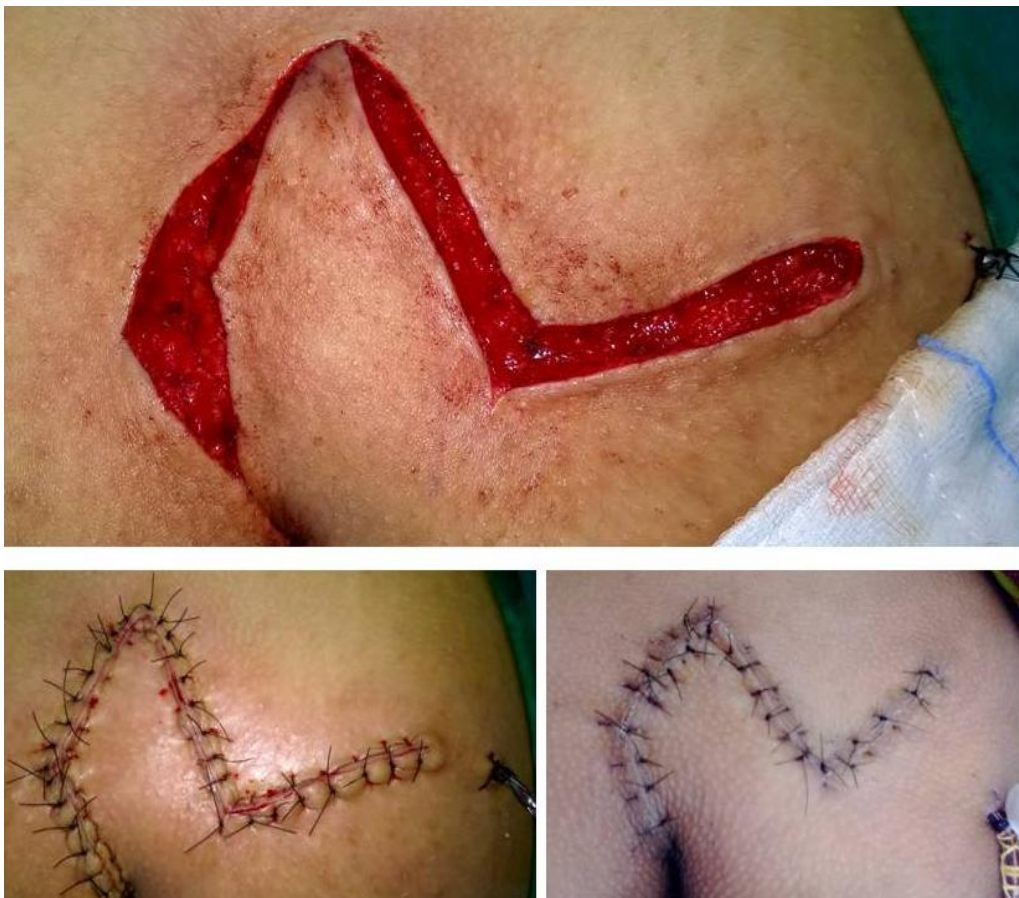
Figure 1 ; Marking and excision of Pilonidal sinus completely.



**Figure 2 :** Advancement of Rhomboid flaps.



**Figure 3 ;**Approximation and closure of the defects with Limberg Flap by suturing with 3 – 0 Ethilon.

### **III. Results**

Complete excision was achieved in all cases. The length of the tract varied from 2 to 8 cm .A clear margin beyond 1 cm was obtained at the angles from the sinus tract. Overall results were satisfactory. There were no recurrence in our series at 1 year of follow up. 1 patient had partial necrosis of the flap which required re exploration debridement and delayed closure with regular dressings. 3 patients had minimal flap necrosis .SSI occurred in 4 patients which was managed conservatively. The mean hospitalization was 4.3 SD 0.30 days (range 2-5 days), and the mean time required for recovery and return to daily activities was 11.00 SD 3.10 days (range 8-18 days).

### **IV. Discussion**

Limberg flap is basically a parallelogram with two angles of 120° and two of 60° These angles that can be modified depending on the shape of the lesion or defect. All sides of the rhomboid and all sides of the flap are equal. As many as four flaps can be raised from one rhomboid, if required (3). The procedure and flap elevation from the subcutaneous tissue is Easy to perform and the Vascularity of the Flap is good .The flap design places the longitudinal axis of the rhomboid excision parallel to the line of minimal skin tension.It can be performed almost anywhere in the body with good cosmetic results.( 3)

The vascularity in the midline is less compared to lateral structures in the fasciocutaneous plane at the back. The closure of the defects in midline might give away if the conditions are not optimum for perfect healing. good healing is provided by the limberg flap which combines the advantage of closing the defect in the midline with vascularity obtained laterally and effectively reduce the incidence of wound infection ,gaping and necrosis.Also lateralisation of inferior apex have shown better results in other studies. This technique is worth to be considered as the surgical treatment of choice and residents shall also benefit from learning the surgical practice of advancement flaps and experience the benefits. There is a short hospital stay and avoids pain and skin grafting and is almost a single staged and hospitalisation procedure for complete clearance .

### **V. Conclusion**

Advancement Flaps is a definitive surgical procedure for pilonidal sinus and avoids recurrence following complete excision of the tract.

### **References**

- [1]. Muhammad Nadeem Aslam, Sidra Shoaib, Abdul Majeed Choudhry. Use of Limberg Flap for Pilonidal sinus –A Viable Option. J Ayub Med Coll Abbottabad 2009;21(4)
- [2]. Menten BB, Leventoglu S, Cihan A, Tatlicioglu E, Akin M, Oguz M. Modified Limberg transposition flap for sacrococcygeal pilonidal sinus Surg Today. 2004;34(5):419-23
- [3]. Chasmar LR. The versatile rhomboid (Limberg) flap. Can J Plast Surg. 2007 Summer; 15(2): 67–71.