

Multiple Congenital Anomalies Associated In Children with Duodenal Atresia- 2 Case Reports and Review of Literature

Dr.Sipala Siva kumar¹, Dr.T.Vittal Mohan²

Dept. of Pediatric Surgery, S.V. Medical College, Tirupati, A.P., Dr. NTR University of Health Sciences, A.P., India.

Abstract: Duodenal Atresia has been reported with multiple associated anomalies which are rare .here we report two such cases, their management,outcome and review of relevant literature.

KeyWords: Duodenal Atresia, Multiple Congenital Anomalies.

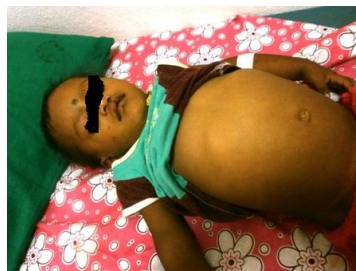I. Introduction

The duodenum is the most common site of neonatal intestinal obstruction accounting for nearly half of all cases.the incidence of duodenal atresia has been estimated as 1 in 6000 to 1 in 10,000 live births and are often associated with other congenital anomalies including trisomy 21 and cardiac malformations[1].because of extreme rarity of multiple anomalies associated with duodenal atresia we are reporting.

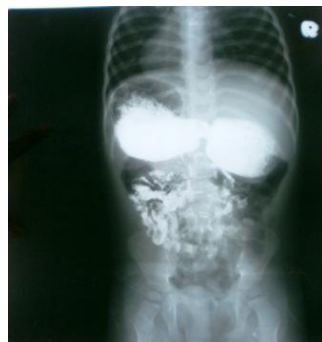II. Case Reports

Case 1

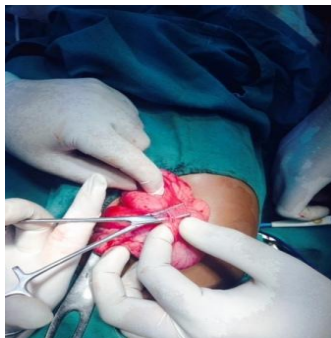
A 2year male child weighing 7 kg referred with complaints of bilious vomitings.no antenatal usg done.there was developmental delay and features of Down syndrome,cleft lip(partial) on left side,upper abdominal fullness and systolic cardiac murmer.plain radiograph of abdomen revealed double –bubble sign with sparse distal gas shadows.upper gastrointestinal contrast study confirmed duodenal atresia.echo detected Atrio ventricular septal defect.after adequate preparation we did laparotomy by supraumbilical transverse muscle cutting incision and the findings were type1 duodenal atresia with a wind sock deformity and malrotation. We did Ladd's procedure and duodenotomy by vertical incision, excised the membrane and closed the duodenotomy transversly and kept a flank drain.child recovered uneventfully and discharged on 7th post operative day.



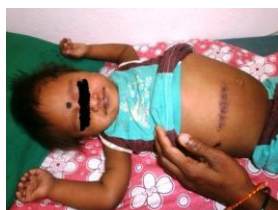Duodenal Atresia with Down Syndrome and cleft lip



Gastrointestinal contrast showing Duodenal Atresia



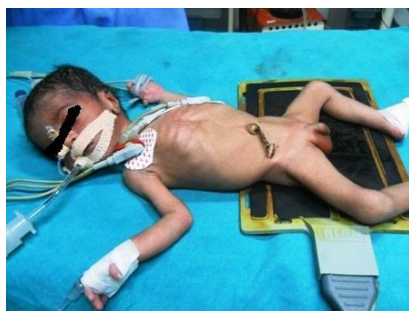Operative photograph of Duodenal Atresia with Malrotation



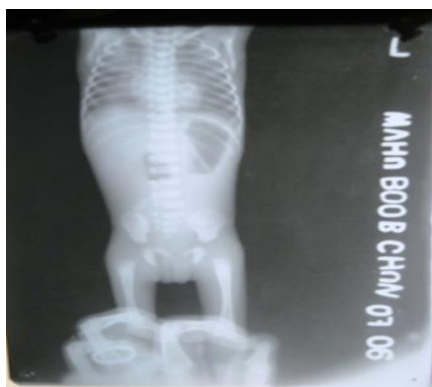Post operative scar

Case 2

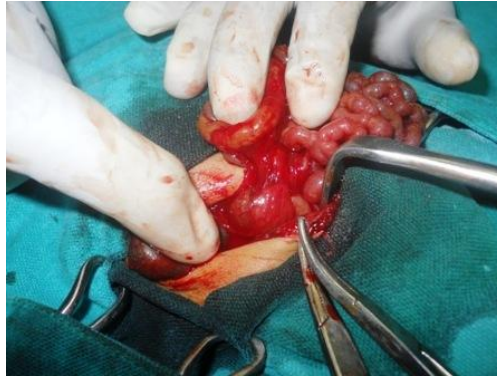A 3 day old male baby weighing 2.5 kg referred with complaints of bilious vomitings since birth. history of maternal polyhydramnios present. plain radiograph of abdomen confirmed the duodenal atresia by double –bubble sign. after adequate preparation by i.v fluids and nasogastric decompression we did laparotomy by supraumbilical transverse muscle cutting incision and the findings were type I duodenal atresia associated with with malrotation and annular pancreas We did Ladd’s procedure and diamond shaped duodeno-duodenostomy and kept a flank drain. child recovered uneventfully and discharged on 7th post operative day.



Duodenal Atresia



plain radiograph showing double –bubble sign



Operative photograph showing Ladd's bands

III. Discussion

Congenital Anomalies and syndromes are associated in more than half of the patients with duodenal atresia. Down syndrome is present in 30% of cases, annular pancreas in 23%, congenital heart disease in 22%, malrotation in 20%, [1].in2/3rd of patients the associated anomalies occur in isolation where as multiple anomalies in 1/3rd of the patients and alter the final outcome[2].similar cases of multiple anomalies reported by Bilal Mirza et al and goncalves et al.[3,4]

IV. Conclusion

Survival of children with duodenal obstruction has increased from 45% to 95% over the past half century.this dramatic improvement is related to improved diagnosis,surgical and postoperative management.almost all mortality is now related to associated anomalies.

References

- [1]. Harry Applebaum,Steven L Lee,and Devin P.Puaong. Duodenal atresia and Stenosis-Annular pancreas. In: Grosfeld JL, O' Neill JA Jr, Coran AG, Fonkalsrud EW, (ed). Pediatric Surgery, 6th edn. St. Louis: Mosby Elsevier. 2006;p 1260-68.
- [2]. Choudhry MS, Rahman N, Boyd P, Lakhook K. Duodenal atresia: associated anomalies, Prenatal diagnosis and outcome. *Pediatr Surg Int.* 2009; 25: 727-30
- [3]. Mriza B, Ijaz L, Saleem M, Sheik A. Multiple associated anomalies in a single patient of duodenal atresia: a case report. *Cases J.* 2008; 1:215
- [4]. Goncalves MEA, Viana DC, Rodrigues JC, Macedo DB, Lima TL. Duodenal atresia combined with annular pancreas: a case report. *Rev Para Med.* 2008;22:601289.