

## A Case Of Addison's Due To Non Meningococcal (Tuberculous) Adrenal Hemorrhage

Dr.B.S.V.V.Ratnagiri, M.D;D.M<sup>1</sup>, Dr.Lella Padmaja MBBS: DGO<sup>2</sup>,

Dr.M.Jagan Mohan, M.D;D.M<sup>3</sup>; Dr. Sudhakar Bandari, M.D<sup>4</sup>,

M.V.Sairam, U.G<sup>5</sup>

<sup>1</sup> (Assistant Professor of Gastroenterology, Siddhartha Medical College, Vijayawada-520011, A.P, India)

<sup>2</sup> (Tutor in Obstetrics and Gynecology Siddhartha Medical College, Vijayawada-520011, A.P, India)

<sup>3</sup> (Professor of Gastroenterology, Siddhartha Medical College, Vijayawada-520011, A.P, India)

<sup>4</sup> (Postgraduate in General Medicine, Siddhartha Medical College, Vijayawada-520011, A.P, India)

<sup>5</sup> (Under graduate, 4<sup>th</sup> year MBBS, Siddhartha Medical College-520008, Vijayawada, A.P, India)

**Abstract:** A 40 year old male patient was admitted with history of nausea, vomiting, loss of appetite, loss of weight and severe fatigue with past history of tuberculosis and had ATT for 6 months. Findings in physical examination were mild dehydration, hyper pigmentation of face, hands (creases), elbows and feet, and low blood pressure. Lab evaluation was normal except for raised ESR. Biochemical workup showed hyponatremia, hyperkalemia, and raised Creatinine. Ultrasound of abdomen showed bilateral enlarged adrenals with calcifications, and also thickened ileocaecal junction noted. CT scan of abdomen showed bilateral enlarged adrenals with small hemorrhages and speckled calcification. Endocrinal assays showed low early morning serum cortisol and high adrenocorticotrophic hormone (ACTH). History, clinical examination, laboratory work up confirmed the diagnosis of Addison's disease secondary to tuberculosis. Patient was kept on cortisol supplementation along with antituberculosis treatment (ATT). Bilateral adrenal hemorrhage is a rare complication of tuberculosis which was documented in our case but calcifications in adrenal glands are common finding in tuberculosis.

**Keywords:** Addison's disease, Hyponatremia, Hyperkalemia, Speckled calcification, adrenocorticotrophic hormone (ACTH).

### I. Introduction

Tuberculosis may affect many of the endocrine glands including the hypothalamus, pituitary, thyroid, but the most commonly involved endocrine organ is the adrenal gland. In addition to mycobacterial tuberculosis, other mycobacterium, bacteria, viruses and fungi may affect the adrenal glands and lead to the development of adrenal insufficiency. Most cases of adrenal tuberculosis are found 10 to 15 years after the initial infection. Hence, tuberculous Addison's disease has a relatively late onset. Bilateral adrenal hemorrhage is a rare complication of tuberculosis which was documented in our case but calcifications in adrenal glands are common finding in tuberculosis.

### II. Case Report

#### Case presentation:

A 40 year old male patient was admitted with history of nausea, vomiting, loss of appetite, loss of weight and severe fatigue since 4 months. He denied any history of fever, cough, rash, back pain, drug intake, or any history of convulsions. His past history was positive for tuberculosis and had ATT for 6 months. He was not a known hypertensive but diabetic having treatment since 1 year. He was treated with nonspecific supportive therapies in primary care hospital, before getting admitted in our ward.

#### Clinical examination:

Patient is sick looking and is conscious, coherent with signs of mild dehydration. He had hyper pigmentation of hands (creases), elbows and feet. PR: 78/min, BP: 90/60 mm hg, Respiratory rate: 18/min. Afebrile. Respiratory system: Bilateral air entry present with normal vesicular breath sounds. Per abdomen: Soft and no organomegaly. Cardiovascular system: Normal

#### Investigations:

Complete blood count (CBC) showed normal. Hb 13.2 g/dl, white blood cells 7,000/cram with normal platelet count. ESR 40mm/1g hour. Serum Creatinine is 2.2mg/dl.

The sodium was: 128 mmol/L, potassium was 6.5 mmol/L, chlorides were 89mmol/L.

Normal liver function tests..

Chest X ray – Normal.

Ultrasound of abdomen showed bilateral enlarged adrenals with calcification, small hemorrhages and thickened ileocaecal junction noted (possibly of Kochs etiology).

CT scanning of abdomen showed bilateral enlarged adrenals with small hemorrhages and speckled calcifications.

Mantoux test was negative.

PCR for Tuberculosis is positive.

Early morning serum cortisol was very low (0.25ug/c11). The adrenocorticotrophic hormone (ACTH) level was very high (1250pg/ml).

The gonadotrophic hormones, prolactin and thyroid functions tests were within normal limits.

The serology for HIV 1 and 2 were negative.

**Diagnosis:** History, clinical examination, laboratory work up confirmed the diagnosis of Addison's disease secondary to tuberculosis.

**Treatment:** Patient was kept on hormonal supplementation (cortisol) and anti Tuberculous treatment (ATT).

### III. Discussion

Addison's disease is a primary adrenocortical deficiency that is the result of damage to the adrenal cortex. Overt clinical features of hypoadrenalism occur when 80-90% of both adrenal cortices are destroyed.

Tuberculosis is still a major cause of adrenal insufficiency in populations with a high prevalence of tuberculosis like in India.

Tuberculosis may affect many of the endocrine glands including the hypothalamus, pituitary, thyroid, but the most commonly involved endocrine organ is the adrenal gland. In addition to mycobacterial tuberculosis, other mycobacterium, bacteria, viruses and fungi may affect the adrenal glands and lead to the development of adrenal insufficiency. Most cases of adrenal tuberculosis are found 10 to 15 years after the initial infection. Hence, tuberculous Addison's disease has a relatively late onset.

Enlargement of both adrenal glands may occur in most (90%) patients with Tuberculous adrenal insufficiency. The imaging findings may vary with the stage and activity of the inflammatory process. In early Tuberculousadrenitis, bilateral adrenal enlargement is the typical finding, as in the present case. At the late or healing stage, enlargement of Tuberculous adrenals may partially or completely resolve, with or without calcification or atrophy.

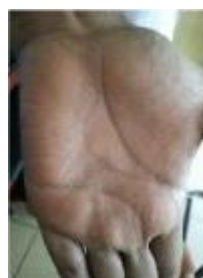It has been stated that, adrenal enlargement may be due to activation of hypothalamus-pituitary-adrenal axis during active pulmonary tuberculosis, as active pulmonary tuberculosis is a stressful condition as direct involvement of adrenal glands by infection.

In the present case, the patient was started with anti-tuberculous treatment. Recovery of adrenal function may occur in patients treated for Tuberculosis, but absence of adrenal recovery 2 to 5 years after therapy also has been observed.

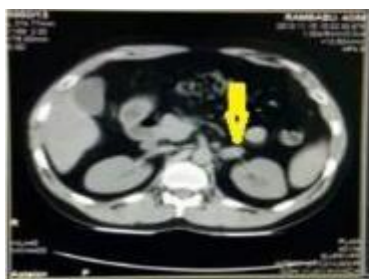In the present patient, adrenal insufficiency not recovered at short-term followup, and the patient continues to take hormone replacement.



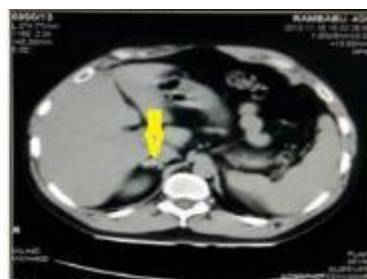
Hyperpigmentation



Hyperpigmented creases



Enlarged left adrenal with hemorrhage



Enlarged left adrenal with hemorrhage

#### **IV. Conclusion**

Bilateral adrenal hemorrhage is a rare complication of tuberculosis which was documented in our case but calcifications in adrenal glands are common finding in adrenal tuberculosis.

#### **References**

- [1]. Williams textbook of endocrinology.-12<sup>th</sup>ed. I Shlomo Melmed [et al.]p. ; cm.
- [2]. J Assoc Physicians India 2000 Sep; 48(9):919-20. Disseminated tuberculosis causing bilateral adrenal enlargement and Addison's disease .
- [3]. J Assoc Physicians India SEPTEMBER 2013 • VOL. 61, Addison's Disease presenting with Muscle Spasm
- [4]. Kenneth L Becker. Principles and Practice of Endocrinology and metabolism. 3rd ed. 2001; Lippincott Williams & Wilkins: 1918.
- [5]. Martorell PM, Roep BO, sss JWA. Autoimmunity in Addison's disease. The Netherlands Journal of Medicine 2002;60:269-275.
- [6]. Agarwal G, Bhatia E, Pandey R, Jain SK. Clinical profile and prognosis of Addison's disease in India. Natl Med J India 2001;14:23-5
- [7]. Shapiro MS, Trebich C, Shilo L, Shenkman L. Myalgias and muscle contractures as the presenting signs of Addison's disease. Postgraduate Medical Journal 1988;64:222-3.