

Laser assisted treatment of excessive gingival display along with modified lip re-positioning

Dr.Cimi Iqbal¹ , Dr.K.Nandakumar² ,Dr.T.P Padmakumar³

¹Consultant Periodontist, Travancore Medical College & Hospital, Kerala, India

²Professor and HOD, Department of Periodontics, Azeezia College of Dental Science & Research, Kerala, India ³Professor, Department of Periodontics, Azeezia College of Dental Science & Research, Kerala, India

Abstract: Excessive gingival display and gingival hyper-pigmentation are major concerns for a large number of patients visiting the dentist. This problem is aggravated in patients with a "gummy smile" or excessive gingival display while smiling. The case presented is with a similar complaint, and the procedure used had shown stable and significant outcome through a conservative approach. Two stage procedure was done. First stage, surgical crown lengthening along with de-pigmentation using diode laser followed by second stage surgical lip re-positioning to reduce the excessive gingival display. This technique can be considered as an alternative treatment modality in aesthetic satisfaction.

I. Introduction

Excessive gingival display commonly referred to as "gummy smile" can be a source of embarrassment for some patients. The smile is one of the key factors of a first impression¹. Advances in dental materials and laboratory technique had led to excellent crowns, veneers, and composite restoration. However, some patients who present with gingival and skeletal deformities may require more complex esthetic rehabilitation. For these challenging patients, a multidisciplinary approach can be beneficial to enhance a balance harmony between all the components of the smile: *Lips, teeth & gingival scaffold*.^[1]

Lips define the esthetic zone and the lip line can be defined, while smiling as *low, medium, or high*.^[2] The lip is considered *low* when only part of the teeth are visible below the upper lip, *medium* when 1 to 3mm of the marginal gingiva is exposed during a smile and *high* (gummy smile) when more than 3mm of gingiva is shown. It is an aesthetic issue that can affect a large portion of the population, with a reported prevalence between 10.5%¹ and 29%.^[3] Studies shows predominance of gummy smile in female(2:1) and low lip line in male (2.5:1).^[4]

Excessive gingival display has **four possible etiologies**

Cause may be related to one or more factors relating to gums themselves, the teeth, or even the lip or jaw. Each of these areas will require different approach to solve the problem.

First, it may be a result of **delayed eruption** in which the *gingiva* fail to complete the apical migration over the maxillary teeth to a portion that is 1mm coronal to the cemento - enamel junction.^[6] In such cases, restoring the normal dento-gingival relationships can be achieved with an esthetic crown lengthening.^[7] This procedure involve moving the gingival margins apically through soft and possibly hard tissue resection.

Second possible cause is **compensatory eruption** of maxillary *teeth* due to natural variations in the tooth-eruption process that can result in shorter than normal teeth and gumminess of the smile. This happens in case of attrition of the teeth. To compensate for the wear and maintain a functional bite, the teeth actually begin to move (or erupt) very slowly outward from the gum. This makes the smile appear gummier. In such cases orthodontic treatment can be used to move the affected teeth back up into correct position.^[8] The length of the teeth can be corrected by (crowning) them or covering them with thin porcelain veneers.

The third possibility related to *jaws* is **vertical maxillary excess** in which there is an enlarged vertical dimension of the mid-face and "incompetent" lips. Treatment involves orthognathic surgery to restore normal inter- jaw relationships and to reduce the gingival display^[9]; this procedure involves hospitalization, but it can achieve dramatic results.

Finally the cause may related to *lips*, may be short or **hyperactive upper lip** where, when the patient smiles, the upper lip moves in an apical direction and exposes the dentition and excessive gingiva. On average, the upper lip moves 6 to 8 millimeters from its normal resting position to a full smile.

Gummy smile due to hyperactive upper lip can be corrected using various technique, with highly variable outcome :

✚ Botulinum toxin (Polo 2005, Mazzuco & Hexsel 2010)

✚ Lip elongation associated with rhinoplasty (Ezquerria et al. 1999),

- ✦ Detachment of lip muscles(Litton & Fournier 1979),
- ✦ Myotomy and partial removal (Miskinyar1983, Ishida et al. 2010)
- ✦ Lip repositioning (Rubinstein & Kostianovsky 1973,^[10] Rosenblatt & Simon 2006, Simon et al. 2007)^[11] are the reported treatment approaches.

The objective of lip repositioning is to minimize the gingival display by limiting the retraction of the elevator smile muscles (e.g., zygomaticus minor, levator anguli oris, orbicularis oris and levator labii superioris) which is achieved by removing a strip of mucosa from the maxillary buccal vestibule and creating a partial thickness flap between the muco-gingival junction and the upper lip musculature. The lip mucosa is then sutured to the muco-gingival line, resulting in a narrower vestibule and restricted muscle pull, thereby reducing gingival display during smiling.^[11]

This technique was originally described as cosmetic surgery by Rubinstein and Kostianovsky^[10] for correction of a gummy smile caused by a hypermobile lip. The literature includes only isolated case reports of lip repositioning surgery(Rosenblatt & Simon 2006, Simon et al 2007, Humayun et al 2010) This surgical procedure was designed to be shorter, less aggressive, and was thought to have fewer postoperative complications compared to orthognathic surgery. Lip repositioning is the reverse of vestibular extension procedure.

The modification of the original Rubinstein & Kostianovsky (1973) technique, where the midline maxillary labial frenum was not excised. This modification was introduced to facilitate maintaining the position of the labial midline and to reduce the morbidity associated with the procedure.

The article presented here with a similar case of gummy smile , gingival hyper-pigmentation and hyperactive upper lip in which the surgical crown lengthening & gingival de-pigmentation was done using diode laser followed by "modified lip repositioning" to reduce gingival display.

II. Case Report

A 26 yr old female patient presented to the Department of Periodontics, Azeezia college of Dental Sciences & Research , Kollam, with a chief complaint of swelling of gums in the upper front teeth region and excessive display of the gums while smiling which was aesthetically unpleasing for the patient. Her medical history revealed that, she had undergone treatment for hypothyroidism seven years back, presently not under medication.

Patient had undergone orthodontic correction 10 yrs back for the same complaint. Results obtained were not satisfactory for the patient, an alternate treatment option of orthognathic surgery was suggested by an oral and maxillofacial surgeon . She preferred less invasive procedure to address her chief complaint.

Hence after discussing the alternate treatment modalities, benefits, and possible complications for a lip repositioning procedure informed consent was obtained.

During clinical evaluation ,it was verified that patient had incompetent lips with 5mm of gingiva was displayed during her smile, showing harmonious and healthy gingiva and normal upper lip length.

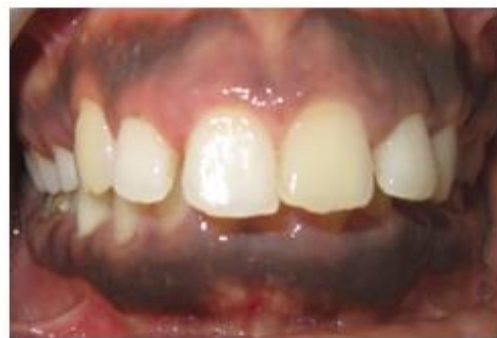A diagnosis of moderate vertical maxillary excess with hyperactivity of upper lip was made.

The surgical procedure was initiated in two stage ,crown lengthening procedure & gingival de-pigmentation using diode laser was done .

After a healing period of one month, patient was not satisfied with the profile due to excessive gingival display while smiling , the second stage of surgical lip repositioning was done for treatment of hyperactive upper lip.



Pre Operative



Hyper-pigmented Gums

III. Surgical Procedure.

1.Crown Lengthening & Depigmentation

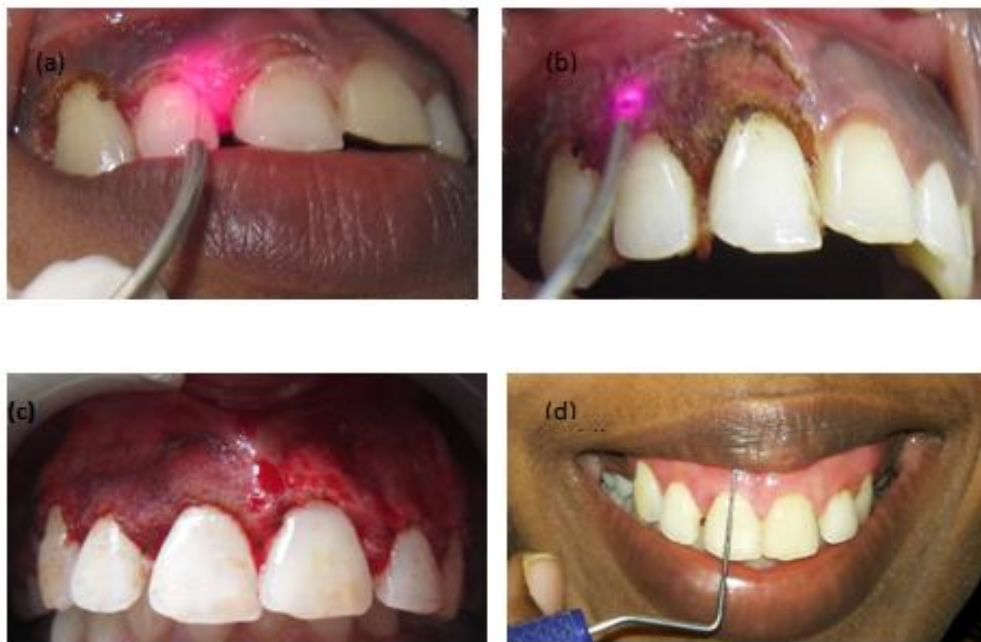After phase I therapy , sulcus depth measuring more than 2mm was found(Pseudopocket). Gingivoplasty procedure was done using diode laser from the distal aspect of maxillary right canine to distal aspect of maxillary left canine. Only topical lignocaine spray was used.

The ZOLOR Photon (3 Watt/810nm) Dental Diode Laser manufactured by us at ZOLOR Technology was used contact method ,with disposable flexible fiber optic system in continuous & pulse mode, power set at 1.5 W& 1W for gingivoplasty and gingival depigmentation respectively.

Laser ablation started from the base of bleeding points created by the pocket marker. Ablation was performed using light brushing strokes & tip was kept in continuous motion. Remnants of ablated tissue were removed using sterile gauze dampened with saline .Gingivoplasty was also done in inter-dental papilla and marginal gingiva to create a normal physiological contour by changing the tip angulations. This procedure was repeated until the desired level of marginal tissue removal with exposure of clinical crown till CEJ.

Depigmentation

Here the fiber-optic hand piece was held in contact mode on to the tissue .Laser ablation started from the muco-gingival junction toward the free gingival margin, including papillae. The motion of ablation was circular with overlapping circles. High attention was taken to avoid passing the laser beam on teeth structures and over mucosa. The ablation of the gingiva was completed within 20 to 25 minutes .There was no need to apply a periodontal dressing. patient were instructed to avoid eating of hot and spicy foods for the first 24 hours. Normal oral hygiene procedures were performed by all patients.



a)Diode laser assisted crown lengthening b)De-pigmentation using diode laser c)Immediate post operative d)One month post operative showing the excessive gingival display.

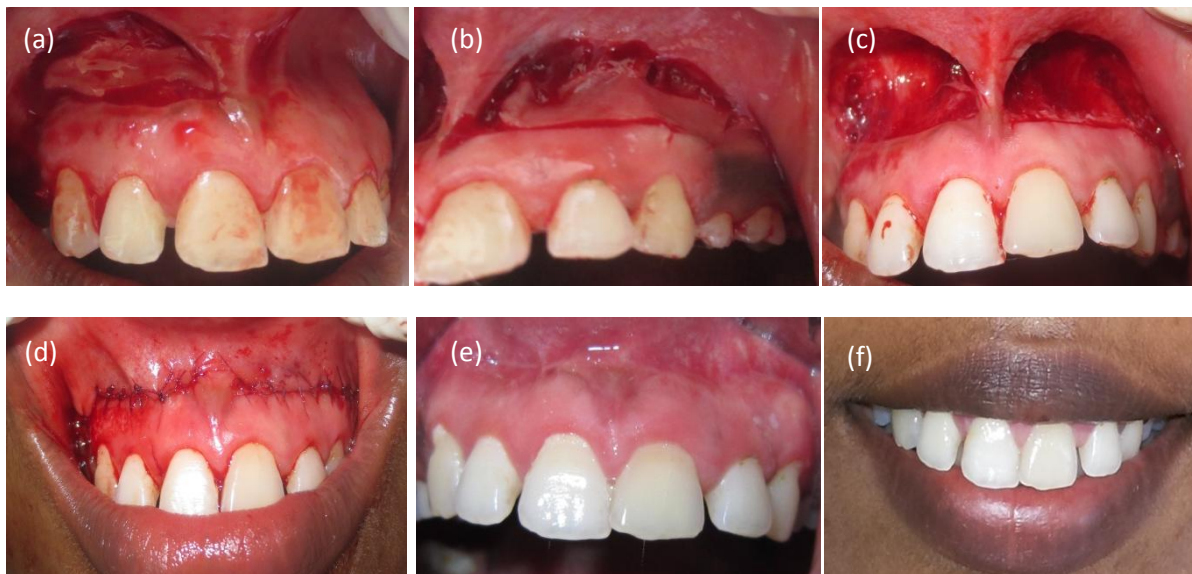
2.Lip Repositioning

The following clinical parameters were recorded during active smile, with a mm ruler in place, at baseline ,third month ,six months.(Table). When the lip covered part of the clinical crown (post-operatively), the amount of gingival display was set at zero. All measurements were recorded to the nearest millimeter over the mid-buccal of the right central incisor.

Table

CLINICAL PARAMETERS	BASELINE	THIRD MONTH	SIX MONTH
Upper Lip Length (from nasal base to the superior border of the upper lip vermillion)	10mm	12mm	12mm
Upper Lip Vermillion length (from inferior border of the upper lip)	9mm	11mm	11mm
Amount of gingival display during active smile (from the inferior border of the upper lip vermillion to the gingival margin of the central incisor).	5mm	1mm	≤2mm

- The surgical procedure was initiated at the left or right side of the maxilla with a partial thickness horizontal incision, 1mm coronal to the mucogingival line, from midline frenum until the canine
 - ❖ At each end of the first incision, a vertical incision was made, extending 10–12 mm apically.(fig a)
 - ❖ Finally, a horizontal incision connecting the two vertical incisions, and parallel to the first incision, was made.
 - ❖ The procedure was repeated on the contra lateral side, leaving the midline frenum intact.(fig b)
 - ❖ The strip of outlined mucosa was removed by a superficial split thickness dissection, leaving the connective tissue exposed. Minor salivary glands were removed, when necessary.(fig c)
 - ❖ Continuous inter-locking sutures were used to stabilize the new mucosal margin to the gingiva (fig d)

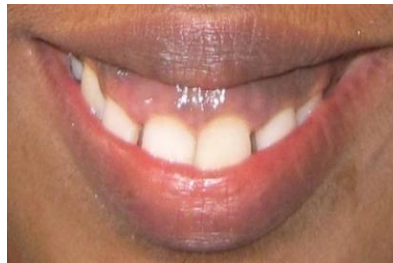


a) Incision design b)contra lateral side c)Mucosal strip removed d) Mucosa positioned and sutured e) one month post operative showing scar formation f) 3 month post operative

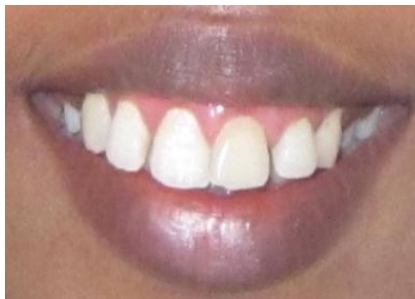Post operative prescription included antibiotics and analgesics . Amoxycillin 500 mg thrice daily was prescribed for five days and ALONAC-P(aceclofenac + paracetamol) twice daily for two days was used as analgesic. The patient was advised to use chlorhexidine mouthwashes (0.12%) for the immediate two weeks postoperative period to aid in plaque control. Post operative instruction included application of ice pack, a soft food diet during the first week, avoidance of any mechanical trauma to surgical site and restriction of lip movement (smiling or talking) during the first 2 weeks.

Post operative healing was uneventful. The patient complaint about tightness of the lip ,lasting for 2 weeks. A minor scar formed on the suture line(fig e),but remained invisible during smiling. The 6 months follow up showed reduction of gingival display , with 1- 2 mm of gingiva visible during smiling .The patient was satisfied with the harmonious smile.

PRE OPERATIVE



POST OPERATIVE SIX MONTHS



IV. Discussion

The plastic surgical procedure is one of the major technique for the correction of various mucogingival problems. Gummy smile correction can be done using various technique. Patient with inadequate clinical crown length and unequal or unaesthetic gingival height are managed by crown lengthening procedure. The various surgical techniques used for crown lengthening are gingivectomy & gingivoplasty, apically displaced flap , crown lengthening using osteotomy and lasers. Similarly gingival de-pigmentation has been carried out using many procedures employing mechanical ^[12] surgical,^[13-14] chemical,^[15] electrosurgical, and cryosurgical ^[16] techniques. Some of those procedures are associated with complications. ^[17] Laser ablation of gingival de-pigmentation has been recognized as one of the most effective, pleasant, and reliable techniques.^[18]

The present case used diode laser for crown lengthening and gingival de-pigmentation as:

Although scalpel surgery is faster and favorable, but it can cause unpleasant bleeding during and after the surgery and is necessary to cover the exposed connective tissue with periodontal pack for 7-10 days. While the diode laser causes minimal damage to the periosteum and bone under the gingiva being treated.^[20] Although healing of laser wounds is slower than healing of scalpel wounds, laser wounds are sterile and less likely to be inflamed.^[19] The primary advantage is hemostasis and relatively dry field. Wound healing was satisfactory , no post operative complication noted . Studies have reported positive outcome after using the diode laser for surgical crown lengthening depigmentation.^[21] Six months post operative result was satisfactory with no evidence of re-pigmentation.

The results showed that the surgical procedure successfully reduced the pre-operative gingival display The obtained ~80% average reduction in gingival display by modified lip repositioning correlated strongly to the combined increase in upper lip and vermilion length, and was stable for the 6 months of follow-up. Minimal gingival display during smile is considered more attractive. The amount of gingival display that is considered attractive varies from 1 mm to 3 mm^[22]. The case treated here had a baseline gingival display ≥ 4 mm .

Although the results of lip repositioning surgery appear stable for up to 6 months post-operatively, longer follow-up periods are necessary to establish the long-term success of this procedure. The stability of outcomes reported in this study is consistent with those of published case reports (Rosenblatt & Simon 2006, Simon et al. 2007, Humayun et al. 2010, Silva et al 2013^[23]) The level of satisfaction with the modified lip repositioning surgery was high. Despite its benefits and other positive attributes, lip repositioning surgery is not indicated in the presence of a severe vertical maxillary excess, narrow band of attached gingiva, because of the ensuing difficulty in flap design, suturing, stabilization and were patient's ability to perform adequate oral hygiene.

V. Conclusion

There are number of modalities and corrective clinical measures that can be used to treat esthetic problems. The decisive factor depends on individual patients and appropriate selection of treatment which suits the patient. The case presented here with excessive gingival display and gingival hyper-pigmentation was treated by laser assisted surgical crown lengthening and de-pigmentation followed by modified lip repositioning instead of initially proposed orthognathic surgery due to apprehensive nature of patient. The suggested alternative treatment with the modified lip repositioning resulted in predicted outcome with high level of patient satisfaction.

Reference

- [1]. Garber DA, Salama MA. The aesthetic smile: Diagnosis and treatment. *Periodontol* 2000 1996;11:18-28
- [2]. Tjan AH, Miller GD, The JG. Some esthetic factors in a smile. *J Prosthet Dent* 1984;51:24-8
- [3]. Dong J. K., Jin T. H., Cho H.W, Oh S.C. The esthetics of the smile: a review of some recent studies. *Int J Prosthodont* 1999; 12:9-19.
- [4]. Peck S, Peck L, Kataja M. The gingival smile line. *Angle Orthod* 1992;62:91-100
- [5]. Stanley J.N, Major M.A. Orofacial complex:Form and Function.In : John.J.Dalton,editor.*Wheeler's Dental Anatomy, Physiology and Occlusion*, 9th ed. Philadelphia : Elsevier Publishing; 2010. p. 82- 90.
- [6]. Maynard JG , Wilson RD. Physiologic dimensions of the periodontium significant to the restorative dentist. *J Periodontol* 1979;50:170-4.
- [7]. Lee EA. Aesthetic crown lengthening: Classification, biologic rationale and treatment planning considerations. *Pract Proced Aesthet Dent* 2004;16:769-78.
- [8]. Kokich VG. Esthetics: The orthodontic-periodontic restorative connection. *Semin Orthod* 1996;2:21-30.
- [9]. Ezquerro F, Berrazueta MJ, Ruiz-Capillas A, Arregui JS. New approach to the gummy smile. *Plast Reconstr Surg* 1999;104:1143-50.
- [10]. Rubinstein AM, Kostianovsky AS. Cosmetic surgery for the malformation of the laugh: Original technique in Spanish. *Pren Med Argent* 1973;60:952.
- [11]. Rosenblatt A, Simon Z. Lip repositioning for reduction of excessive gingival display: A clinical report. *Int J Periodontics Restorative Dent* 2006;26:433-37.
- [12]. Farnoosh AA . Treatment of gingival pigmentation and discoloration for esthetic purposes. *Int J Periodontics Restorative Dent* 1990;10:312-19
- [13]. Tamizi M, Taheri M . Treatment of severe physiologic gingival pigmentation with free gingival autograft. *Quintessence Int* 1996;27:555-58.
- [14]. Almas K, Sadig W. Surgical treatment of melanin- pigmented gingiva; An esthetic approach. *Indian J Dent Res* 2002;13:70-73.
- [15]. Hirschfeld I, Hirschfeld L. Oral pigmentation and a method of removing it. *Oral Surg Oral Med Oral Pathol* 1951;4:1012-16.
- [16]. Tal H. A novel cryosurgical technique for gingival depigmentation. *J Am Acad Dermatol* 1991;24:292-93
- [17]. Atsawasuwan P, Greethong K, Nimmanon V. Treatment of gingival hyperpigmentation for esthetic purposes by Nd:YAG laser: Report of 4 cases. *J Periodontol* 2000; 71:315-321.
- [18]. Tal H, Oegiesser D, Tal M. Gingival depigmentation for aesthetic purposes using erbium:YAG laser: Rationale and technique. *Refuat Hapeh Vehashinayim* 2002;19:25-32.
- [19]. Pick RM, Colvard MD. Current Status of Laser on soft tissue dental surgery. *J Periodontol* 1993;64:589-602
- [20]. John J. Graeber. Gingivoplasty Using an 810-nm Diode Laser to Treat Drug-Induced Gingival Enlargement. *J Laser Dent* 2008;16:136-9
- [21]. Lagdive S, Doshi Y, Marawar PP. Mana. Management of gingival hyperpigmentation using surgical blade and diode laser therapy: A comparative study. *J Oral Laser Applications* 2009;9:41-47.
- [22]. Geron, S. & Atalia, W. Influence of sex on the perception of oral and smile esthetics with different gingival display and incisal plane inclination. *Angle Orthod* 2005 ;75: 778-84.
- [23]. Silva CO, Ribeiro NV, Campos TVS, Rodrigues JG, Tatakis DN. Excessive gingival display: treatment by a modified lip repositioning technique. *J Clin Periodontol* 2013; 40: 260-5.