

A Giant Juvenile Fibroadenoma of Breast

(Dr. Satyajeet Kr Singh, Dr. Kunal, Dr. (Prof) S.Nag.)

Abstract: Giant fibroadenoma are benign tumors, but their rapid growth and large size may determine difficulties in their work up. We present a case of giant juvenile fibroadenoma of breast in a girl of 16 years of age with its diagnostic workup and management. The diagnosis was made on FNAC which was confirmed by Histopathology report.

I. Introduction

Fibroadenoma is the commonest benign breast disease followed by fibrocystic disease. It implies a new growth pattern comprising of both fibrous and glandular tissue. Fibroadenoma are more common before 30 years of age but can occur at any age group within reproductive period of life. In rare occasions it can show rapid and massive growth resulting in giant fibroadenoma. Giant fibroadenoma are greater than 5 cm in diameter and constitute less than 4% of all fibroadenoma. Giant fibroadenoma may be either adult type or juvenile type. Giant juvenile fibroadenoma is a uncommon tumor presenting in a adolescent female.

II. Case History

A 16 years old unmarried female presented in outpatient department at the Narayan Medical College and Hospital Jamuhar, with a rapidly enlarging right breast for 6 months. There was no history of any trauma, nipple discharge, fever, anorexia, weight loss or any significant family history. On clinical examination, a huge enlargement of right breast was found while other breast was normal. It was firm to hard irregular mass, not fixed to skin or to the underlying structure. There was no axillary lymphadenopathy. Routine haematological and biochemical test were within normal limits. Ultrasonography showed heterogeneous paranchymal pattern suggestive of fibroadenoma. On fine-needle aspiration cytology diagnosis was fibroadenoma. The patient underwent enucleation of the lump via circumareolar incision in right breast. The excised lump measured 7.5cm x 5.5cm and weighed 275gm. Cut surface shows multiple grey white nodules. The resected specimen was sent for histopathological study and the result was giant fibroadenoma. The patient is on regular follow up and doing well.

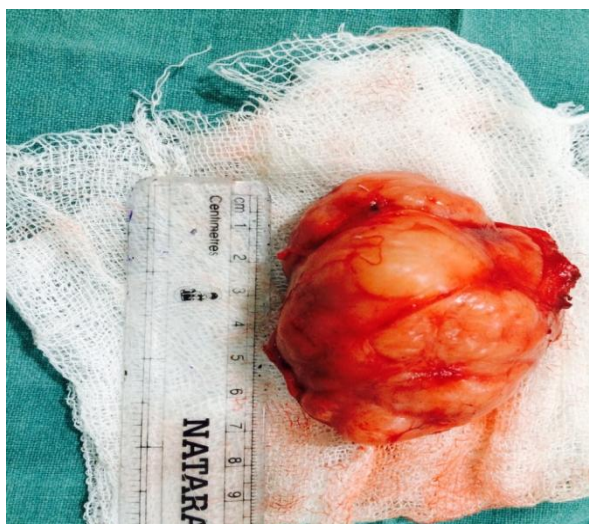

Fig 1

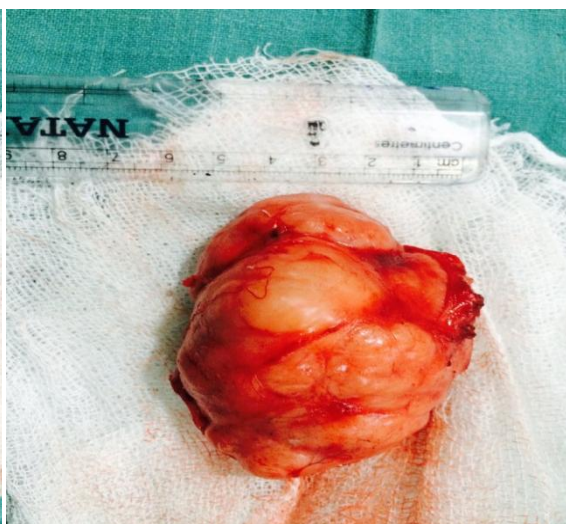


Fig 2

III. Discussion

Breast fibroadenomas are the most common solid lesions found in younger women. They typically present as firm, mobile, painless, easily palpable breast nodules. They occur in any part of reproductive life of female but are more common before the age of 30 years. The nomenclature of fibroadenoma in younger women is confusing and a plethora of names exists to designate the lesion such as age related term juvenile fibroadenoma and size related term giant or massive fibroadenoma. According to Stanford School of Medicine, juvenile fibroadenoma of breast is defined as circumscribed, often large, breast mass occurring in adolescent

females with stromal and epithelial hypercellularity but lacking leaf like growth pattern of phyllodes tumors. Most patients age is 10-20 years with a mean age of 15 years. Giant fibroadenoma is defined as tumour > 5 cm in diameter or disproportionately large compared to the rest of the breast. It is more frequently seen in young and black female. Giant juvenile fibroadenoma causes rapid and massive enlargement of breast in adolescent and is an uncommon tumour. Exact etiology of juvenile giant fibroadenoma is not known; hormonal influences are thought to be contributing factors. Excessive estrogen stimulation and/ or receptor sensitivity or reduced levels of oestrogen antagonist during puberty have been implicated in pathogenesis.

A wide variety of breast conditions such as phylloides tumour, virginal hypertrophy, lipoma, hamartoma, cyst, abscess and carcinoma can result in solitary or multiple giant masses. It is important to distinguish these pathological entities preoperatively as the treatment modalities and the prognosis differ quite significantly in these various conditions. Some of the lesions were treated by mastectomy, but some other lesions may require only local excision, aspiration, or conservative management. Phylloides tumour of breast is an uncommon fibroepithelial tumour with an epithelial and more cellular stromal components. They occur in all age groups, but are uncommon in adolescent, and are more likely to occur in women over 35 years. Phylloides tumour can be benign, borderline or malignant depending on histological features including stroma, cellularity, mitotic activity, and infiltration along tumour border. About 90% of the tumors are low grade or benign. It is treated by wide excision with a margin of normal tissue or mastectomy.

Virginal hypertrophy is rapid and distressing enlargement of one or both breasts, which is often asymmetrical. It is treated by reduction mammoplasty. Giant lipoma can cause unilateral breast hypertrophy. Soft mobile mass can be felt on palpation. Breast abscess developing during puberty causes sudden and rapid growth in the breast with pain and erythema. Although malignant tumors of the breast are rare in adolescent, two percent of all primary malignant lesions occur under the age of 25 years in female. Preoperative cytological examination is essential. Cytological diagnosis of phylloides tumor remains difficult with a significant overlap with fibroadenomas. The cytological smears of malignant phylloides tumour is quite easy and well established but the differential diagnosis between fibroadenomas and benign or borderline phylloides tumor is overlapping at times. Ultrasonography and mammography are two basic techniques for routine imaging in the diagnosis of breast diseases and Magnetic Resonance Imaging (MRI) allows exact evaluation of size and location.

A giant fibroadenoma should be excised as its increasing size may distort the shape of breast. Cosmetic consideration is important when making breast incisions specially in young girls.

IV. Conclusion

Fibroadenoma 5 cm or more in diameter is considered as giant fibroadenoma. Giant fibroadenoma is the most common cause of breast enlargement and causes asymmetry of breast in adolescent and young adult female. It can grow to huge proportion and compress the surrounding normal breast tissue. If giant fibroadenoma is diagnosed, surgical excision is necessary.

References

- [1]. Raganoonan C, Fairbairn JK, Williams S, Hughes LE. Giant breast tumours of adolescence. *Aust NZ J Surg*. 1987; 57:243-7.
- [2]. Bauer BS, Jones KM, Talbot CW. Mammary mass in the adolescent female. *Surg gynecol Obstet*. 1987; 165:63-5.
- [3]. Nikumbh DB, Desai SR, Madan PS, Patil NJ, Wader JV. Bilateral giant fibroadenomas of breast: A case report. *Patholog Res Int*. 2011;482046. Epub 2011 May 30.
- [4]. Rattan K, Kumar S, Dhull AK, Kaushal V, Kaur P. Giant Fibroadenoma Mimicking Phyllodes Tumor in a Young Female: A Cytological Dilemma. *The Internet Journal of Third World Medicine* 2008; 6:2.
- [5]. Kempson RL, Rouse RV. Juvenile fibroadenoma of breast. *Stanford School of Medicine*. Available from:
- [6]. <http://surgepathcriteria.stanford.edu/breast/juvifibroadenoma6>. Musio E, Mozingo D, Otchy DP. Multiple giant fibroadenoma. *American Surgeon* 1991; 57(7):438-41.
- [7]. Issam M. Giant fibroadenoma. Case report and review of literature. *Basrah Journal of surgery* 2006; 12:1-4.
- [8]. Muttarak M, Chaiwun B. Imaging of giant breast masses with pathological correlation. *Singapore Med J*. 2004; 45(3):132-9.
- [9]. Uygur F, Yigitler C. Rare juvenile giant fibroadenoma. *The journal of British Health* 2009; 5:164-6.
- [10]. Wurdinger S, Herzog AB, Fischer DR, Marx C, Raabe G, Schneider A, et al. Differentiation of phylloides breast tumors from fibroadenoma on MRI. *AJR Am J roentgenol*. 2005; 185:1317-21.
- [11]. Riham H, Khouli EL, Louie A. A Giant Fibroadenoma in the Guise of a Phylloides Tumor; characterization Role of MRI. *Semin Roentgenol*. 2009; 44(2):64-6.
- [12]. Chang DS, McGrath MH. Management of benign tumors of adolescent breast. *Plastic and Reconstructive Surgery* 2007; 120(1):13-17.
- [13]. Bandyopadhyay R, Nag D, Modak SK, Mukhopadhyay S, Roy S, Sinha SK. Distinction of phylloides tumor from fibroadenoma: Cytologists' perspective. *J Cytol*. 2010; 27(2):59-62.
- [14]. Mukhopadhyay M, Patra R, Mondal S, Ghosh A, Ray AK. Bilateral giant juvenile fibroadenoma of breasts. *J Indian Assoc Pediatr Surg*. 2009; 14(2):68-69.
- [15]. Gobbi D, Dall'igna P, Alaggio R, Nitti D, Cecchetto G. Giant fibroadenoma of the breast in adolescents: report of 2 cases. *Journal of Pediatric Surgery* 2009; 44:39-41.