

Left Side Ureterocele with Calculus: A Case Report

Sunita Nayak¹, Suren Prasad Dash², Muktikanta Khatua³

¹Tutor, Department of Anatomy, SCB Medical College, Cuttack, Odisha, India

²Consultant Radiologist, Sahara Diagnostics, Courtpeta Square, Berhampur, Odisha, India

³Assistant Surgeon, District Head Quarter Hospital, Koraput, Odisha, India

Abstract: An ureterocele is a congenital abnormality found in the ureter where the distal ureter balloons at its opening into the bladder, forming a sac-like pouch. It is most often associated with a duplicated collecting system, where two ureters drain their respective kidney instead of one. Ureteroceles occur in approximately 1 out of every 4,000 babies and are 10 times more common in girls than in boys with a left sided preponderance because a duplex collecting system (two ureters for one kidney) is more common in girls. This case report is about a 32 years old female patient complaining of lower abdominal pain, burning pain during micturation (dysuria), flank pain occasionally on left side and frequent urination. On USG and IVP x-ray, diagnosis was made as left renal hydronephrosis with left hydroureter due to left side intravesical ureterocele with left vesicoureteric calculus. With surgical unroofing of ureterocele and removal of calculus by crushing into pieces, patient became normal.

Keywords: Hydronephrosis, Hydroureter, Ureterocele, Vesicoureteric calculus.

I. Introduction

An ureterocele is a birth defect where the portion of the ureter closest to the bladder swells up like a balloon and the ureteral opening is often very tiny and can obstruct urine flow. This blockage can affect how the part of the kidney affected develops and works. It is most often associated with a duplicated collecting system, where two ureters drain their respective kidney instead of one. Ureteroceles occur in approximately 1 out of every 4,000 babies and are 5 times more common in girls than in boys with a left sided preponderance because a duplex collecting system (two ureters for one kidney) is more common in girls [1].

Types of ureterocele:-

Intravesical: Confined within the bladder

Ectopic: Some part extends to the bladder neck or urethra

Stenotic: Intravesical ureterocele with a narrow opening

Sphincteric: Ectopic ureterocele with an orifice distal to the bladder neck

Sphincterostenotic: Orifice is both stenotic and distal to the bladder neck

Cecoureterocele: Ectopic ureterocele that extends into the urethra, but the orifice is in the bladder

II. Case Presentation

32 years old female patient came with the chief complains of lower abdominal pain, burning pain during micturation (dysuria), flank pain occasionally on left side and frequent urination. She had no other complains. No past history of any chronic illness, hypertension or diabetes. Investigations report said: TWBC: 12.2×10^3 /cmm; ESR 04mm/1st hour, Hemoglobin: 10gm%. Differential count: Neutrophil-73%, Lymphocyte-25%, Eosinophil-04%, Basophil-01%, Monocyte-00%. Urinalysis revealed RBC and pus cells: 10 to13 per HPF.

Abdominal ultrasonogram: Left kidney mild hydronephrotic with dilated left ureter upto lower part. A cystic dilatation of left ureterovesical junction as a balloon like swelling which inflates and deflates with an interval in side urinary bladder (intravesical) along with an echogenic calculus at vesicoureteric junction (Fig. 1). On High definition color flow and color Doppler flow, a jet of urinary flow was seen entering when the balloon like structure inflates, indicating an ureterocele (Fig. 2).

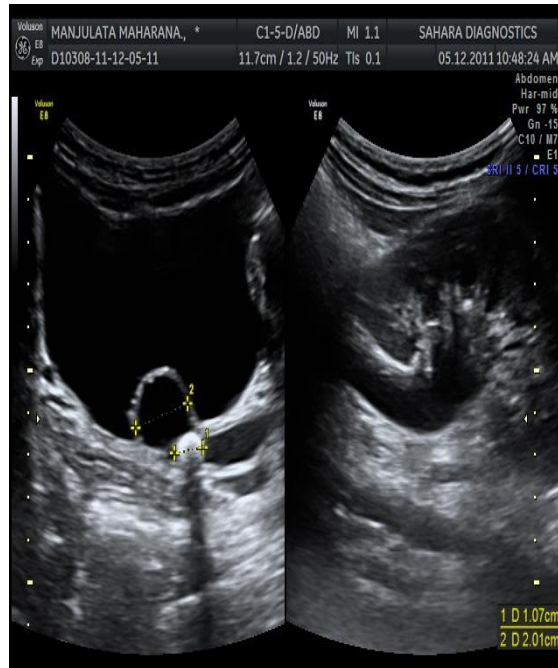


Fig.1. USG-ureterocele with calculus

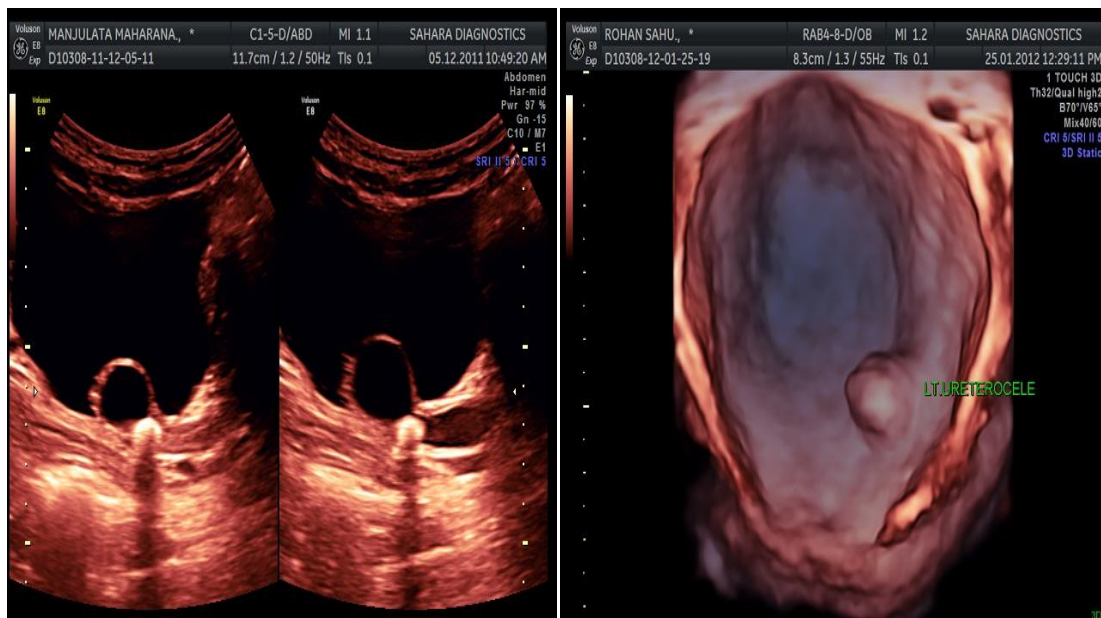


Fig.2. High definition Color flow Doppler showing ureterocele with calculus.

X-ray pyelogram: 40 ml of water soluble radio contrast dye (60% urograffin) injected through antecubital vein and radiographs were taken. Left renogram showed mild hydronephrosis with hydroureter and a dye filled balloon like swelling at left vesicoureteric junction seen (fig. 3). Right renogram: normal, suggestive of left side hydronephrosis with hydroureter and a left side ureterocele. No MRI or CT scan done.

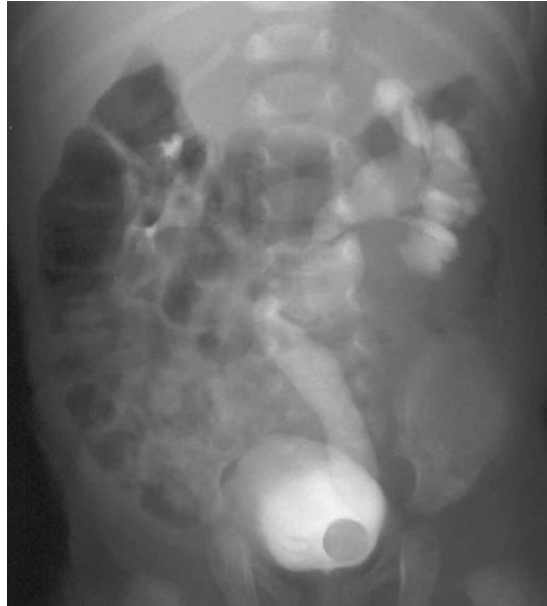

Fig.3: Intravenous pyelography.

After transeurethral unroofing and removal of calculi after crushing, patient was discharged uneventfully. She was advised for serial monitoring of renal function, periodic evaluation of voiding symptoms and bladder function. Interval radiologic studies to assess hydroureteronephrosis and vesicoureteral reflux were also advised.

III. Discussion

Ureterocele is the cystic dilatation of the distal ureter. It is a congenital developmental anomaly. Several theories of its origin have been proposed. These include abnormal muscular development of the distal ureter, leading to weakness and dilatation. Another theory is that an abnormal developmental stimulus is responsible for the dilation [1, 4]. However, the most accepted mechanism is the incomplete dissolution of the Chwelle's membrane, which is usually present before the 37th day of gestation as a division between the urogenital sinus and the developing ureteral bud. It is commonly associated with duplex upper tract and often ectopic [3]. It has varied effects as regards to obstruction, reflux, continence, and renal function. The incidence is 1:4000 children and occurs most frequently in females (5:1) and almost exclusively in the Caucasians [1, 3]. There are a few reports about the incidence in other races, and the incidence among Blacks is not known. It is unilateral in 80% of cases and bilateral in 10% of cases [4]. The single-system ureteroceles are usually found in adults and are thus termed "adult" ureterocele. These are usually less prone to obstruction and renal dysplasia associated with duplicated systems [2, 8, 9]. This will likely explain why the patient in this study presented late in adulthood (age range was 20-49 years, with a mean age of 31 years). Thus, the diagnosis was not suspected prior to radiological investigations. The late presentation is not only due to the rarity of the condition among Blacks but also because the patients were adults with a condition that commonly presents in early childhood. Ericsson in 1954 classified ureteroceles as either simple or ectopic. They may be associated with a single or double system. The simple type is usually associated with the single system while ectopic is associated with duplex system [2]. Subsequently, Stephens in 1958 characterized ureteroceles based on the nature of their opening as: stenotic (a narrowed intravesical opening), sphincteric (when the opening is into the bladder neck), sphincterostenotic (a narrowed opening into the bladder neck) and cecoureterocele (intravesical ureterocele with submucosal extension into the urethra) [1]. Ureteroceles have also been described as orthotopic or ectopic. These numerous classifications and terminologies are confusing. They are neither very clear nor helpful in guiding management decisions. In an attempt to eliminate the ambiguity, the committee on terminology, nomenclature, and classification of the section of urology of the American Academy of Pediatrics proposed standardized terms. They include: intravesical ureterocele (ureterocele contained wholly in the bladder); ectopic if any portion extends to the bladder neck or urethra; single or duplex systems and the orifices were termed as stenotic, sphincteric, sphincterostenotic, and cecoureterocele [4, 6]. In the study by Aas and Chtourou, six patients had unilateral ureterocele while four had bilateral, making a total of 14 ureteroceles. All the males had only unilateral lesions, while all the four bilateral lesions occurred in the female patients and the only patient with a duplex system with the ureterocele found in the ureter draining the upper pole was also a female. Thus, 93% of these patients had single-system ureterocele which is the typical "adult" type ureterocele [2, 9].

In childhood, diagnosis may be made following a child's presentation with recurrent UTI or urosepsis, incontinence, failure to thrive, urinary tract calculus, abdominal mass, bladder outlet obstruction and vaginal or urethral prolapse [10, 11]. "Adult" ureteroceles are less prone to obstruction and dysplasia [2] and thus are generally asymptomatic. This explains why they are detected in adulthood either incidentally or when a patient presents with recurrent flank pain, calculus or UTI. In this study, the presenting symptoms were flank pain and painful micturition, each occurring in 60% of the patients; fever and hematuria was the reason for presentation in 40% and 30% patients, respectively. A number of articles have reported ureteroceles associated with other genitourinary diseases; they have been called acquired ureteroceles and are commonly found in adults [2, 6, 7]. Ureteroceles associated with schistosomiasis was reported by Umerah [6] and Elem and Sinha [7]. Ultrasonography can confirm the diagnosis even in utero, as a cystic mass can be seen within the bladder or close to the proximal urethra [6]. Intravenous urography may demonstrate poor function on the affected side with delayed excretion or no excretion at all. It may also demonstrate hydroureteronephrosis, the dilated distal ureter becomes evident, appearing as a "cobra head" or "spring onion" deformity with peripheral halo [3, 5]. These findings were noted in the intravenous urograph (IVU). A voiding cystourethrogram (VCUG) demonstrates the size and location of the ureterocele as a filling defect or may demonstrate reflux into the ureters. Nuclear scan with DMSA (dimercapto succinic acid), DTPA (diethelene triamine pentaacetic acid) or MAG3 (Mercaptoacetyl triglycine) may demonstrate subtle changes in renal function and presence or absence of obstruction [11, 12, 13]. Early surgical intervention is required for cure and prevention of long-term sequelae [14]. The goals of treatment are the preservation of renal function and elimination of infection, obstruction or reflux. Surgical treatment can be endoscopic or open [14]. Endoscopic treatment includes transurethral puncture and transurethral incision; these are applicable mainly to the intravesical types and may be curative in up to 90% of cases [15, 16, 17]. The open procedures are often reserved for the more complex types. The operative procedures include upper pole nephrectomy and partial ureterectomy in cases associated with dysplastic upper pole in a duplicated system. Intravesical excision with common sheath reimplantation is done when the upper tracts are normal or there is no indication for partial nephrectomy [1, 14]. Treatment of the ureteroceles in this study was mainly by open method. The specific procedures included excision with ureteric reimplantation and incision with marsupialization. These patients require long-term follow-up to monitor renal function, symptoms and occurrence of vesicoureteric reflux, especially in patients treated with endoscopic method or simple open incision [14, 16].

IV. Conclusion

The prognosis of ureteroceles are related to the degree of associated reflux or obstruction. Depending on the size and position of a ureterocele, they may prolapse into the ureter causing complete bladder obstruction. Redundant collection systems are usually smaller in diameter than single and predispose the patient to impassable kidney stones. The effective "bladder within a bladder" compounds this problem by increasing the collision of uric acid particles, the process by which uric acid stones are formed. Ureteroceles is also associated with poor kidney function. It can cause frequent blockage of the ureter leading to serious kidney damage. In other cases, a small upper portion of the kidney is congenitally non-functional. Though often benign, this problem can necessitate the removal of non-functioning parts.

References

- [1]. Stephens FD. Aetiology of ureteroceles and effects of ureteroceles on the urethra. *Br J Urol* 1968; 40:483-7.
- [2]. Aas TN. Ureterocele. A clinical study of sixty-eight cases in fifty-two adults. *Br J Urol* 1960;32:133-44.
- [3]. Chwalla R. The process of formation of cystic dilatation of the vesical end of the ureter and of diverticula at the ureteral ostium. *Urol Cutan Rev* 1927;31:499-504.
- [4]. Jeffrey PW. Embryogenesis of ureteral anomalies: A unifying theory. *Aust N Z J Surg* 1988;58:631-8.
- [5]. Richard ES. Ureterocele. *Br J Surg* 1973;60:337-42.
- [6]. Umerah BC. The less familiar manifestations of Schistosomiasis of the urinary tract. *Br J Radiol* 1977;50:105-9.
- [7]. Elem B, Sinha SN. Ureterocele in Bilharziasis of the urinary tract. *Br J Urol* 1981;53:428-9.
- [8]. Tanagho EA. Anatomy and management of ureteroceles. *J Urol* 1972;107:729-36.
- [9]. Chtourou M, Sallami S, Rekik H, Binous MY, Kbaier I, Horchani A. Ureterocele in adults complicated with calculi: Diagnostic and therapeutic features. Report of 20 cases. *Prog Urol* 2002;12:1213-20.
- [10]. Hutch J, Chisholm ER. Surgical repair of ureterocele. *J Urol* 1996;96:445-50.
- [11]. Copley DE, Duckett JW. The modern approach to ureteroceles. *J Urol* 1995;153:166-71.
- [12]. Thompson GJ, Kelalis PP. Ureterocele: clinical appraisal of 176 cases. *J Urol* 1964;91:488-92.
- [13]. Conlin MJ, Skoog SJ, Tank ES. Current management of ureteroceles. *Urology* 1995;45:357-62.
- [14]. Byun E, Merguerian PA. A meta-analysis of surgical practice pattern in endoscopic management of ureteroceles. *J Urol* 2006;176:1871-7.
- [15]. Rickwood AM, Reiner I, Jones M, Pournaras C. Current management of duplex-system ureteroceles, experience with 41 patients. *Br J Urol* 1992;70:196.
- [16]. Monfort G, Morisson-Lacombe G, Coquet M. Endoscopic treatment of ureterocele revisited. *J Urol* 1985;133:1031-3.
- [17]. Blyth B, Passerini-Glazal G, Camuffo C, Snyder HM, Duckett JW. Endoscopic incision of ureteroceles: intravesical versus ectopic. *J Urol* 1993;149:556-9.