

A Morphological Study of the Superficial Palmar Arch in Human Foetuses of Manipuri Origin

G. Tempy Sangma¹, Purnabati S², Aribam Jaishree³, Rajkumari Ajita⁴, Ambath D. Momin⁵

Assist. Professor^{1,2}, Department of Anatomy, Regional Institute of Medical Sciences, Imphal, Manipur, India

Assoc. Professor^{3,4}, Department of Anatomy, Regional Institute of Medical Sciences, Imphal, Manipur, India

Senior Resident⁵, North Eastern Indira Gandhi Regional Institute of Health & Medical Sciences, Shillong

Abstract: Introduction: The study of superficial palmar arch (SPA) and its variation in human foetuses has been rarely reported. Superficial palmar arch is defined in textbooks as an arterial arcade that lies superficial in the palmar compartment in contact with the deep surface of the palmar aponeurosis. It is formed by the direct continuation of the ulnar artery beyond the flexor retinaculum. It is often not a complete arch, but it is complete if it becomes continuous with the superficial palmar branch of the radial artery.

Superficial and deep palmar arch are the main source of blood supply to the structures of the hand and they are commonly subjected to significant variations. The present study therefore was done in order to see the morphological variants in human foetuses and compare with the findings of the previous workers.

Materials and Methods: The study included 40 hands of foetuses both right and left obtained from the department of obstetrics and gynaecology, RIMS, Imphal. Study was conducted after clearance from the ethics committee. 20 foetuses ranging from 14 weeks to 40 weeks free from any malformations were dissected after fixing with 10% formalin.

Results: Among our specimens, 87.5% showed incomplete arch whereas in 2.5% complete type of morphology was observed. In 5% cases there was complete absence of SPA on both the sides and in 2.5% cases there was presence of median artery on the right side and the median artery takes part in the formation of SPA after joining the ulnar artery.

Conclusion: The present study has highlighted some of the variations of superficial palmar arch that we usually may come across and will be of immense help for clinicians, plastic surgeons in their reconstructive surgeries and in case of arterial repairs in children and adults.

Keywords: Superficial palmar arch, radial artery, ulnar artery, median artery.

I. Introduction

The variations of the SPA in adults is well known, and in humans it was first mentioned by Teidman as early as 1831, and the first detailed comparative study of the hands of humans and primates was done by Smith in 1910 [16]. The hand is the most important tool and has a rich vascular supply which is mostly by the superficial palmar arch and the deep palmar arch. Due to its superficial nature it is constantly exposed to hand injuries which may hamper its blood supply leading to necrosis and digital symptoms. The hand receives its major blood supply via superficial palmar arch which is subjected to variation [8]. The superficial palmar arch is the main terminal branch of the ulnar artery which gives rise to three common palmar digital arteries that anastomose with the palmar metacarpal arteries from the deep palmar arch. Each common palmar digital artery divides into a pair of proper palmar digital arteries, which run along the adjacent sides of the 2nd and 4th digits [13]. The radial side of index finger and thumb are supplied by Arteria Radialis Indicis (ARI) and Arteria Princeps Pollicis (APP) Romanes GJ [18].

Bilge et al classified the SPA as complete and incomplete when the arch is formed by either the single artery or between the constituting vessels which also agrees with the classification of Gellman et al [4,7].

Adachi B described three types of SPA, the type 1 (ulnar type), in which the arch is formed by the ulnar artery alone, type 2 (radio-ulnar type), which is considered the classical type and the type 3 (median ulnar or median radial type) in which the median artery forms part of the arch [1].

Coleman SS and Anson BJ classified the SPA in two groups. Group I and II[6].

Group I

Type A: classic type

Type B: SPA is completely formed by ulnar artery alone.

Type C: Mediano-Ulnar where the arch is formed by the ulnar artery and an enlarged, median artery

Type D: Radio-mediano-ulnar arch.

Type E: SPA is formed by ulnar artery and a vessel from deep arch.

Group II

Type A: There is no anastomosis between superficial branches of radial and ulnar arteries.

Type B: SPA formed by ulnar artery alone.

Type C: SPA formed by ulnar and median arteries without anastomosis.

Type D: SPA formed by ulnar, median and radial arteries without anastomosis.

In the present investigation, the objective was to study the morphological variants in human foetus and compare with the adult findings as described in the existing literature. Our study followed the classification of Coleman SS and Anson BJ.

II. Materials And Methods

The materials studied consisted of twenty foetuses of different gestational ages ranging from 14 weeks to 40 weeks, products of terminated pregnancy under MTP ACT of India, 1971 and stillbirths collected from the Department of Obstetrics and Gynaecology, RIMS, Imphal with permission from the local ethical committee. Only those foetuses which were free from any gross anatomical abnormality were selected for the present study. The age of the foetuses were calculated from the obstetrical history, crown rump length (CRL) and gross features. The foetuses were fixed in 10% formalin and then dissection of the hand was performed as per Cunningham's manual of practical anatomy. The hands were dissected from the level of cubital fossa till the web spaces in the palm and then skin and palmar aponeurosis reflected. The radial and ulnar artery were traced right from its origin upto the palm. The morphology of superficial palmar arch was studied, variations noted and then photographs were taken.

III. Observations And Results

For easier understanding foetuses were divided into four groups. Each group comprises of five foetuses. The groups were as follows;

Group I : 14 to 20 weeks

Group II : 21 to 26 weeks

Group III : 27 to 34 weeks

Group IV : 35 to 40 weeks

Group I: In these earliest group foetus, all the hands showed incomplete type of SPA (Group II, type B). Brachial artery terminates into radial and ulnar artery in the cubital fossa and the radial artery runs superficial in the forearm and on reaching the wrist curves dorsally and crosses the anatomical snuff box and the ulnar artery enters the hand superficial to the flexor retinaculum along with the ulnar nerve. The radial artery do not give off the superficial branch. The ulnar artery lies lateral to the nerve throughout its course and its superficial branch forms the SPA which gives off the three common digital arteries from the arch which again divides into into two proper digital arteries. The arch is not extended on the radial side and does not supply the thumb and index finger (fig 1). One 17 week old foetus of this group showed complete absence of superficial palmar arch on both the sides (fig 2).

Group II: Foetuses in these group also showed superficial palmar arch of incomplete form (Group II, type B). Ulnar artery alone forms the superficial palmar arch with no contribution from the radial artery. One 22 weeks old foetus of this group showed complete arch (Group I, type A) on the right side where the superficial palmar branch of ulnar artery joins with and the superficial palmar branch of the radial artery to form the arch. Arteria princeps pollicis (APP) and the Arteria Radialis Indicis (ARI) is given off by the superficial palmar arch and the common palmar digital arteries were also given off by the arch (fig 3).

Group III: The foetuses in these group also showed SPA of incomplete type. The superficial palmar branch which is the main termination of the ulnar artery forms the arch and do not supply the thumb and index finger (Group II, type B). However the arch gives off the three common digital arteries to supply the medial and the lateral sides of the second, third and fourth web spaces (fig 4).

Group IV: Median artery was present on the right side of one 38 week old foetus of these group. The median artery was taking origin from the ulnar artery in the proximal part of the forearm. The artery then pierced the median nerve from the posterior aspect and throughout its course in the forearm it lies anterior to the median nerve (fig 5). After reaching the palm the median artery crosses to the medial side and terminates by joining the ulnar artery to form the SPA and digital branches were given off by the ulnar part (Group I, type c). The same foetus on the left side showed formation of complete arch and Arteria Princeps Pollicis (APP) and Arteria Radialis Indicis (ARI) were given off by the arch (Group I, type B).

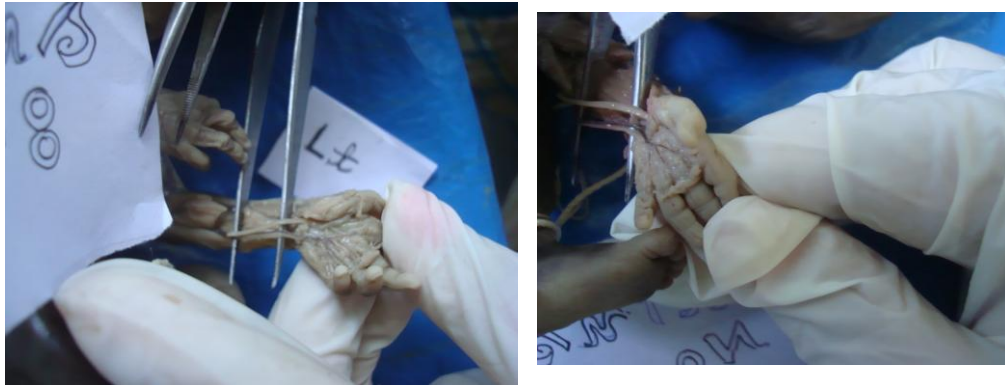

Fig 1: 20th week old foetus showing incomplete superficial palmar arch formed entirely by the ulnar artery.

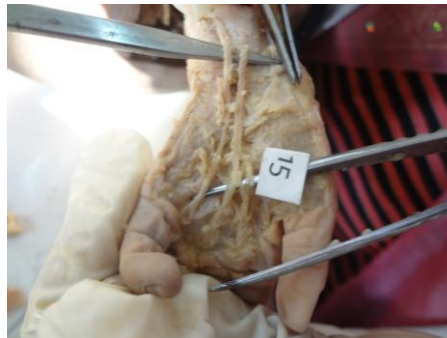


Fig 2: 17th week old foetus showing complete absence of superficial palmar arch.



Fig 3: Incomplete superficial palmar arch formed by anastomosis between ulnar artery and superficial branch of radial artery in 22 weeks old foetus.

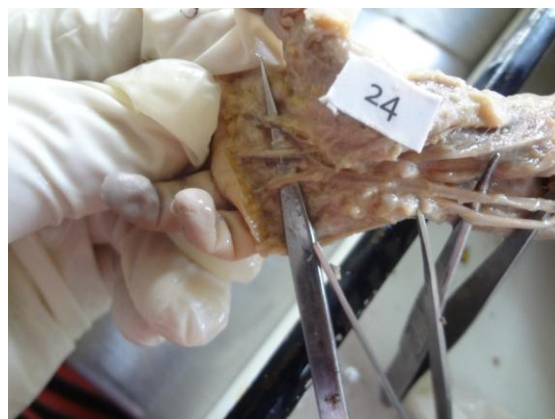

Fig 4: 34th week old foetus showing incomplete superficial palmar arch formed by ulnar artery.



Fig 5: 38th week old foetus showing the median artery piercing the median nerve.

IV. Discussion

Coleman SS and Anson BJ found the incidence of complete SPA in 78.5% and incomplete SPA in 21.5% cases out of 650 hands [6]. Ikeda et al reported complete SPA in 96.4% cases and incomplete SPA in 3.6% by performing stereoscopic arteriography in their study of 220 cadaver's hands [8]. Gellman et al found complete SPA in 84.4% and incomplete in 15.5% [7]., whereas in 500 cases studied by Janevski et al complete arches were seen in 75% and incomplete SPA in 25% [9]. In our present study of 40 hands incomplete SPA was in higher frequency (group II, type B) which was seen in 87.5% of the cases and complete SPA in 2.5% (group I, type B) and similarly Loukas M et al reported a case of SPA which had no contribution from radial artery and terminated by giving rise to common trunk for APP and AII [11]. In 2.5% cases, the SPA was classical type where both the ulnar and the radial artery takes part in forming the arch (group I, type A) and gives off the APP and ARI and is in accordance with the findings of Aniruddha et al in their study of 42 hands where incomplete SPA's were seen in 23 hands (54.76%) and complete SPA's in 19 hands (45.23%) [3]. Maher WP in a study of 50 pairs of foetal hands reported that there was no difference between the right and left hands of the foetuses but in our study some differences between right and left were observed [12].

Rodriguez et al describe the median artery as having two patterns, palmar and antebrachial where the former represents the embryonic pattern and the latter represents partial regression of the embryonic artery which is slender, short and terminates before reaching the wrist [16]. Sanudo JR et al describe the median artery as a transitory vessel which represents the arterial axis of the forearm during the early embryonic life and regresses in 2nd embryonic month and reported its incidences between 1.5% - 27.1% [20]. Patnaik VV et al reported a case of persistent median artery with formation of double SPA with one median artery acting as radial artery and another which joins the ulnar artery to form medio-ulnar type of complete SPA [14]. In the present study too the median artery takes part in forming complete SPA after joining the ulnar artery in 2.5% case and Al-Turk M and Metcalf WK also observed medio ulnar type in 4% of their cases [2]. SPA formed by the median artery and ulnar artery do not give off the ARI and APP [17].

In 5% of our study we observed the complete absence of SPA and Jaschtschinski in their study of 200 hands showed absence of SPA in 32% cases [10]. In cases where SPA was not found the lateral fingers are supplied by the superficial branch of radial artery. Clamping of the radial artery is contraindicated in cases of deficient collateral flow which may lead to complications like ischaemia and gangrene [15]. Ruengsakulrach R et al therefore suggested to be screened before harvesting the radial artery to confirm the presence of a viable collateral circulation in the hand [19]. Injury to SPA or ulnar artery can compromise the arterial supply of the fingers, especially if there is an insufficient anastomosis between the superficial and deep palmar arches [5].

V. Conclusion

From our study we conclude that formation of the arch can be subjected to variation right from the early foetal stage and therefore it would be helpful if follow up studies can be done in adults using Doppler ultrasonography, Allen test arterial angiography and avoid any hazards associated with them.

Acknowledgement

We thank all the unborn foetuses without which this present study would not have been successful.

References

- [1] Adachi B .Das arteriensystem der Japan, Kyoto.1928:365,368,389.
- [2] Al-turk, M and Metcalf, WK. A study of the superficial palmar arteries using Doppler ultrasonic flowmeter. *Journal of Anatomy*, 1984, 138, (1):27-32.
- [3] Aniruddha S, Sumita D, Kana D, Jayanta B. Handedness may be related to variations in palmar arterial arches in humans. *Singapore Medical Journal* 2012;53(6):409-412.
- [4] Bilge O., Pinar Y., Ozer M.A., Gonsa F. A morphometric study on the superficial palmar arch of the hand. *Surg. Rad. Anat* 2006;28:343-350.
- [5] Calenoff, L. Angiography of the hand: guidelines for interpretation. *Radiology*, 1972, 2, 331-335.
- [6] Coleman SS. and Anson BJ. Arterial patterns in the hand based upon a study of 650 specimens. *Surgery Gynaecology And Obstetrics*, 1961, 113, 409-424.
- [7] Gellman H., Botte M.J., Shankwiler J., Gelberman R. Arterial patterns of the deep and superficial palmar arches. *Clin. Orthop. Relat. Res*, 2001:383: 46-47.
- [8] Ikeda A., Ugawa A., Kazihara, Y. and Hamada, N. Arterial patterns in the hand based on a three-dimensional analysis of 220 cadaver hands. *The Journal of Hand Surgery*, 1988, 13, (4):501-509.
- [9] Janevski BK. Angiography of the upper extremity. The Hague, Martinus Nijhoff,1982; 73-122.
- [10] Jaschtschinski, S N. Morphologie and topographic des arcus volaris sublimus and profundus. *Anat. Hefte*, 1836;7:163-188.
- [11] Loukas M., Tubbs., Louis Jr.R.G., Apaydin N. Princeps pollicis artery arising from the superficial palmar arch. *Singapore Med Journal* 2009;50(11):e 391-392.
- [12] Maher WP. Palmar-digital arterial networks in fifty pairs of human fetal hands :Arteriographic models for clinical considerations. *Am.J.Anat* 1980;187:201-210.
- [13] Moore K .L., Dalley A.F (1999) *Clinically oriented Anatomy*,4thedn.Philadelphia: Lippincott, Williams and Wilkins.
- [14] Patnaik, VVG., Kalsey G, Singla R K. Superficial palmar arch duplication-a case report. *Journal of Anatomical Society of India*, 2000;49 (1):63-69.
- [15] Patnaik VVG., Kalsey G., Singla R K. Palmar arterial arches-A morphological study. *Jour. Anat .Soc. of India*, 2002;51 (2): 187-193.
- [16] Rodriguez-Niedenfuhr M., Burton GJ., Deu J.and Sanudo Jr.Development of the arterial pattern in the upper limb of staged human embryos: normal development and anatomic variation s. *Journal of Anatomy*, 2001,199,(4):407-417.
- [17] Rohini K.R and Dakshayani K.Unilateral Persistence of median Artery and its clinical Significance: *Anatomica Kartanaka*, 2011,5,(2):39-42.
- [18] Romanes GJ. *Cunningham's manual of Practical anatomy*.15th ed. Oxford: Oxford University Press,2005.1:74-104.
- [19] Ruengsakulrach R., Eizenberg N., Fahrer C., Fahrer M. and Buxton BF. Surgical implications of variations in hand collateral circulation: *Anatomy revisited. The journal of thoracic and cardiovascular Surgery*, 2001, 122,(4):682-686.
- [20] Sanudo JR, Chikwe J, Evans SE. Anamolous median nerve associated with persistent median artery. *J Anat*, 1994; 185:447-451.