

## A Study on Management of both bones forearm fractures with Dynamic compression plate

Dr. Addepalli Srinivasa Rao, M.S, M.ch, Dr. C. V. Dasaraiah M.S.,  
Dr. Meeravali M.S

Department of Orthopaedics, Siddhartha Medical College, Vijayawada, Andhrapradesh, India 520008

---

### **Abstract:**

**Background:** We undertook a study on management of diaphyseal fractures of both bones forearm by internal fixation with dynamic compression plate.

**Materials and Methods:** This is a prospective study in which 56 cases of diaphyseal fractures both bones forearm in adults were treated in Government General Hospital, Vijayawada. The average age ranged between 21-30 years. The patients were assessed for fracture union, function and complications.

**Results:** The range of movements and grip strength is good. Excellent result was obtained in 42 cases (75%), good in 7 cases (12.5%), fair result in 7 cases (12.5%). Infection occurred in one case and delayed union occurred in one case.

**Conclusion:** open reduction and internal fixation is the treatment of choice for diaphyseal fracture both bones forearm and dynamic compression plating is an effective treatment option for fractures of both bones of forearm

**Keywords:** both bones, diaphyseal, forearm, fracture, fixation, dynamic compression plate

---

### I. Introduction

It is essential to regain length, apposition, axial alignment and normal rotational alignment while treating diaphyseal fractures of radius and ulna to gain good range of pronation and supination. The chances for malunion and nonunion are greater because of the difficulties in reducing and maintaining the reduction of two parallel bones in the presence of pronating and supinating muscles, which have angulatory as well as rotator influences. Open reduction and internal fixation with plating is generally accepted as the best treatment for displaced diaphyseal fractures in the adult. The value of compression in obtaining rigid internal fixation had been noted by various authors. Compression techniques have a lower incidence of nonunion and are found to hasten rehabilitation, with joint stiffness. Plating entails a sufficiently stable fixation of the bone fragments, allowing early mobilization.

The ideal management of fracture is a solidly united fracture in the perfect anatomical alignment, stable internal fixation, preservation of blood supply to the fragments and soft tissue and early active pain free mobilization of the muscle and joints to prevent development of fracture disease.

The intention of rehabilitating the patient at an earliest possible time and the unsatisfactory outcome of the conservative treatment of the fracture of the both bone of the fore arm in adults promoted us to make an attempt to treat the fractures by open reduction and internal fixation using implants.

### II. Materials And Methods

This prospective study conducted from August 2008 to October 2010, consists of 56 patients of fracture of both bones of forearm, who gave informed consent. The ethical clearance was obtained from institutional ethics committee. Inclusion criteria were (1) displaced diaphyseal fractures of both bones of forearm in adults. (2) closed or type I compound diaphyseal fractures of both bones of forearm. (3) competent neurological and vascular status of the affected extremity. Exclusion criteria were (1) fractures of both bones of forearm in children (2) fractures of either ends of radius and ulna. (3) type II and III open fractures. Cases with pathological fracture and, history of long term steroid therapy were excluded from this study.

There were 46 males (82%) and 10 females (18%), with an average age 30 years (range 16-60 years). 48 cases (86%) of the cases were simple and 8 cases (14%) were compound fractures. 37 cases (66%) had fractures on the right side and 19 cases (34%) had fractures on the left side. The fractures were classified according to AO/ASIF alpha numeric classification system. 8 cases (14%) had fractures in the upper one third, 34 cases (61%) had fractures in the middle one third, 14 cases (25%) had fractures in the lower one third. All the cases underwent open reduction and internal fixation under brachial block or general anesthesia, under tourniquet control with the patient in supine position and the radius fractures were approached either by Thompson's approach or Henry's approach, the ulnar fractures by standard posterior subcutaneous approach and the fractures were fixed with 3.5mm dynamic compression plate employing the surgical techniques described by the

AO/ASIF group. Posterior plaster slab was applied for 2 weeks until the stitches were removed and was continued for 4 weeks in cases of comminuted fractures.

**Table 1: Fracture pattern based on AO classification**

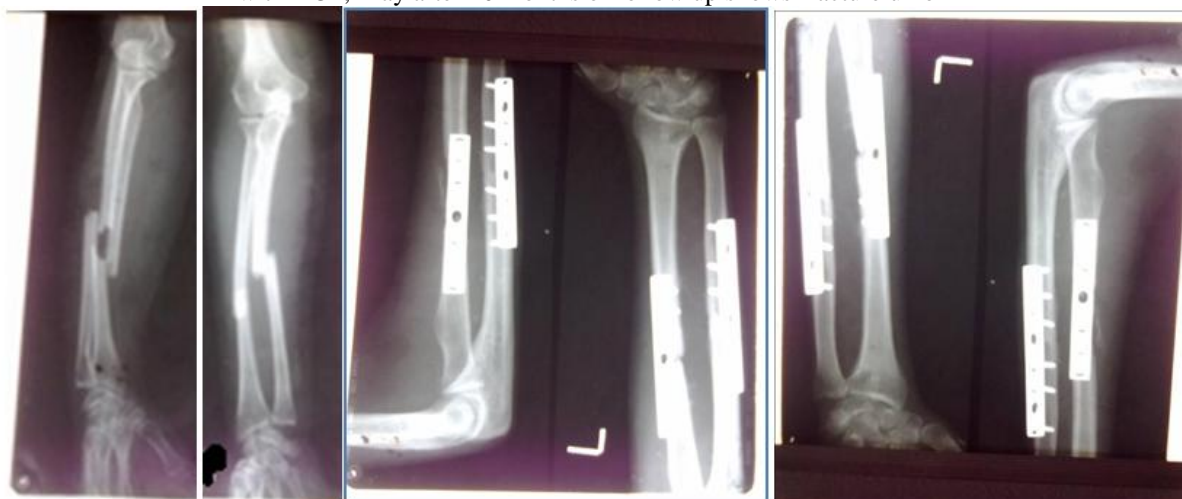AO type	Number of patients
22 – A3	33
22 – B3	18
22 – C3	5

The patients were followed up clinico-radiologically for a minimum period of 6 months. Initially the patients were evaluated every 3-4 weeks intervals for the first 3 months, every 6 weeks thereafter for 3 months, and then at 3 monthly intervals. The results were evaluated on the basis of fracture union, range of movements, muscle (grip) strength and complications. The functional outcome was assessed using the criteria of Anderson et al. The complications were evaluated in terms of infections (superficial/deep), nonunion, synostosis, implant loosening and secondary loss of reduction, refracture.

**Table 2: Anderson et al criteria for assessment of functional outcome**

Result	Union	Flexion and extension at wrist joint	Supination and pronation
Excellent	Present	<10° loss	<25% loss
Good	Present	<20° loss	< 50% loss
Fair	Present	<30° loss	>50% loss
Poor	Nonunion with or without loss of motion		

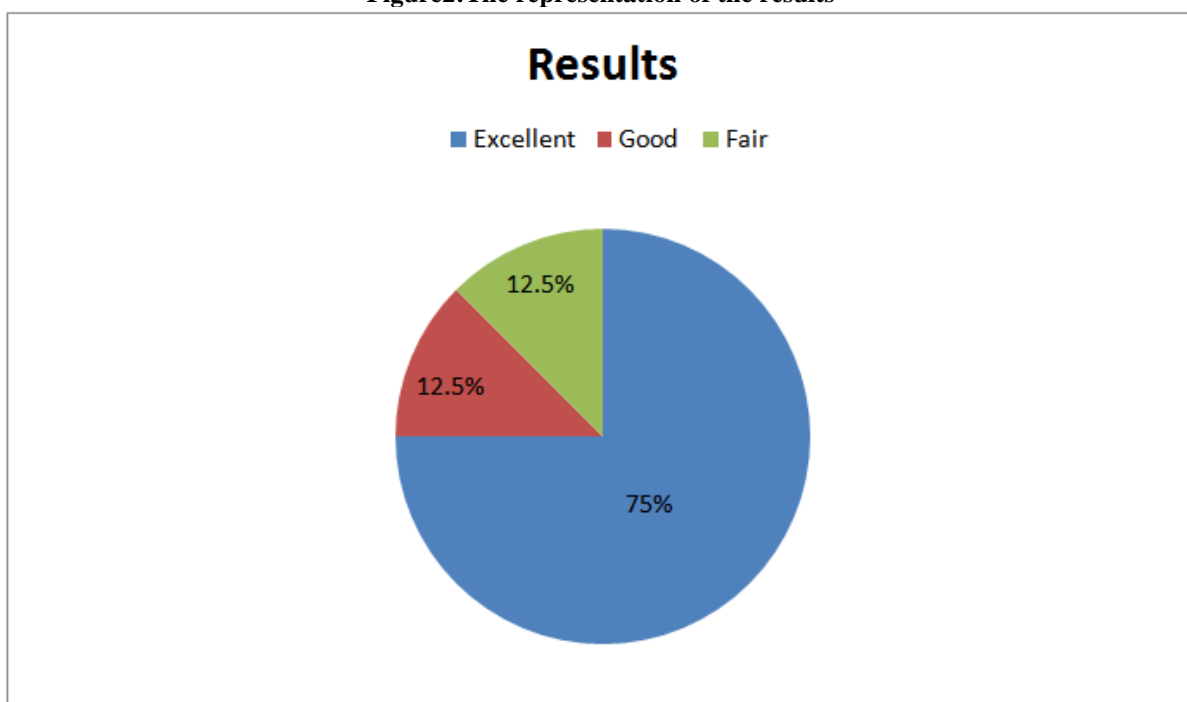
**Figure 1:** Preoperative x-ray shows fracture of both bones, immediate postoperative x-ray following fixation with DCP, x-ray after 10 months of follow up shows fracture union



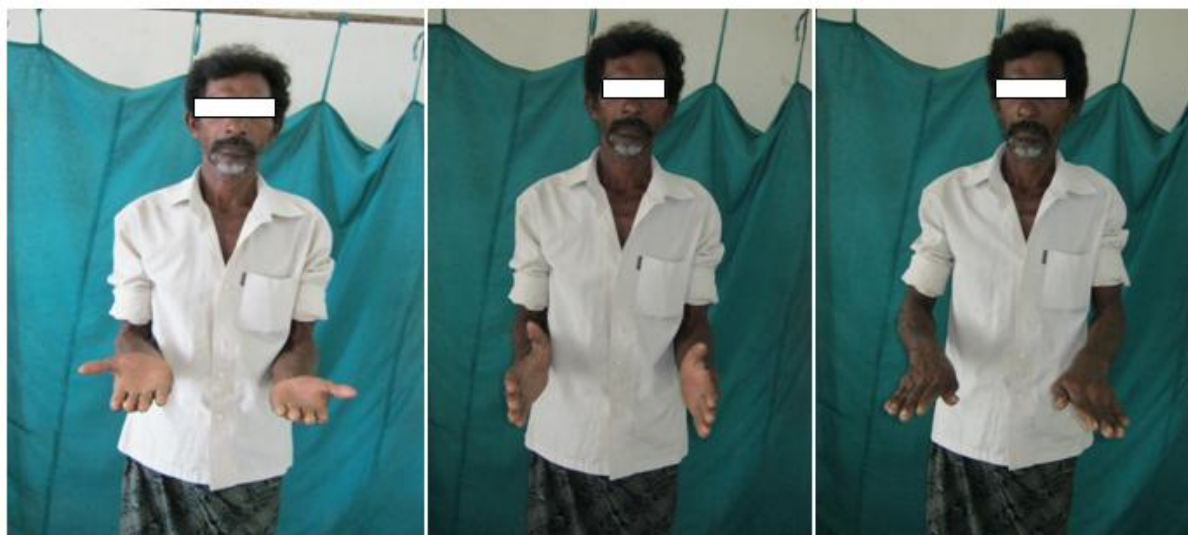### III. Results

Criteria of Anderson et al was followed for assessment of functional outcome. Fractures of both bones of forearm united in 10 to 24 weeks (average of 12 weeks) time. Excellent result was obtained in 42 cases (75%), good in 7 cases (12.5%), fair result in 7 cases (12.5%). Infection occurred in one case and delayed union occurred in one case.

**Figure2: The representation of the results**



**Figure 3:** clinical photo showing follow up at 10 months with full range of supination and pronation



#### **IV. Discussion**

Open reduction and internal fixation is a treatment of choice for the majority of the diaphyseal fractures of the both bones forearm in adult. While reducing the fractures it is important to correct the angulation, radial bowing and rotation deformities.

The axis of rotation of the forearm bones extends from centre of the head of the radius to the insertion of the triangular fibro cartilage at the base of the styloid process of the ulna. If the relation of the forearm axis is altered by angulation the mechanism of the radio-ulnar joint is deranged and permanent limitation of the rotation will occur. Rotational deformities will also limit the radio-ulnar movement. The supinator muscles are inserted proximally and the pronators are inserted distally. Consequently the fracture of midshaft of the radius takes place.

The proximal fragment supinates and the distal fragment pronates which is seen in the X-Ray as a striking discrepancy in the width of the interosseous space between the proximal and distal fragments, intramedullary space and cortical thickness of proximal and distal fragments

Open reduction and internal fixation is always recommended in these cases as the maintenance of the reduction in plaster casing is difficult as there is every chance of displacement to occur.

In this series out of 56 cases 49(87.5%) cases are graded excellent and good; fair 7(12.5%) cases and 7 cases were immobilized with above elbow slab and bandage, delayed union 1 case, infection in 1 case.

DANAM STREET M.D. in his series, he has treated 137 cases of fracture both bones of forearm with square nails. He followed 103 cases out of 103 cases 86(83.5%) cases are excellent and good, unsatisfactory 8(8%) cases and failure 9(8.5%) cases.

P.N.ROY & R.N.SARMA in their series they did open reduction and internal fixation 28 cases, out of 37 cases fracture both bones with DCP, Out of 37 cases 32(78%) cases are excellent and good; fair 4(10%) cases and Poor 1(2%) cases.

Dr.KIRIT et al in 1998 they did internal fixation by using 4.5 semi tubular plates and 3.5 DCP in 134 patients. Out of 134 cases 124(92%) cases are excellent and good, unsatisfactory 6 (4%) cases and failures 4(3%) cases.

### **Timing of operation**

Operative intervention for the forearm fractures better to be carried out between 7 & 14 days from the time of injury. By that time the initial edema subsided much soft tissue damage gets healed. The operation can be performed on a routine list in the best available time as an elective procedure.

## **V. Conclusions**

Our study has proven that open reduction and internal fixation of diaphyseal fractures of radius and ulna can be best done with dynamic compression plating technique which has given an excellent to good result. The complications of the procedure are negligible. The outcome is determined by principles of proper plating. The soft tissue care is utmost important i.e. minimum periosteal stripping on the surface of the bone on which plate is applied. This maintains optimal vascularity at the fracture site. Proper preoperative planning, operative technique and postoperative rehabilitation program are key points for the excellent outcome. All the fractures of both bones forearm can be treated by open reduction and internal fixation with dynamic compression plating to obtain sound union and good range of movements.

## **References**

- [1]. Age, F.P. Medullary : Fixation of fractures of the forearm, J.B.J.S. 41-A, 1948,1959
- [2]. C.A.Gold Farg et al (2005) – Functional outcome after fracture of both bones of the forearm fixed with DC plates – JBJS-Vol87-B,3,374,379
- [3]. Campbell Vol.III Tenth Edition 1998
- [4]. Chick G, Courtc, Nordinjy – Complex fractures of the radius and ulna in adults- Revchir Orthop reopractic a parmit,2001, Dec;87(3)773-85 Franch
- [5]. Clinical Orthopaedics and Research; Nov.1986, J.B.J.S. 39-A,91,1957
- [6]. Clinical Orthopaedics India, November 1988
- [7]. Clinical Orthopaedics November , 1986.
- [8]. Cooden: Internal Fixation of Fractures forearm J.B.J.S.43A-1115,1961
- [9]. Crekss – The management of Forearm Injuries, Orthopedic Clinics, North America 4:969:1973
- [10]. Dodge H.S. & Cady G.W. – treatment of fractures of radius and ulna with Dynamic compression plates
- [11]. Droll KP, Pernap, Poltar J, Hamiman E, Schemikietec Mc Ker MD – Outcome following plate fixation of fractures of both bones of forearm in adults – JBJS AM 2007, Dec J9(12):2619-24
- [12]. Ducan R, Geiss Ler W, Freel and AE , Savoie FH et al – Immediate internal fixation of open fractures of diaphyseal of the forearm. J Orthop fractures 1992;6(1):25-31.
- [13]. Fernandez Delloca AA, Masilah galanta R – Osteosynthesis of diaphyseal fractures of the radius and ulna using plates – Injy.2001 Sept32:2:1344-50
- [14]. Franktuil et al – Functional outcome after ORIF of both bone forearm – <http://www.hwbf.org/OTA/am/OTA02/OTAPG/OTA2070.html>
- [15]. Grace T.C. and Enors Mann , W.W. Jr.1 – Forearm fractures, treatment by Rigid Fixation with early motion –J.B.J.S.62-A, 433:1980
- [16]. Hansk, Uhtoff, Philippe Poisras and Devdas Backman et al – Internal plate fixation of fractures both bones forearm. J Orthop sci (2006) 11:118-126 DOI 10.1007/s00776-005-0984-7
- [17]. Herman MJ, Marshall ST et al : Forearm fractures in children and adolescents : A practical approach – Hand clin.2006Feb;22(1):55-67
- [18]. Hertel R, Pisian M, Lambests, Ballmer F7- Plate osteosynthesis of diaphyseal fractures of radius and ulna –Injy-1996Oct;27(8):545-8
- [19]. Janos Pearl et al : Middle third forearm fractures : Treatment by DC Plates Webmed Jan8,2010
- [20]. Knight R.A. & Purvis G.D. : Fracture of both bones of the Forearm in adults, J.B.J.S.,31-A, 755,1949.
- [21]. Maantyre NR, Ilyas et al : Treatment of Fore arm fractures : Actachir Octachir Orthop traumatol cech.2009 Feb
- [22]. Marek F.M. Axial Fixation of forearm fractures – J.B.J.S. 43-A, 1099, 1961Feb:110(1)60-5
- [23]. Marek F.M. Axial Fixation of forearm fractures – J.B.J.S. 43-A, 1099, 1961
- [24]. Muss JP, Bynum DK, et al : Diaphyseal fractures of the radius and ulna in adults- Hand clin.2007 May :23(2):143-51
- [25]. Naiman, P.T.Schein, A>J & Stiffered R.S. – Use of A.O. – Compression plate in selected fractures of forearm – A preliminary of clinical orthopedics : 71:208:1970

- [26]. P.V.Solanki et al – Effect of early mobilization of grip strength pich strength and work of hand muscles in case of closed diaphyseal fractures of radius –ulna treated with dynamic compression plating 2000-46-2-84-7
- [27]. Rush L.V. & Rush H.L. : A technique for longitudinal pin fixation of certain fractures of ulna, J.B.J.S. 21:619:1939
- [28]. Stevens CT, Tennis HJ : Plate osteosynthesis of simple forearm fractures – Actaorthop Belg 2008 Apr:74(2):180-3
- [29]. Sudietz, Muller LP, Gercele E et al : Volar and dorsal midshaft forearm plating DCP and LC DCP Actachir Belg 2010 Jan-Feb:110(1)60-5