

Photodynamic therapy as an adjunct to scaling and root planing in treatment of chronic periodontitis patients: A clinical study

Dr.Chetan Raut¹, Dr.Kunal.S.Sethi²

¹P.G.Student,Department of Peridontics,MGV's KBH Dental College &Hospital,Nasik,India

²Professor and guide,Department of Peridontics, MGV's KBH Dental College &Hospital, Nasik, India

Abstract:Recent research data have suggested a potential benefit of photodynamic therapy (PDT) in the treatment of periodontitis. However, there is very limited data from controlled clinical trials evaluating the effect of PDT in the treatment of periodontitis. The aim of this study was to evaluate the clinical effects of the adjunctive use of PDT to scaling and root planing in chronic periodontitis patients. Thirty-four sites with chronic periodontitis were randomly treated with scaling and root planing followed by a single episode of PDT (test) or scaling and root planing alone (control). Bleeding score using Sulcular bleeding index 1971, probing depth (PD), gingival recession (GR), and clinical attachment level (CAL) were measured at baseline and 21 days after therapy. At 21 days post-operative, significant differences between the groups with regards to Clinical attachment level, Pocket probing depth, Full mouth bleeding scores were observed.

Conclusion: The additional application of a single episode of PDT to scaling and root planing results in an additional improvement in terms of Pocket depth reduction and Clinical attachment level gain, but it resulted in a significantly higher reduction in bleeding scores compared to scaling and root planing alone.

Keywords: Photodynamic Therapy, Photosensitisers, Periodontitis, Scaling & Root Planing.

I. Introduction:

Periodontitis is a multifactorial disease that is associated with loss of the supporting tissues (i.e., periodontal ligament and alveolar bone) around the tooth.¹ A major objective of periodontal therapy is to remove soft and hard, supragingival and subgingival deposits from the root surface to stop disease progression. Numerous studies have reported significant improvements in clinical and microbial parameters following non-surgical periodontal therapy that is the scaling and root planing. To further enhance the effectiveness of scaling and root planing (SRP), power-driven instruments, such as sonic and ultrasonic scalers, have been introduced. Despite the fact that non-surgical periodontal treatment may result in significant clinical improvements in the great majority of cases, none of the currently available instrumentation techniques are effective in completely eliminating subgingival bacteria and calculus.² These limitations could be attributed to several factors, such as the complex anatomy of teeth (i.e., furcation-involved teeth) and mechanical limitations related to the size of instruments or invasion of periodontal pathogens into the surrounding soft tissues or possible re-colonization of periodontal pockets from other diseased sites or intraoral niches.³

Photodynamic therapy (PDT), also called photoradiation therapy, phototherapy, or photochemotherapy, was introduced in medical therapy in 1904 as the light-induced inactivation of cells, microorganisms, or molecules.⁴ PDT involves the combination of visible light, usually with a diode laser and a photosensitizer. The photosensitizer is a compound that is capable of absorbing light of a specific wavelength and transforming it into useful energy.⁵ Each factor is harmless by itself, but when combined they can produce lethal cytotoxic agents that can selectively destroy cells. Thus, PDT may represent a promising alternative for reducing the bacterial load or even for eradicating certain periodontal pathogens.

Briefly, upon illumination, the photosensitizer is excited from the ground state to the triplet state.¹⁵ The longer life time of the triplet state enables the interaction of the excited photosensitizer with the surrounding molecules, and it is generally accepted that the generation of the cytotoxic species produced during PDT occurs while in this state. The cytotoxic product, usually O₂, cannot migrate >0.02 mm after its formation, thus making it ideal for the local application of PDT without endangering distant molecules, cells, or organs.⁶

Experimental examinations revealed that light from a helium/neon (He/Ne) laser or a gallium-aluminium arsenide laser, in combination with appropriate photosensitizers, resulted in a significant reduction in the viability of aerobic and anaerobic bacteria in a solution of subgingival plaque from subjects with chronic periodontitis.^{7,8} It was also demonstrated that bacteria associated with periodontal disease can be killed through photosensitization with toluidine blue O and irradiation with an He/Ne soft laser.

Most of the sensitizers used for medical purposes belong to the following basic structures.⁹

- Tricyclic dyes with different meso-atoms. Acridine orange, proflavine, riboflavin, methylene blue, fluorescein, eosine, erythrosine, rose Bengal
- Tetrapyrroles. Porphyrins and derivatives, chlorophyll, phylloerythrin, phthalocyanines

- Furocoumarins. Psoralen and its methoxy-derivatives xanthotoxin, bergaptene

Recently a new photosensitizer called Indocyanine green (ICG), a tri-carbocyanine that belongs to family of cyanine dyes has been developed.¹⁰ It is widely used in the fields of Ophthalmology and Cardiac imaging. Recent in vitro studies have reported its efficacy in killing potent periodontal pathogens like *A. actinomycetemcomitans* and *P. gingivalis* when combined with 810 nm diode laser.

Therefore, the aim of the present prospective, controlled clinical study was to clinically evaluate the effectiveness of the adjunctive use of PDT to scaling and root planing in treatment of chronic periodontitis patients.

II. Materials And Methods

2.1 Subject Selection

The study included total of five subjects (2 Males, 3 females) with chronic periodontitis, who were referred for treatment at the Department of Periodontology, MGVS KBH Dental college and hospital, NASHIK. Patients were included in the study after having signed an informed consent. In this five subjects 34 intraoral sites with a pocket depths ≥ 4 mm were selected for the study and randomly divided into two groups which were Scaling and root planing group (control) and photodynamic therapy plus scaling & root planing group (test group). Criteria for subject selection were patients diagnosed with chronic periodontitis, no treatment of periodontitis for the last 6 months, no systemic diseases that could influence the outcome of the therapy, no pregnancy, and no use of antibiotics for the 12 months prior to treatment, patients not allergic to the photosensitizer used.

The following clinical parameters were assessed at baseline and at 21 days after active periodontal therapy using the same type of periodontal probe:

Bleeding Score using Sulcular bleeding index by Muhlemann 1971,

Probing depth (PD),

Gingival Recession (GR) &

Clinical attachment level (CAL).

All clinical measurements were made at four sites per tooth: mesio-facial, mid-facial, disto-facial, palatal/lingual by the same examiner. The cement-enamel junction (CEJ) was used as the reference point.

2.2 Study Design

The study performed was a randomized clinical trial. Treatment allocation was performed by a lottery method. All subjects were treated with SRP ultra-sonic instrumentation followed by a single episode of Photodynamic therapy in test group or only SRP using ultra-sonic instrumentation in control group. Oral hygiene instruction individualized for every subject was given at the first appointment. It was followed by initial periodontal treatment for test and control groups until the operator believed that the root surfaces were adequately debrided and planed. Randomization was performed immediately following the completion of instrumentation.

2.3 Treatment procedure:

In the test group, the photosensitizer liquid that is indocyanine green dye was applied with a blunt needle to the instrumented sites, starting from the apical end of the pocket and moving coronally to avoid entrapment of air bubbles. One minute later, all pockets were thoroughly rinsed with sterile saline to remove the excess photosensitizer. Immediately after rinsing, the diode laser, with 810 nm wavelength and 0.8 W of power output, equipped with a probe tip, was placed at the depth of the pocket and moved circumferentially around the tooth for 30 seconds, according to the manufacturer's instructions. The subjects returned at 21 days post SRP for evaluation. After clinical measurements were performed, the subjects received one session of prophylaxis, including reinforcement of oral hygiene, supragingival debridement, and tooth polishing.

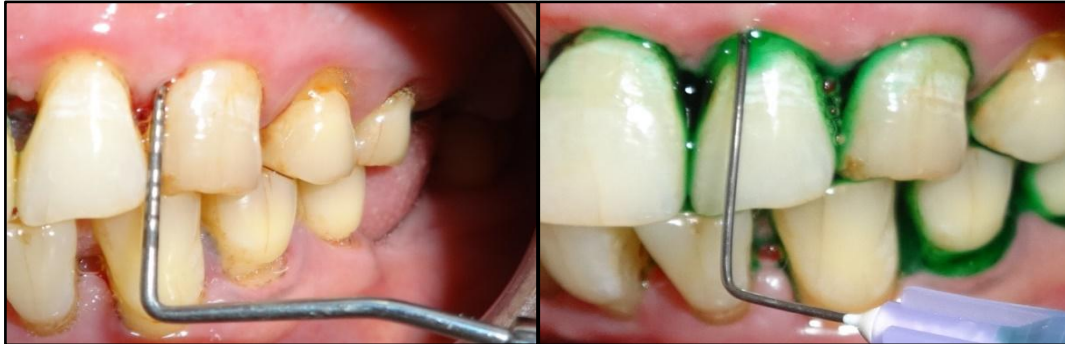

fig.1

fig.2

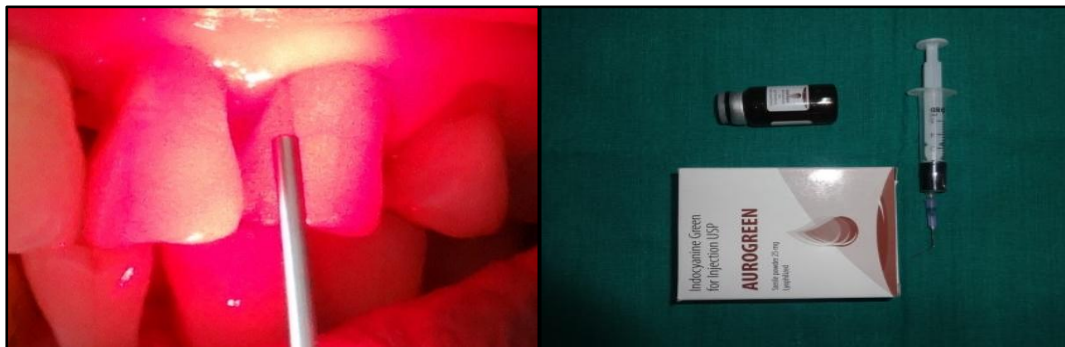


fig.3

fig.4

III. Results:

Table (1) shows the mean scores of probing pocket depth,gingival recession and clinical attachment level at baseline for both test and the control group.

Table (2) shows the mean scores of the three clinical parameters at 21 days follow-up. Mean scores of probing pocket depth was 4.97 for the test group and 5.38 for the control group where the recession for the test group and the control group was 1.14 and 0.94 mm respectively.Clinical attachment level was 6.1mm for the test group and 6.2 mm for the control group. Results showed that the probing depth was reduced to 3.14mm in test group and 4.14 mm in control group,whereas the gingival recession was seen to increase from 1.14 to 1.5 in test group and 0.94 to 1.13 in control group.Clinical attachment level was also reduced to 4.7mm and 5.4mm in both test group and control group respectively.

Table (3) shows the mean bleeding scores for both test group and the control group at the baseline and at 21 days follow-up. It was reduced to 0.57 in test group whereas in the control group it was reduced to 1.14.

1.Mean probing depth, gingival recession and clinical attachment level (in mm) at baseline

	Test Group	Control Group
Pocket depth	4.97	5.38
Clinical attachment level	6.11	6.24
Gingival recession	1.14	0.94

2.Mean probing depth,gingival recession and clinical attachment level (in mm) 21 days follow-up.

	Test Group	Control Group
Pocket depth	3.14	4.14
Clinical attachment level	4.70	5.47
Gingival recession	1.55	1.32

3.Changes in bleeding scores in both the groups at baseline and 21 days follow up.

	Test Group	Control Group
BASELINE	3.28	3.14
21 DAYS	0.57	1.14

IV. Discussion:

The current clinical study has investigated the role of PDT combined with scaling and root planing in treating chronic periodontitis. A short term evaluation period of 21 days was selected in present study assessing the efficacy of various adjunctive treatment modalities to SRP as adopted in various interventional studies. It has been reported that greatest reduction in Probing depth and gain in CAL occurs within a month after SRP. However longer follow-up could have resulted in more definitive results.

Earlier research has revealed that PDT in association with non-surgical debridement achieved higher reductions in PPD and gains in CAL in non-furcated teeth.^{11,12} The positive clinical outcomes obtained in the control group in the present study are in agreement with the previously reported findings on the clinical efficacy of subgingival debridement in the treatment of chronic periodontitis, which showed that in subjects with chronic periodontitis, subgingival debridement in conjunction with supragingival plaque control was effective in reducing PD and improving CAL.¹³⁻¹⁹

For the elimination of bacteria in supragingival and subgingival plaque, antimicrobial photodynamic therapy has been applied with various combinations of lasers and photosensitizing agents. In antimicrobial photodynamic therapy, the particular photosensitizers employed are toluidine blue O, methylene blue, phenothiazine chloride. However due to certain disadvantages of conventional photosensitizers, recently developed dye called Indocyanine green dye was used in present study which is well-known in liver function tests, ophthalmology and oncology. Indocyanine green is an anionic photosensitizer which is activated at 810 nm and leads to photo-oxidation. ICG is not resorbed by the intestinal mucosa, which is why the danger of uncontrolled swallowing of the material is non-existent. The metabolization of indocyanine green occurs microsomally in the liver and is excreted only via liver and the pancreatic ducts. ICG is of a low toxicity. LD50 values in animals were 60 mg/kg in mice and 87 mg/kg in rats.

In this study reduction in PPD and gain in CAL were seen, along with significant reduction in bleeding scores. However there was also some increase in the gingival recession in both test and control group. The mean PPD reduction for test and control group was 1.63 and 1.24 respectively. The mean CAL gain for test group and control group was 1.4 and 0.8 respectively. Gingival recession scores for test group was increased from 1.14 to 1.5 and for the control groups the respective numbers were 0.94 to 1.3. The bleeding scores for the test group was reduced from 3.28 to 0.57 in the test whereas in the control group it was reduced from 3.14 to 1.14.

V. Conclusion:

Within its limits, the present study showed that the addition of a single episode of PDT to SRP resulted in an improvement in terms of PD reduction and CAL gain, but it resulted in a significantly greater reduction in bleeding scores compared to SRP alone. Present study being a preliminary intervention had certain limitations like short sample size and short duration of evaluation. Also microbial parameters were not assessed to support the clinical findings. Further studies are needed if PDT application can be considered as an adjunct to Scaling and root planing.

References

- [1]. Page RC, Offenbacher S, Schroeder HE, Seymour GJ, Kornman KS. Advances in the pathogenesis of periodontitis: Summary of developments, clinical implications and future directions. *Periodontol 2000* 1997;14:216-248.
- [2]. Adriaens PA, Adriaens LM. Effects of nonsurgical periodontal therapy on hard and soft tissues. *Periodontol 2000* 2004;36:121-145.
- [3]. Umeda M, Takeuchi Y, Noguchi K, Huang Y, Koshy G, Ishikawa I. Effects of nonsurgical periodontal therapy on the microbiota. *Periodontol 2000* 2004;36:98-120.
- [4]. Von Tappeiner H, Jodlbauer A. On the effect of photodynamic (fluorescent) substances on protozoa and enzymes (in German). *Deutsch Arch Klin Medizin* 1904;39:427-87.
- [5]. Sharman WM, Allen CM, van Lier JE. Photodynamic therapeutics: Basic principles and clinical applications. *Drug Discov Today* 1999;4:507-517.
- [6]. Moan J, Berg K. The photodegradation of porphyrins in cells that can be used to estimate the lifetime of singlet oxygen. *Photochem Photobiol* 1991;53:549-553.
- [7]. Wilson M, Burns T, Pratten J, Pearson GJ. Bacteria in supragingival plaque samples can be killed by lowpower laser light in the presence of a photosensitizer. *J Appl Bacteriol* 1995;78:569-574.
- [8]. Haas R, Do'rtbudak O, Mensdorff-Pouilly N, Mailath G. Elimination of bacteria on different implant surfaces through photosensitization and soft laser. *Clin Oral Implants Res* 1997;8:249-254.
- [9]. Santamaria L, Prino G. List of the photodynamic substances. *Res Progr Org Biol Med Chem* 1972;3:11-35.
- [10]. Joerg Meister ; Michael Hopp ; Johannes Schäfers ; Jonas Verbeek ; Dominik Kraus ; Matthias Frentzen Indocyanine green (ICG) as a new adjuvant for the antimicrobial photo-dynamic therapy (aPDT) in dentistry Proc. SPIE 8929, Lasers in Dentistry XX, 89290T (February 18, 2014); doi:10.1117/12.2057433.
- [11]. Andersen, R., Loebel, N., Hammond, D. & Wilson, M. (2007) Treatment of periodontal disease by photodisinfection compared to scaling and root planing. *Journal of Clinical Dentistry* 18, 34–38.

- [12]. Braun, A., Dehn, C., Krause, F. & Jepsen, S. (2008) Short-term clinical effects of adjunctive antimicrobial photodynamic therapy in periodontal treatment: a randomized clinical trial. *Journal of Clinical Periodontology* 35, 877–884.
- [13]. Van der Weijden GA, Timmermann MF. A systematic review on the clinical efficacy of subgingival debridement in the treatment of chronic periodontitis. *J Clin Periodontol* 2002;29(Suppl. 3):55-71.
- [14]. Cobb CM. Non-surgical pocket therapy: Mechanical. *Ann Periodontol* 1996;1:443-490.
- [15]. Lindhe J, Westfelt E, Nyman S, Socransky SS, Haffajee AD. Long-term effect of surgical/non-surgical treatment of periodontal disease. *J Clin Periodontol* 1984;11:448-458.
- [16]. Badersten A, Nilve'us R, Egelberg J. Effect of nonsurgical periodontal therapy. I. Moderately advanced periodontitis. *J Clin Periodontol* 1981;8:57-72.
- [17]. Badersten A, Nilve'us R, Egelberg J. Effect of nonsurgical periodontal therapy. II. Severely advanced periodontitis. *J Clin Periodontol* 1984;11:63-67.
- [18]. Ramfjord SP, Caffesse RG, Morrison EC, et al. modalities of periodontal treatment compared over 5 years. *J Clin Periodontol* 1987;14:445-452.
- [19]. Loos B, Kiger R, Egelberg J. An evaluation of basic periodontal therapy using sonic and ultrasonic scalers. *J Clin Periodontol* 1987;14:29-33.