

## Colonoscopic Sigmoid Perforations- A case report

Dr. Abhishek kr Singh<sup>1</sup>, Dr. Sunil Kumar<sup>2</sup>

<sup>1</sup> Registrar, Department of Surgery, Tata Main Hospital, Jamshedpur  
<sup>2</sup> Professor and Head of Department of Surgery, Tata Main Hospital, Jamshedpur

### I. Introduction

Colonoscopic perforation (CP) is widely recognized as one of the most serious complications following lower gastrointestinal endoscopies. Although CP is a rare complication, it is associated with a high rate of morbidity and mortality<sup>[1-5]</sup>. This unpleasant complication could result in operation, stoma formation, intraabdominal sepsis, prolonged hospital stay, and even death.

#### Case report:

A 76 year female, known Diabetic and Hypothyroid, had a h/o alternating bowel habit for last 2 months. She was undergoing screening colonoscopy when it became apparent that the rectosigmoid junction might have become ? perforated. The procedure was abandoned and she was admitted in HDU. Plain X-ray abdomen advised and she was resuscitated. On examination, her lower abdomen had diffuse guarding and tenderness, and vitals were normal. X-ray abdomen revealed retroperitoneal free air and free air under the Rt dome of diaphragm. She underwent Exploratory laparotomy and intraoperative findings shows 4 cm perforation size at lower end of sigmoid colon, diverticulum at lower end of sigmoid colon and small collection in pelvis. Perforations was repaired by PDS 2-0 and she was discharged on 10<sup>th</sup> post op day in good condition.

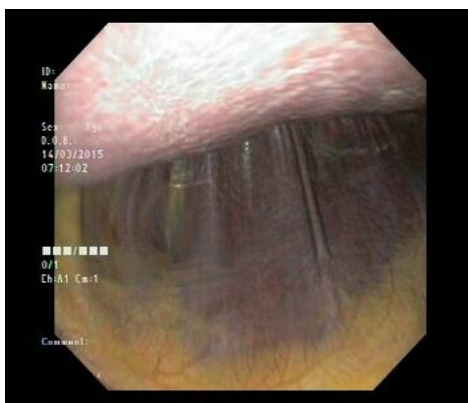


Figure 1. Colonoscopic view showing ischemic area in sigmoid colon

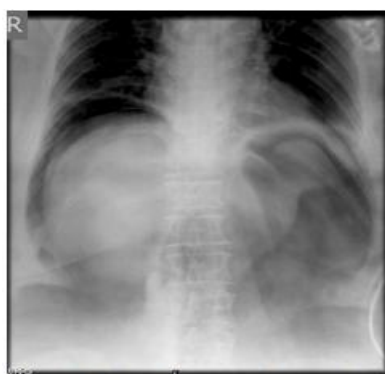
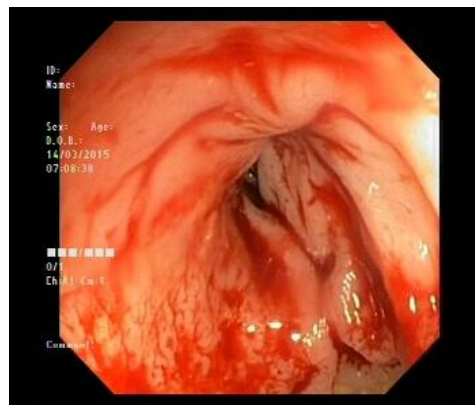


Figure 2. X- Ray Abdomen showing Gas Under RT dome of diaphragm

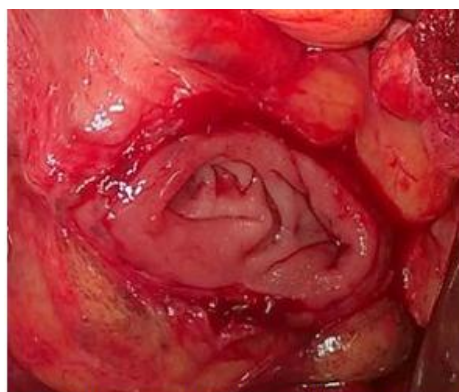

Fig.3. Intra-op perforation site at sigmoid colon

### II. Discussion

The incidence of CP could be as low as 0.016% of all diagnostic colonoscopy procedures<sup>[6]</sup> and may be seen in up to 5% of therapeutic colonoscopies<sup>[7,8]</sup>. The most common site of colonic perforation is the rectosigmoid colon<sup>[1-4,12,14,15]</sup>. Several factors making this bowel segment vulnerable to being injured include a

sharp angulation at either the rectosigmoid junction or the sigmoid descending colon junction, and the great mobility of the sigmoid colon. A forceful insertion of an endoscope while having a sigmoid loop formation is the leading cause of anti-mesenteric bowel perforation due to an overextension of bowel by the shaft of the endoscope. Additionally, the sigmoid colon is commonly involved with diverticular formation<sup>[12,16]</sup>, and the muscular layer of the bowel wall may be thin or fragile due to previous inflammation (diverticulitis). Pelvic adhesions following previous pelvic operation or infection also contribute to a high incidence of sigmoid perforation<sup>[2,7]</sup>. Patients over 75 years of age also have an approximately 4-6 fold rise in the CP rate as opposed to younger patients<sup>[9,13,15,17]</sup>.

Patients with multiple comorbidities are also at greater risk of this perforation<sup>[9,10]</sup>. These include diabetes mellitus, chronic pulmonary disease, congestive heart failure, myocardial infarction, cerebrovascular disease, peripheral vascular disease, renal insufficiency, liver disease and dementia<sup>[19,20]</sup>.

Other risk factors for CP reported in the literature include a history of diverticular disease<sup>[9]</sup> or previous intra-abdominal surgery<sup>[17]</sup> colonic obstruction as an indication for colonoscopy<sup>[15]</sup>, and female gender<sup>[18]</sup>

### **Presentation And Diagnosis**

The most common clinical feature of CP is the visualization of an extra-intestinal structure during the endoscopic examination<sup>[2]</sup>. However, CP patients could present with symptoms and signs of peritonitis (mainly abdominal pain and tenderness) within several hours after the completion of colonoscopy.

When perforation is suspected, a plain x-ray of the abdomen taken to rule out intraperitoneal air. Computed tomography (CT) scanning, and magnetic resonance imaging, are also of great help to identify the free gas<sup>[2]</sup>. Triple-contrast or double-contrast (intravenous and rectal) CT scanning is increasingly used in patients with a clinical suspicion of colonic perforation<sup>[22,23]</sup>

### **Management**

#### **1.Endoscopic closure of the perforation**

#### **2. Operative treatment**

##### **A. Simple closure of the perforation:**

This surgical approach is appropriate in the case of small colonic perforation (< 50% of bowel circumference), without significant fecal contamination and concomitant intestinal pathology requiring bowel resection. Oversewing of the perforation has been carried out in 25%-56% of immediate perforations, and the leakage rate following primary repair was extremely low<sup>[1-4,27]</sup>.

##### **B. Bowel resection with or without intestinal continuity:**

Bowel resection including the perforation site is required when the perforation site is large, or when primary closure of the perforation could compromise the lumen, or when there is concomitant colon pathology requiring bowel resection. In the absence of significant intra-abdominal contamination, bowel resection and anastomosis can be performed with acceptable morbidity. However, in extensive tissue inflammation or faecal peritonitis, bowel resection without anastomosis should be considered.

##### **C. laparoscopic surgery for CP<sup>[24,29]</sup>.**

#### **Prognosis**

Patients with CP could have a remarkably high morbidity and mortality rate depending on their existing medical conditions, nature of the perforation, methods of CP management, experience of the care team and hospital setting. The 30-d morbidity and mortality rates are 21%-53% and 0%-26%, respectively<sup>[1-4,11]</sup>. The average length of hospital stay in CP patients is 1-3 wk<sup>[1,3,5,30]</sup>.

Surgical site infection is the most common complication, while cardiopulmonary complications and multiple organ failure are the leading causes of death<sup>[1,2]</sup>.

### **III. Conclusion**

Colonoscopic perforation is a rare complication following lower gastrointestinal endoscopies; however, it is associated with a high rate of morbidity and mortality. Special precautions should be taken during therapeutic endoscopy and while performing colonoscopic examination in patients with advanced age or those with several comorbidities. Management of patients with CP should be individualized based on patients' clinical grounds and their underlying diseases, nature of the perforation, and concomitant colorectal pathologies.

### **References**

- [1]. Lohsiriwat V, Sujarittanakarn S, Akaraviputh T, Lertakyamanee N, Lohsiriwat D, Kachinthorn U. Colonoscopic perforation: A report from World Gastroenterology Organization endoscopy training center in Thailand. *World J Gastroenterol* 2008; 14: 6722-6725

- [2]. Iqbal CW, Cullinane DC, Schiller HJ, Sawyer MD, Zietlow SP, Farley DR. Surgical management and outcomes of 165 colonoscopic perforations from a single institution. *Arch Surg* 2008; 143: 701-706; discussion 706-707
- [3]. Teoh AY, Poon CM, Lee JF, Leong HT, Ng SS, Sung JJ, Lau JY. Outcomes and predictors of mortality and stoma formation in surgical management of colonoscopic perforations: a multicenter review. *Arch Surg* 2009; 144: 9-13
- [4]. Lüning TH, Keemers-Gels ME, Barendregt WB, Tan AC, Rosman C. Colonoscopic perforations: a review of 30,366 patients. *Surg Endosc* 2007; 21: 994-997
- [5]. Mai CM, Wen CC, Wen SH, Hsu KF, Wu CC, Jao SW, Hsiao CW. Iatrogenic colonic perforation by colonoscopy: a fatal complication for patients with a high anesthetic risk. *Int J Colorectal Dis* 2009; Epub ahead of print
- [6]. Rathgaber SW, Wick TM. Colonoscopy completion and complication rates in a community gastroenterology practice. *Gastrointest Endosc* 2006; 64: 556-562
- [7]. Damore LJ 2nd, Rantis PC, Vernava AM 3rd, Longo WE. Colonoscopic perforations. Etiology, diagnosis, and management. *Dis Colon Rectum* 1996; 39: 1308-1314
- [8]. Repici A, Pellicano R, Strangio G, Danese S, Fagoonee S, Malesci A. Endoscopic mucosal resection for early colorectal neoplasia: pathologic basis, procedures, and outcomes. *Dis Colon Rectum* 2009; 52: 1502-1515
- [9]. Gatto NM, Frucht H, Sundararajan V, Jacobson JS, Grann VR, Neugut AI. Risk of perforation after colonoscopy and sigmoidoscopy: a population-based study. *J Natl Cancer Inst* 2003; 95: 230-236
- [10]. Arora G, Mannalithara A, Singh G, Gerson LB, Triadafilopoulos G. Risk of perforation from a colonoscopy in adults: a large population-based study. *Gastrointest Endosc* 2009; 69: 654-664
- [11]. Cobb WS, Heniford BT, Sigmon LB, Hasan R, Simms C, Kercher KW, Matthews BD. Colonoscopic perforations: incidence, management, and outcomes. *Am Surg* 2004; 70: 750-757; discussion 757-758
- [12]. Korman LY, Overholt BF, Box T, Winker CK. Perforation during colonoscopy in endoscopic ambulatory surgical centers. *Gastrointest Endosc* 2003; 58: 554-557
- [13]. Rabeneck L, Paszat LF, Hilsden RJ, Saskin R, Leddin D, Grunfeld E, Wai E, Goldwasser M, Sutradhar R, Stukel TA. Bleeding and perforation after outpatient colonoscopy and their risk factors in usual clinical practice. *Gastroenterology* 2008; 135: 1899-1906, 1906.e1
- [14]. Lohsiriwat V, Sujarittanakarn S, Akaraviputh T, Lertakyamanee N, Lohsiriwat D, Kachinthorn U. What are the risk factors of colonoscopic perforation? *BMC Gastroenterol* 2009; 9: 71
- [15]. Waye JD. Colonoscopic polypectomy. *Diagn Ther Endosc* 2000; 6: 111-124
- [16]. Levin TR, Zhao W, Conell C, Seeff LC, Manninen DL, Shapiro JA, Schulman J. Complications of colonoscopy in an integrated health care delivery system. *Ann Intern Med* 2006; 145: 880-886
- [17]. Anderson ML, Pasha TM, Leighton JA. Endoscopic perforation of the colon: lessons from a 10-year study. *Am J Gastroenterol* 2000; 95: 3418-3422
- [18]. Charlson ME, Pompei P, Ales KL, MacKenzie CR. A new method of classifying prognostic comorbidity in longitudinal studies: development and validation. *J Chronic Dis* 1987; 40: 373-383
- [19]. Klabunde CN, Potosky AL, Legler JM, Warren JL. Development of a comorbidity index using physician claims data. *J Clin Epidemiol* 2000; 53: 1258-1267
- [20]. Saunders BP, Fukumoto M, Halligan S, Jobling C, Moussa ME, Bartram CI, Williams CB. Why is colonoscopy more difficult in women? *Gastrointest Endosc* 1996; 43: 124-126
- [21]. Shanmuganathan K, Mirvis SE, Chiu WC, Killeen KL, Scalea TM. Triple-contrast helical CT in penetrating torso trauma: a prospective study to determine peritoneal violation and the need for laparotomy. *AJR Am J Roentgenol* 2001; 177: 1247-1256
- [22]. Holmes JF, Offerman SR, Chang CH, Randel BE, Hahn DD, Frankovsky MJ, Wisner DH. Performance of helical computed tomography without oral contrast for the detection of gastrointestinal injuries. *Ann Emerg Med* 2004; 43: 120-128
- [23]. Hansen AJ, Tessier DJ, Anderson ML, Schlinkert RT. Laparoscopic repair of colonoscopic perforations: indications and guidelines. *J Gastrointest Surg* 2007; 11: 655-659
- [24]. Tran DQ, Rosen L, Kim R, Riether RD, Stasik JJ, Khubchandani IT. Actual colonoscopy: what are the risks of perforation? *Am Surg* 2001; 67: 845-847; discussion 847-848
- [25]. Bleier JI, Moon V, Feingold D, Whelan RL, Arnell T, Sonoda T, Milsom JW, Lee SW. Initial repair of iatrogenic colon perforation using laparoscopic methods. *Surg Endosc* 2008; 22: 646-649
- [26]. Tulchinsky H, Madhala-Givon O, Wasserberg N, Lelcuk S, Niv Y. Incidence and management of colonoscopic perforations: 8 years' experience. *World J Gastroenterol* 2006; 12: 4211-4213.