

Rare Giant Mesenteric Desmoid: A Case Report

*KirandeepKaur, RamandeepKaur, Harneet Singh Ghotra

[MS Surgery, Shah Hospital, Kaithal]

[MD Gynae&Obs]

[MS Surgery, Mch Neurosurgery]

Abstract: Intra-abdominal desmoids are rare neoplasms. The aggressive nature of these tumours and the potential for major morbidity secondary to resection can present a difficult surgical dilemma. We report an unusual giant mesenteric desmoid fibromatosis which involved both ileum and transverse colon, which is first of its kind case. A 58 year old female presented with vague fullness in lower abdomen and ill defined mass on ultrasound abdomen. Diagnostic laparoscopy was done. A giant desmoid was localized in mesentery of ileum and abutting anterior wall of transverse colon. Complete resection of tumour was accomplished along with involved ileum and part of transverse colon.

Key Words: Desmoid fibromatosis, ileum and transverse colon, laparoscopy, complete resection.

I. Introduction

Desmoid tumours have an estimated incidence of 3.7 new cases per million people per year[1]. Desmoids may occur in the abdominal wall, the mesentery, or the retroperitoneum. Extra-abdominal desmoids may involve the shoulder, thigh, buttock, or the trunk[1]. Desmoid fibromatosis is defined by World Health Organization as 'clonal fibroblastic proliferations' that arise in the deep soft tissues and are characterized by infiltrative growth and a tendency towards local recurrence but an inability to metastasize[2]. This entity was first described in the 1800's by MacFarlane[3]. Muller later used the term desmoids, derived from the greek word 'desmos' meaning tendon like to refer to this lesion[4]. Here we present a case of giant desmoid tumour involving both ileum and transverse colon which was completely resected.

II. Case Report

A 58 years old female presented with the only complaint of vague fullness lower abdomen for 6 months. She was post menopausal for 8 years. No chronic ailment, no relevant family history, no surgery in past. Clinically, well-defined 8x7cm palpable mass with limited side to side mobility, arising from pelvis, with well-defined upper border and palpable lateral margins, lower limit was not reached & it was intra-peritoneal. CECT abdomen showed lobulated homogenous hypo-attenuating mass lesion in lower abdomen and pelvis involving mesentery in midline, some of the pelvic ileal loops and colonic loops were splayed around the mass? Desmoid? Carcinoid (Fig 1).

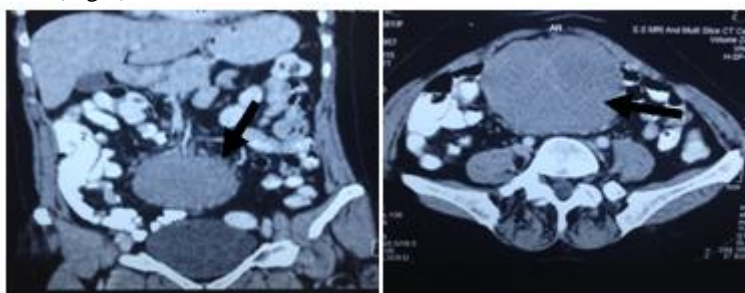


Figure 1(CECT Abdomen) showing giant mass in the mesentery.

On FNAC hemorrhagic aspirate had suspicious looking cells. Tumor markers CA125 and CEA and other lab parameters (CBC, RBS, RFTs, LFTs, CXR) were normal. Diagnostic laparoscopy showed giant cystic mass in mesentery of ileum, 90cm from ileo-caecal junction. It was attached to 45cm of ileum and the anterior wall of mid transverse colon, exactly opposite to the ileal attachment. Mass was large and difficult to manipulate laparoscopically, so midline laparotomy was performed. Anterior wall of transverse colon below the attachment of omentum (about 5cm) which was the involved part of colon was resected. Total resection of the mass along with involved 45cm of ileum (which was splayed around the mass and was densely adherent to it) was done. (Fig 2,3,4). End to end anastomosis of ileum, and primary repair of transverse colon rent was done.

Gross examination revealed encapsulated grey white mass weighing 650gms, size 13×12 ×8cm with 45 cm of ileum attached to it, cut surface was grey-white, trabeculated, glistening with focal haemorrhagic areas.

Histopathological examination: Intra- abdominal mesenteric deep desmoid type fibromatosis measuring 13 cm in greatest dimensions, no evidence of malignancy seen, ileal wall and cut ends were unremarkable(Fig 5)

Patient postoperatively was uneventful, nasogastric tube was removed on day 5 and patient started on liquid and semisolid diet. Patient was referred to oncologist for further opinion and management.

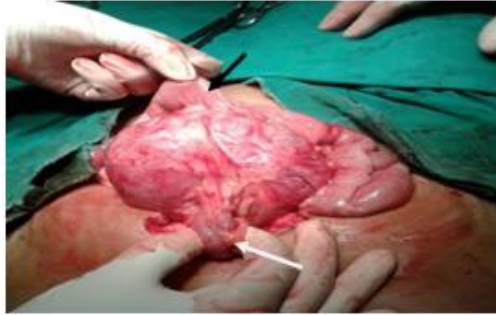

Figure 2: Black arrow shows ileum and white arrow shows transverse colon around the mass.

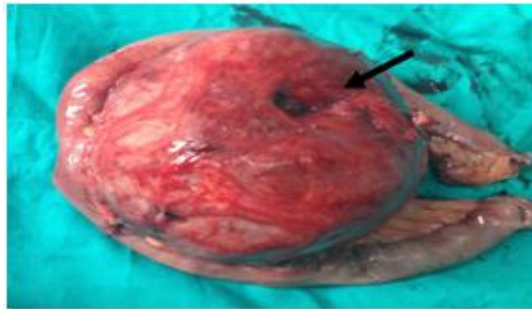


Figure 3: Specimen showing ileum (black arrow) splayed around desmoid fibromatosis and a depression (white arrow) where transverse colon was entering it.

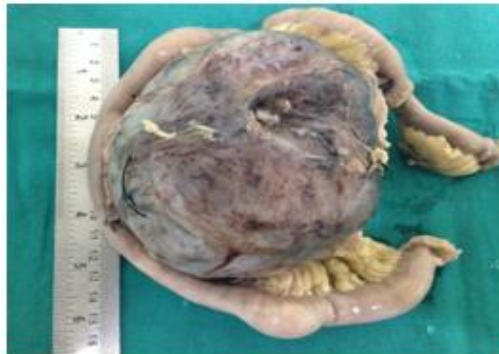

Figure4: Showing measurements of the cyst

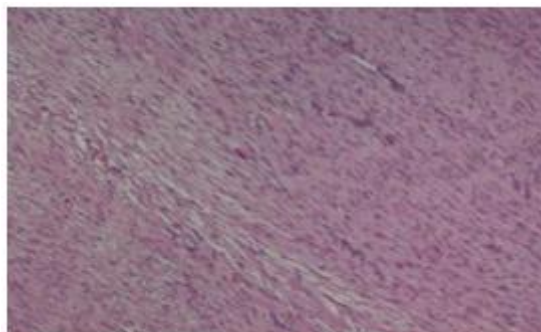


Figure5: Histopathological examination

III. Discussion

Desmoid tumors accounts for 0.03% of all neoplasms [5]. The natural history of desmoids varies from patient to patient: some desmoids grow unceasingly; others grow, stop growing, and then start growing again; still others grow and then regress without intervention. They can occur throughout the body. Desmoid tumor arises from myofibroblast, lacks a true capsule, and usually infiltrates into adjacent muscle bundles. Despite the benign histological character, their biological behavior is more 'malignant', since the infiltrative pattern of growth, they are sometimes being classified as low-grade fibrosarcoma, can ultimately lead to life-threatening visceral involvement and even cause death [6]. At a cellular level, they lack the nuclear and cytoplasmic features of malignancy and have no metastatic potential [7-9].

Wide local resection, advocated nearly 100-years ago, remains the treatment of choice for most patients with desmoid tumors. Nevertheless, there is little data and agreement with regard to what constitutes an adequate wide margin. Typically, these tumors lack pseudoencapsulation and have non-palpable extensions along muscle bundles and fascial planes, precluding reliable intraoperative clinical estimation of their extent. Despite this, attempts have been made in a number of reports to define the optimal operative procedure by evaluating outcome according to the type of resection, designated variously as simple excision, local excision, wide excision, adequate resection, inadequate resection, radical local excision, and so on -without evaluating the actual pathologic margin. Unfortunately, the achievement of histopathological negative margins does not assure eradication of this disease. In one series the recurrence rate after margin-negative resection was 27%. Another recent study found a 22% recurrence rate after margin-negative resection [7]. In another recent study of patients with primary tumors, it was found that the status of the resection margin had no influence on local recurrence, and patients had an overall local control rate of 75% at 5 years.

Overall, the local control of these tumors with the use of radiation therapy is similar to that obtained by surgical management alone. Nevertheless, radiation therapy may offer some benefit in providing local control in patients with gross residual disease. The most consistent results for complete control have been seen in patients receiving doses >6000 cGy; complete regression of tumor may require up to 2 years [12-15].

Response to multiple systemic agents including antiestrogens, NSAIDs, vitamin K, warfarin, vitamin C and more recently, low-dose combination methotrexate and vinblastine have also been reported. A successful therapy of a desmoid tumour resistant to traditional chemotherapeutic regimens was reported with Imatinib in one study [16-17].

Desmoid tumours should be differentiated from intra-abdominal GIST, metastasis, other mesenteric masses.

IV. Conclusion

Desmoid fibromatosis although rare tumors should always be considered in differential diagnosis of pelvic lesions and possibility of involvement of both small and large intestine should be kept in mind while operating. Bowel resection may be necessary in cases where cysts are close to bowel structures or involve blood vessels that supply the bowel and to achieve tumor free margins.

V. Consent

Written informed consent was obtained from patient in her native language for publication of this case report and accompanying images. Copy of the written consent is available for review.

References

- [1]. Einstein DM, Taglaibue JR, Desai RK, Abdominal desmoids:CT findings in 25 patients. *AJR*1991;157:275-279].
- [2]. Fletcher CDM, Unni KK, Mertens F. Pathology and Genetics of Tumours of Soft Tissue and bone. World Health Organization Classification of Tumours. Lyon, France: IARC Press; 2002:83-84.
- [3]. Hosalkar HS, Torbert JT, Fox EJ et al. Musculoskeletal desmoids tumors *J Am Acad Orthop Surg*. 2008 Apr; 16(4):188-98.
- [4]. Pakos EE, Tsekeris PG, Goussia AC. Desmoid tumours of extremities and trunk: a review of literature. *Int Orthop*. 2005 Aug;29(4):210-3.
- [5]. Stollwerck P.L., Namdar T, Bartscher T, Stang, F.H. et al. A rare desmoid tumor of the shoulder -excision, implantation of brachytherapy applicators and wound closure by pedicle musculolateralissimus dorsi flap. *P. GMS German Medical Science*. 2011; 9.
- [6]. Pathology. Jain P, Shah P, Bhansali M. Unusual presentation of an uncommon abdominal. *Annals of Royal College of Surgeons of England*. 2010;92(7):W19-W21.
- [7]. Spear MA, Jennings LC, Mankin HJ, Spiro IJ, Springfield DS, Gebhardt MC, et al. Individualizing management of aggressive fibromatosis. *Int J Radiat Oncol Biol Phys* 1998;40:637-45.
- [8]. Alman BA, Pajerski ME, Diaz-Cano S, Corboy K, Wolfe HJ. Aggressive fibromatosis (desmoid tumor) is a monoclonal disorder. *Diagn Mol Pathol* 1997; 6: 98-101.
- [9]. Wara WM, Phillips TL, Hill DR, et al. Desmoid tumors—treatment and prognosis. *Radiology* 1977; 124: 225-226. [PubMed]
- [10]. Li M, Cordon-Cardo C, Gerald WL, Rosai J. Desmoid fibromatosis is a clonal process. *Hum Pathol* 1996; 27: 939-943
- [11]. Merchant NP, Lewis JJ, Leung DH, Woodruff JM, Brennan MF. Extremity and trunk desmoid tumors: a multifactorial analysis of outcome. *Cancer* (in press). [PubMed]
- [12]. Leibel SA, Wara WM, Hill DR, et al. Desmoid tumors: local control and patterns of relapse following radiation therapy. *Int J Radiat Oncol Biol Phys* 1983; 9: 1167-1171. [PubMed]

- [13]. Sherman NE, Romsdahl M, Evans H, Zagars G, Oswald MJ. Desmoid tumors: a 20-year radiotherapy experience. *Int J RadiatOncolBiolPhys* 1990; 19: 37–40. [PubMed]
- [14]. Reitamo JJ, Scheinin TM, Hayry P. The desmoid syndrome. New aspects in the cause, pathogenesis and treatment of the desmoid tumor. *Am J Surg* 1986; 151: 230–237. [PubMed]
- [15]. Kiel KD, Suit HD. Radiation therapy in the treatment of aggressive fibromatoses (desmoid tumors). *Cancer* 1984; 54: 2051–2055.
- [16]. Wcislo G, Szarlej-Wcislo K, Szczylik C. Control of aggressive fibromatosis by treatment with imatinibmesylate. A case report and review of the literature. *J Cancer Res ClinOncol*. 2007;133:533–8.
- [17]. Zokalj I, Culinovic-Caic R, Magas Z, Pavcec Z, Saghir H, Igrc J, et al. Gastric gastrointestinal stromal tumour. *RadiolOncol*. 2008;42:187–95.