

## Uncommon Findings in Appendicectomy Specimens

Swayam Jothi S<sup>1</sup>, Rajeswara Rao N<sup>2</sup>, Sujatha N<sup>3</sup>, CHNV Bharath<sup>4</sup>,  
Anuradha S<sup>5</sup>.

<sup>1,2,3</sup> Dept of Anatomy, <sup>5</sup> Dept of Pathology, Shri Sathya Sai Medical College & Research Institute,  
Kancheepuram District

<sup>4</sup> Dept of Anatomy, Shanthiram Medical College, Kurnool District

---

**Abstract:** The lifetime risk for appendicitis is 7% commonly occurring in adolescents and young adults (Turner 2010). The rate of appendicitis varies among countries. Acute appendicitis is the most common surgical emergency and accounts for about 40% of all surgical emergencies in the western world (Edino et al 2004). In developing countries, the incidence is increasing in most urban centers; probably due to adoption of Western diet (Oguntola et al 2010).

A total of 507 slides from Appendicectomy cases collected from the Dept. of Pathology were studied and uncommon findings observed were enumerated. i) Total obliteration of lumen 2.6%, ii) Presence of Hyperplastic epithelium 3.3%, iii) Accumulation of fat in the submucosa varying from grade I to IV, iv) Worm infestation 3.6%, v) Attenuation of the mucosa over the area of lymphoid hyperplasia, vi) Hyalinization & hypertrophy of the muscle coat, vii) Appendices epiploicae at microscopic level in so many cases and at macroscopic level in a few, viii) A case of Tuberculosis 0.2%

The unusual findings reported in the study will throw light on i) Causative factors for appendicitis. ii) For better understanding of sequelae. iii) The importance of histopathological study. iv) For further management of cases.

**Key words:** Hyperplastic epithelium, Appendices epiploicae, Submucosal fat, Obliteration of the lumen.

---

### I. Introduction:

Appendicectomy is one of the common surgeries in the abdomen. We still don't know the significance and function of the rich lymphoid tissue present at the beginning of the large intestine. The uncommon findings observed were reported here. Obstruction of the lumen is the main cause for appendicitis. Obstruction is caused by lymphoid hyperplasia, faecolith & worm infestations.

### II. Material & Methods:

507 slides of Human appendicectomy specimens collected from the Dept. of Pathology, SSSMC & RI were utilized for this study. Under H&E stain detailed study was carried out under low & high power magnification.

### III. Observations:

The Uncommon findings that were seen are as follows:

- i. Total obliteration of lumen was observed in 13 cases (2.6%) (Fig: 1).
- ii. Hyperplastic epithelium was observed in 17 cases (3.3%) (Fig: 2 a & b).
- iii. Different grades of fat deposition was seen in the Submucosa-Grade-I in 110 cases Grade-II in 105 cases, Grade III in 75 cases and Grade IV in 22 cases (Fig: 3 a,b,c,d)
- iv. Worm infestation was seen in 18 cases (3.6%) of which one rare case showed the presence of Balantidium coli infestation (Fig: 4)
- v. Attenuation of the Mucosa was associated with Lymphoid hyperplasia (Fig: 5).
- vi. Muscular hypertrophy was remarkable in 20 cases (Fig: 6 a & b) and was associated with hyalinization in 10 cases (Fig: 7 a & b).
- vii. One case (0.2%) of Tuberculous granuloma of the appendix was seen (Fig: 8 a & b).
- viii. Presence of Appendices epiploicae was noted in 156 cases (30.8%) of which 8 were rudimentary and some presented 2 to 3 Appendices epiploicae at microscopic level (Fig: 9 a & b) and 15 specimens (3%) presented at macroscopic level (Fig: 10 a & b)
- ix. Infiltration of lymphoid tissue into adjacent layers was seen extending medially into the mucosa and extending outwards into the muscular coat and sometimes into the serosal coat (Fig: 11 a & b).

#### **IV. Discussion:**

Neoplasms of the appendix are very common and usually diagnosed at operation or autopsy. In his classical study of 71000 appendicectomy specimens, Collins found 958 malignant and 3271 benign tumors with an overall incidence of 4.6% for benign tumors and 1.35% for the malignant tumors (Collins et al 1963). Benign tumors of the appendix consist of leiomyomas, neuromas and lipomas. Malignant tumors of the appendix include carcinoids, mucocoeles and adenocarcinomas. In present series 17 cases (3.3%) showed hyperplastic epithelium, may be a premalignant condition.

Carcinoids are the commonest tumor of the appendix. In the series by Collins, carcinoid made up 51% of the malignant tumors of the appendix (Collins et al 1963). The reported incidence of appendiceal carcinoids in several studies ranges from 0.02% to 1.5% of surgically removed appendices (Moertel 1987). In the Collin's study, carcinoids were found in 0.7% of all appendicectomy specimens (Collins et al 1963). Not even a single case of carcinoid was observed in the present study.

Parasitic infection is thought to be one of the causes of luminal obstruction of appendix leading to appendicitis. Several studies have found luminal parasites in the appendix associated with or without appendicitis in the range of 0.3 to 3.15%. (Marudanayagam et al 2006); (Aydin et al 2007); (Duzgun et al 2004). In the present study parasitic infestation formed 3.6%. The most common infestation was due to *Enterobius vermicularis*. Next common infestation was due to *Ancylostoma duodenale* & *Ascaris lumbricoides*. One case of *Balantidium coli* was observed as in the case of the study done by Arife Polat et al (2004). No report in English Medical literature regarding *Balantidium coli* in the appendicectomy specimens and hence it is difficult to make any comment on its causative role in the pathogenesis of appendicitis Arife Polat Duzgun et al (2004).

Tuberculous appendicitis (TBA) is a rare condition and commonly occurs in the young. Results of all pre-operative investigations are non-specific and the diagnosis is made only after histopathology (Zhang et al 1996); (Mittal et al 1975); (Singh et al 1987); (Agarwal et al 2004). In the present study Tuberculous granuloma was observed in one case only by histopathological study (0.2%).

Collins in 1963, Shrestha et al (2012) and Arife Polat Duzgun (2004) has reported unusual findings. The presence of appendices epiploicae in appendix has not been reported, except in one article which reports the torsion of an appendix epiploicae present in vermiform appendix is a rare cause of acute abdomen (Muhammed Babar Aslam 2009). In the present study presence of microscopic appendices epiploicae was quiet common 156 specimens (30.8%) and it was observed macroscopically 15 specimens (3%). In chronic appendicitis muscular hypertrophy associated with hyalinization, fibrosis, dilatation of lumen takes place as compensatory mechanism beyond which it ends up in an acute attack. During this process the serosal covering also gets stretched as a result of oedema and when the attack subsides the redundant serosa forms loose folds into which fat gets deposited to form appendices epiploicae which are seen at microscopic level and when these become larger seen macroscopically. The Outpocketing may be the site of inflammation, thrombosis and infarction causing an acute abdomen (Legome et al 2002) requiring investigation (Barbier et al 1998) & surgery (Diaco et al 1993).

#### **V. Conclusion:**

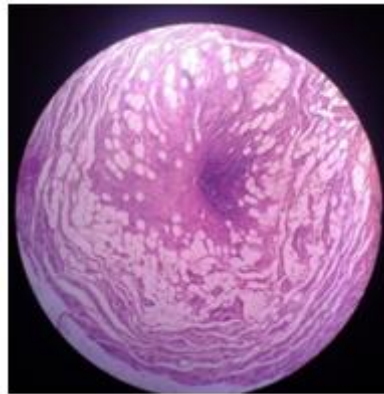
Meticulous exploration and evaluation is required in all cases of appendicectomy for the sake of further research into the etiology and its post operative management. Of course some conditions can be diagnosed only at the time of histopathological reporting.

The unusual findings reported in the study will throw light on i) Causative factors for appendicitis. ii) For better understanding of sequelae. iii) The importance of histopathological study. iv) For further management of cases.

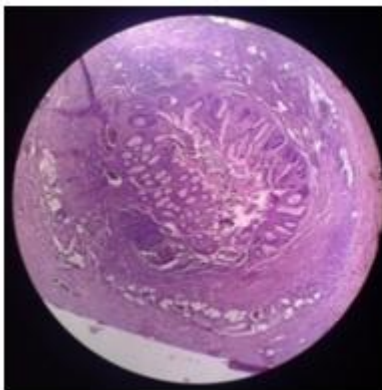
#### **References:**

- [1]. Agarwal P, Sharma D, Agarwal A, Agarwal V, Tandon A, Baghel KD, et al. Tuberculosis appendicitis in India. *Trop Doct* 2004;34:36-8.
- [2]. Aydin O. incidental parasitic infestations in surgically removed appendices: a retrospective analysis. *Diagn Pathol* 2007;2:16.
- [3]. Barbier C, Denny P, Pradoura JM, Bui P, Rieger A, Bazin C, et al. Radiologic aspects of infarction of the appendix epiploica. *J Radiol* 1998; 79:1479-85.
- [4]. Collins DC. 71000 human appendix specimens; a final report summarizing 40 years study. *Am J Protocol Gastroenterol Colon Rectal Surg* 1963; 14:365-81.
- [5]. Diaco JF, Diaco DS, Brannan AN. Endoscopic removal of an infarcted appendix epiploica. *J Laparoendosc Surg* 1993; 3:149-51.
- [6]. Duzgun AP, Moran M, Uzun S et al Unusual findings in appendectomy specimens: Evaluation of 2458 cases and review of the literature. *Indian J Surg* 2004;66:221-6.
- [7]. Edino ST, Mohammed AZ, Ochicha O, Anumah M. Appendicitis in Kano, Nigeria: A 5 year review of pattern, morbidity and mortality. *Ann Afr Med* 2004;3:38-41.
- [8]. Legome EL, Belton AL, Murray RE, Rao PM, Novelline RA. Epiploic appendagitis: the emergency department presentation. *J Emerg Med* 2002; 22:9-13.
- [9]. Marudanayagam R, Williams GT, Rees BI. Review of the pathological results of 2660 appendicectomy specimens. *J Gastroenterol* 2006; 41:745-9.
- [10]. Mittal VK, Khanna Sk, Gupta Nm, Aikat M. isolated tuberculosis of appendix. *Am Surg* 1975;41: 172-4.

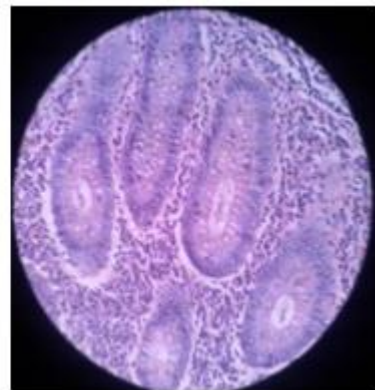
- [11]. Muhammad Babar Aslam,1 Noori Hasan. Torsion of an appendix epiploicae present at the vermiform appendix: a rare cause of acute abdomen. Turkish Journal of Trauma & Emergency Surgery,2009;15(5):509-510.
- [12]. Moertel CI, Weiland LH, Telander RL. Carcinoid tumor of the appendix: Treatment and prognosis. N Eng J Med 1987;317:1699-701.
- [13]. Oguntola AS , Adeoti ML , Oyemolade TA. Appendicitis: Trends in incidence, Age, Sex and Seasonal variations in South - Western Nigeria. Ann Afr Med 2010;9:213-7.
- [14]. Singh MK, Arunabh, Kappor VK. Tuberculosis of the appendix – a report of 17 cases and a suggested aetiopathological classification. Postgrad Med J 1987;63:855-7.Turner JR. The Gastrointestinal tract, In: Kumar, Abbas (eds). Robbins and Cotran Pathologic basis of disease. 8<sup>th</sup> edn. Saunders:Philadelphia; 2010. pp870-1.
- [15]. Turner JR. The Gastrointestinal tract, In: Kumar, Abbas, Fausto (eds). Robins and Cotran Pathologic basis of disease. 8<sup>th</sup> edn. Saunders: Philadelphia; 2010. pp870-1.
- [16]. Zhang Z, Gu J, Zhu Z. a clinicopathological observation of 15 cases of tuberculosis of the appendix. Zhonghua Jie He He Hu Xi Za Zhi 1996; 19:236-8



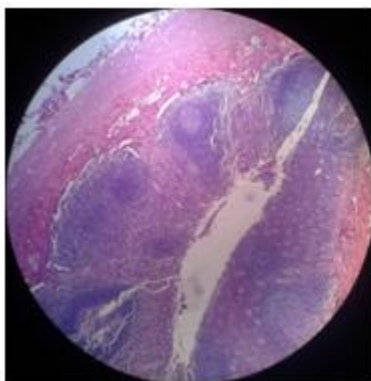
**Fig 1: Shows total obliteration of lumen (H&E 10X)**



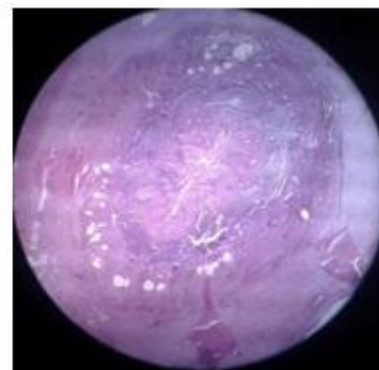
**Fig 2a: Hyperplastic epithelium (H&E 10X)**



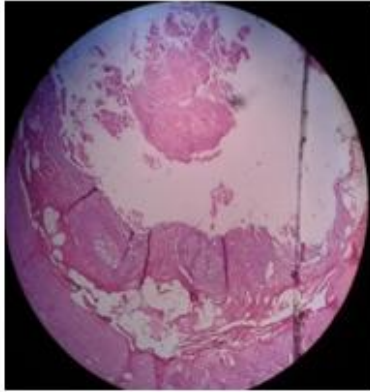
**Fig 2b: Hyperplastic epithelium (H&E 40X)**



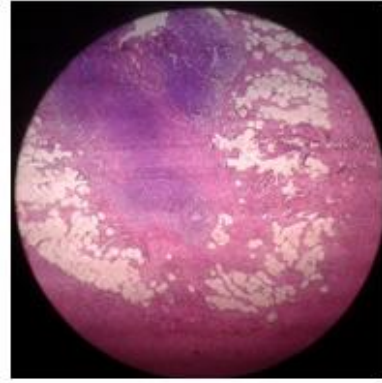
**Fig 3a: Grade-I fat in Submucosa(H&E 10X)**



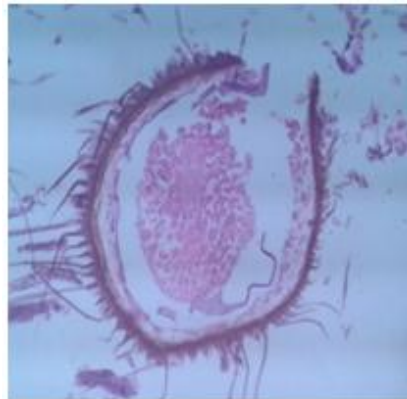
**Fig 3b: Grade-II fat in Submucosa(H&E 10X)**



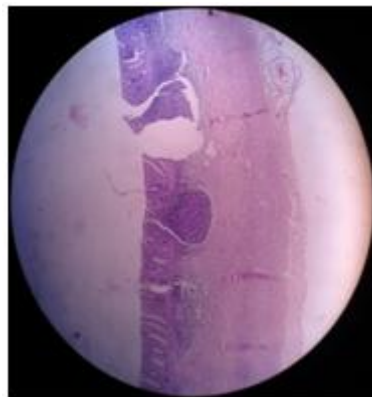
**Fig 3c: Grade-III fat in Submucosa(H&E 10X)**



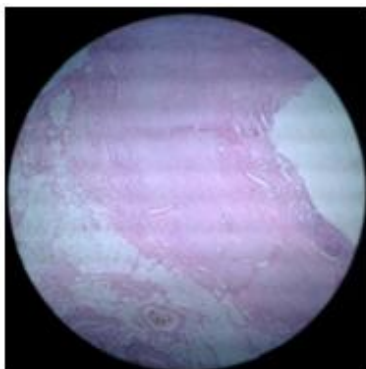
**Fig 3d: Grade-I fat in Submucosa(H&E 10X)**



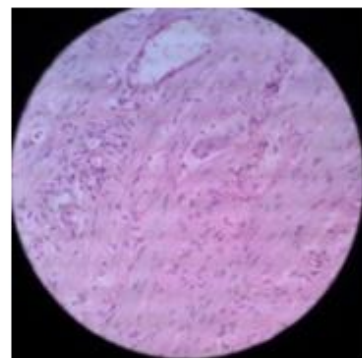
**Fig: 4 shows the presence of Balantidium coli in the lumen of appendix (H&E)**



**Fig: 5 Attenuation of the Mucosa was associated with lymphoid hyperplasia (H&E 10X)**

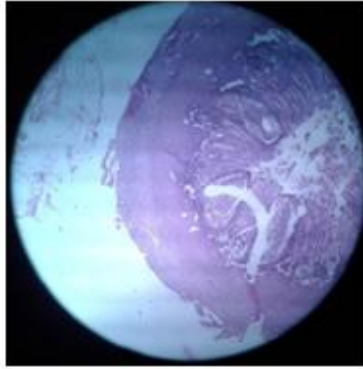


**Fig 6a: H&E 10X**

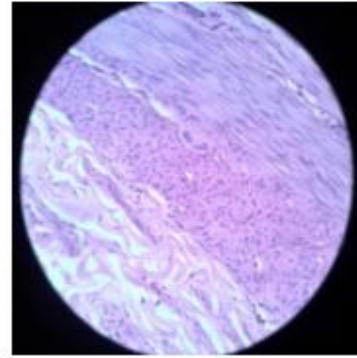


**Fig 6a: H&E 40X**

**Fig: 6a & 6b Muscular hypertrophy associated with hyalinization**

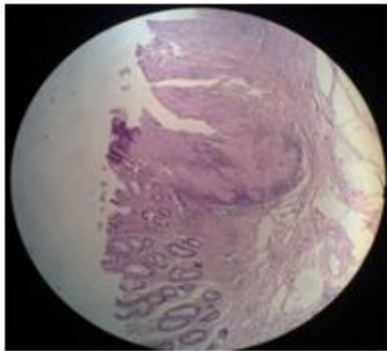


**Fig 7a: H&E 10X**

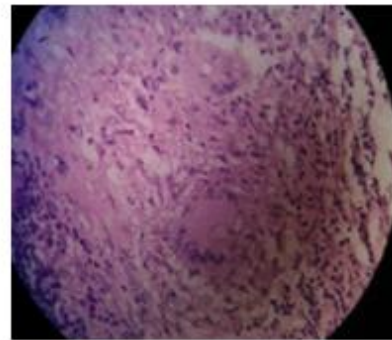


**Fig 7b: H&E 40X**

**Fig: 7a & 7b Muscular hypertrophy associated with hyalinization**

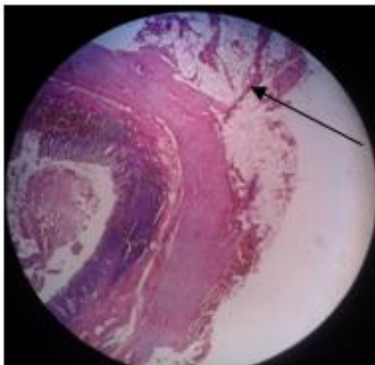


**Fig 8a: H&E 10X**

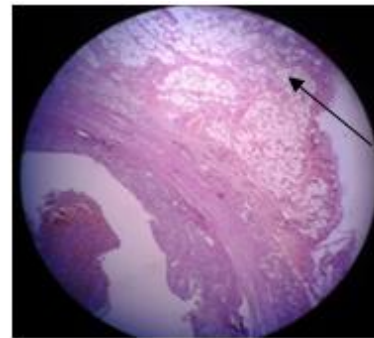


**Fig 8a: H&E 40X**

**Fig: 8a & 8b Tuberculous granuloma of the appendix**

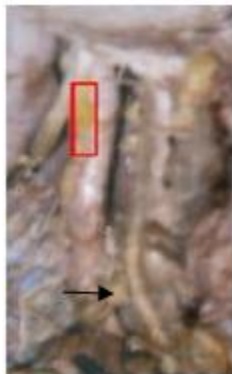

**Fig 9a: H&E 10X**

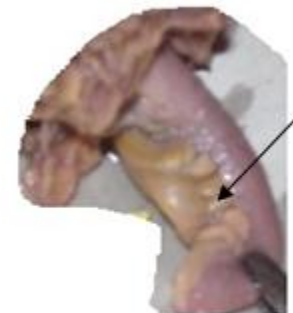

**Fig 9a: H&E 40X**

**Fig: 9a & 9b Appendices epiploicae seen under microscope**



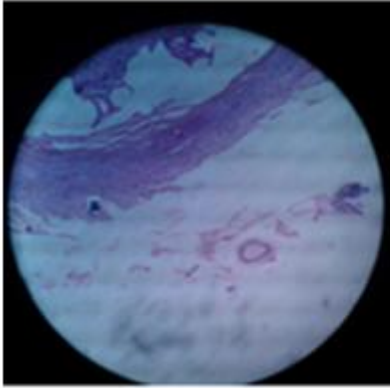
**Fig: 10a**



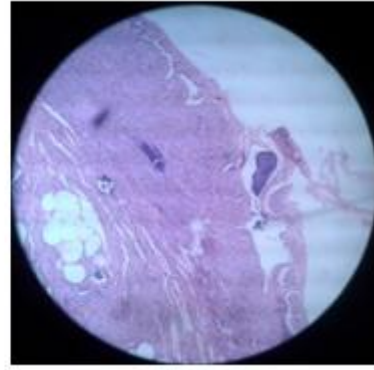
**Fig: 10a**

**Fig: 10a & 10b Appendices epiploicae seen macroscopically**





**Fig 11 a H&E 10X**



**Fig 11 b H&E 40X**

**Fig 11 a & b Lymphoid infiltration into the muscular and serosal coat**