

## Endodontic Management of Mandibular First Molar with Radix Entomolaris And Second Premolar With Three Root Canals: A Case Report

Dr. M.B. Wavdhane<sup>1</sup>, Dr. Pradnya V. Bansode<sup>2</sup>, Dr. Seema D. Pathak<sup>3</sup>,  
Dr. Kapil D. Wahane<sup>4</sup>.

<sup>1,4</sup> Assistant professor, Department of conservative dentistry and endodontics, Govt. dental college and hospital Aurangabad (M.S), India.)

<sup>2</sup> Professor and Head, Department of conservative dentistry and endodontics, Govt. dental college and hospital Aurangabad (M.S), India.)

<sup>3</sup> Associate Professor, Department of conservative dentistry and endodontics, Govt. dental college and hospital Aurangabad (M.S), India.)

**Abstract:** Wide diversity in morphology of multirouted teeth presents a challenge to clinicians in achieving successful endodontic therapy. Locating all the canals, shaping and cleaning and obtaining a tight hermetic seal of all the root canals located within the tooth being treated defines the success of the endodontic therapy undertaken. The endodontist needs to have a thorough knowledge of the complex canal anatomy in order to expect and anticipated these variations. This case report discusses endodontic management of a mandibular first molar with Radix Entomolaris and adjacent mandibular premolar with three root canals.

**Keywords:** Radix Entomolaris, Three canal mandibular second premolar, Endodontic management.

### I. Introduction

Barret has rightly stated “of all the phase of anatomic study in human system, out of the most complex is that of pulp cavity morphology”. Clinician should pose comprehensive knowledge of root canal morphology and associated variation. Root canals are often left untreated because the operator fails to locate when they are present especially in teeth exhibiting anatomic irregularities or accessory or aberrant root canals.(1,2)

The additional third root (i.e. the supernumerary root) in permanent mandibular first molar variants that have three roots is typically distributed lingually. This was first described by Carabelli in 1844 and was termed Radix Entomolaris by Bolk in 1915. The exact cause of Radix Entomolaris (RE) is still not known. Some authors say that it may be due to disturbances during odontogenesis or may be due to atavistic gene. Incidence of RE varies from 5-30% and also among different population. A RE can be found on the first, second and third mandibular molar, occurring least frequently on the second molar (3). According to the classification of De Moor et al (4), based on the curvature of separate RE variants in buccolingual orientation, three types can be identified.

Type-I refers to a straight root/ root canal.

Type-II refers to an initially curved entrance which continues as a straight roots /canal.

Type III refers to an initial curve in coronal third of the root canal and second curve beginning in the middle and continuing to the apical third.

Normal root and root canal anatomy of mandibular premolars are well documented in numerous text books, but there is a great deal of variation in the reporting of the incidence of anomalies(5). Slowey(6) indicated that due to the variations in the canal anatomy, mandibular premolars are most difficult teeth to treat endodontically, they have a high flare up and failure rate, occurrence of three canals with three separate apices ( Type V, Vertucci) in mandibular premolar is vary rare. In a classic anatomical study Zillich and Dowson (7,8) showed the occurrence of three canals in mandibular second premolars to be 0.04% while vertucci(8) reported as zero %.

The present case report addresses the endodontic management of rare case of radix entomolaris with mandibular right first molar and mandibular right second premolars with separate root canals.

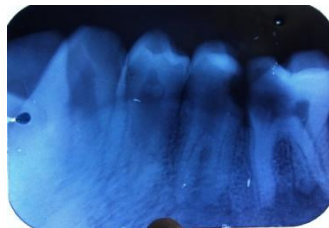
### II. Case Report

A 19 yr oid male reported to the department of conservative dentistry and endodontics, with the chief complaint of pain in the lower right back tooth region . On clinical examination the tooth #45 and # 46 had deep carious lesions showing pulpal involvement and was tender on percussion . . Electric pulp test and heat test with gutta percha stick g ave negative response. There was no evidence of swelling or sinus tract.Radiograph showed disto occlusal radiolucency with pulpal involvement and periodontal space widening relative to mesial and

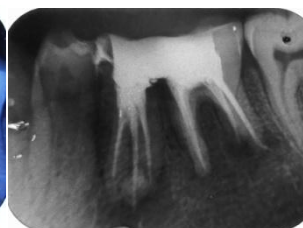distal roots and additional distolingual root (fig1) with #46 .Radiograph also showed deep occlusal cavity with pulp involvement, slight widening of periodontal ligament space ,periapical radiolucency and presence of two roots with a shadow of a third root in between the first two and based on clinical and radiographic evidences, a diagnosis of irreversible pulpitis was made.Diagnosis of extra canals with #45 and #46 was also confirmed by CBCT( Fig.3).

Access was gained to the pulp chamber after administration of local analgesia (2% lidocaine with 1:80,000 adrenaline) under rubber dam isolation using Endo access bur kit (Dentsply,Mallefer,Switzerland ) .Three canals were located (2 mesial and 1 distal ) . The dentine map extended toward s the distolingual direction and tracing it the access was modified from a triangular to a trapezoidal shape successfully locating the extra distolingual (RE) canal .The canal patency was .checked with # 10 k-file .The working length was estimated using a digital apex locator . Canals were cleaned and shaped sequentially with ProTaper files irrigated using 4% sodium hypochlorite and a final rinse of saline . canal were then dried with paper points (Dentsply, Maillefer,USA) ,cotton was placed in pulp chamber and cavite(3M ESPE,St Paul, MN ,USA) was used to close access cavity . Patient called after 4 days for second oppointment.

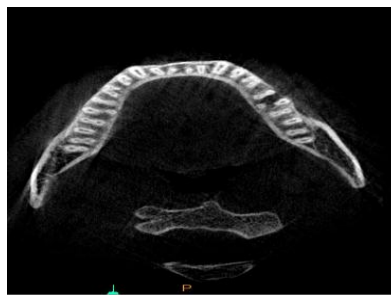
At second appointment , the access to the root canal with #45 was prepared under local anesthesia (2% lidocaine with 1:80,000 adrenalin) under rubber dam isolation using Endo access bur kit (Dentsply,Maillefer, Switzerland) .Three canals were located :bucally ,lingually , and third canal in the middle . the canal patency was checked with #10 k- file . the working length was estimated using a apex locator . canals were clean and shaped sequentially with ProTaper files (Dentsply, Maillefer,USA) , irrigated using 6% sodium hypochloride and final rinse of saline . Canals were dried with paper points (Dentsply,Maillefer,USA) , cotton was placed in the pulp chamber and cavit(3M ESPE,St Paul, MN ,USA) was used to close the access cavity.Dressing changed with #46. Patient was asymptomatic. Patient called after one week for obturation. At next appointment canals of tooth #45 and #46 were obturated with F2 ProTapar gutta parcha cones (Dentsply, Maillefer,USA),using AH plus sealer (Dentsply, Maillefer,USA). Post-operative radiograph was taken to confirm the quality of the obturation. Access opening was sealed with amalgam restoration.Patient was referred to the dept. of prosthodontics for crown.



**Fig.1**



**Fig.2**



**Fig.3**

### **III. Discussion**

The root canals are frequently left untreated because clinicians often fail to identify their presence, particularly in teeth that have anatomical variations or additional root canals, before root canal treatment is performed. Therefore clinician should be aware of the configuration of pulp space of the tooth to be treated (6). Accurate diagnosis of supernumerary roots like RE can contribute to the successful outcome of endodontic treatment (9).

Distolingually located RE varies from short clinical extension to a mature root with normal length(9). Even though genetic factors may strongly influence the presence of RE, the etiology behind the formation of RE remains unknown. This unusual morphology of mandibular molars could be related to the penetrance of an atavistic gene or polygenetic system or due to external factors during odontogenesis(9). Incidence of mandibular premolar with more than one canal or root is likely to be greater than that reported/found because of hidden

images radiographically. The Washington(10) study which assessed the results of endodontic therapy of mandibular second premolar as 4.54%. this may be due to the extreme variation in root canal morphology of mandibular premolar teeth compared with the standard description of one root and one canal and therefore poses an endodontic challenge to clinicians.

Root canal morphology of mandibular premolars and molars can be highly variable and complex and it is often challenging task to carry out successful endodontic therapy with such teeth. Therefore primary step in root canal treatment is identification of internal morphology of canal system as precisely as possible (11). Flat roots are much more likely to contain multiple canals and inter canal ramification. In such cases to obtain predictable results, high quality preoperative radiograph should be available at different horizontal angulations and carefully evaluated to detect the presence of extra root canals. We can also take help of RVG, CBCT and Microscope to negotiate such extra canals.

#### **IV. Conclusion**

Anatomical abnormalities always pose a challenge for clinicians, sound knowledge of normal and its variations should be kept in mind for success of the endodontic treatment. Careful interpretation of radiographs, radiographs with different angulations and other diagnostic aids like RVG, CBCT, microscope helps in managing such abnormalities like Radix Entomolaris and more than two root canals in mandibular second premolar.

#### **References**

- [1]. Prabhu NT, Munshi AK. Additional distal root in permanent mandibular first molars, report of a case. *Quintessence International*, 26(8), 567-9.
- [2]. Segura -Egea JJ, Jimenez-Pinzon A, Rios-Santos JV. Endodontic therapy in a three rooted mandibular first molar, Importance of thorough radiographic examination. *J Can Dent Assoc*, 2002; 68(9), 541-4.
- [3]. Vibha Hegde et al. Radix Entomolaris-Series of case reports. *International jour of advances in case reports*, 2015; 2(4): 216-220.
- [4]. De Moor R, Deroose C, Calberson F. The Radix Entomolaris in mandibular first molars an endontic challenge. 2004; 37(11), 789-799.
- [5]. Cohen S, Burns R. *Pathways of the pulp*. 10th edition. St Louis: Mosby; 2004. p. 366.
- [6]. Slowey RR. Root canal anatomy road map to successful endodontics. *Dent Clin Nort Am* 1979; 23(4): 555-73.
- [7]. Zillich R, Dowson J. Root canal morphology of mandibular first and second premolars. *Oral Surg Oral Med Oral Pathol*. 1973; 36(5): 738-44.
- [8]. Vertucci FJ. Root canal morphology of mandibular premolars. *J Am Dent Assoc* 1978; 97: 47-50.
- [9]. Calberson FL, De Moor RJ, Deroose CA. The Radix Entomolaris and Paramolaris: Clinical approach in endodontics. *J Endod* 2007; 33: 58-63.
- [10]. Ingle JI, Beveridge E, Glick D, Weichman J. The Washington study. In Ingle JI, Taintor JF editor. *Endodontics*, Philadelphia, 1994, Lea and Fabigar, PP 1-53.
- [11]. Nallapati S. Three canal mandibular first and second premolar, a treatment approach. *J Endod* 2005; 31: 474-476.
- [12]. Schafer E, Breuer D, Janzen S. The prevalence of three rooted mandibular permanent first molars in German population. *J Endod* 2009; 202-205.
- [13]. Reichart PA, Metah D. Three rooted permanent mandibular first molars in the Thai community. *Dent Oral Epidemiol* 1981; 9: 191-192.
- [14]. Sudha Mattigatti, Surabhi Rairam, Shivraj S. Wagdargi. Endodontic retreatment of mandibular second premolar with three root canals. *Journal of Dental Sciences and Research* 2012, vol. 3, Issue 1, Pages 31-33.