

No cut ...No Sew...No Fear....An Unusual Clinical Presentation of Localized Gingival Overgrowth –A Case Report

Dr. Seba Abraham, Dr. Anu. R, Dr. Archana .V, Dr. Deepak.KT

Dr. Seba Abraham, (KUHS University, Kerala, India) Dr. Anu. R, (KUHS University, Kerala, India) Dr. Archana .V, (KUHS University, Kerala, India), Dr. Deepak. KT, (KUHS University, Kerala, India)

Abstract: *gingival overgrowth is a matter of concern to both the patient and the practitioner. Gingival overgrowth can be inflammatory, non-inflammatory or combined. Accurate diagnosis and management is a challenge in the clinical practice. The present paper highlights an unusual case report of conditioned gingival enlargement in puberty, modified by mouth breathing habit and its management.*

Keywords: *gingival enlargement, puberty enlargement, gingival inflammation.*

I. Introduction

Alteration in the size of the gingiva is a common clinical sign of gingival disease and is a matter of great concern to the practitioner. Localized and generalized gingival enlargements though a common clinical entity, but finds a unique place in literature, because it has been linked to a variety of local and systemic factors. Hence differential diagnosis becomes an integral part for complete management of the lesion. Most of the etiologic factors lead to an exaggerated tissue response to chronic inflammation associated with local irritants such as plaque, calculus or bacteria and their products¹. Factors that favor plaque accumulation include poor oral hygiene, improper restorative and orthodontic appliance and irritation by anatomic abnormalities². Drying of gingiva due to mouth breathing is also reported to cause chronic inflammatory enlargement, but this association between mouth breathing and gingivitis has only been sparsely reported in the literature.³ The available reports are conflicting. Jacobson et al 1973⁴ reported a definite association, Alexander [1970]⁵ and Jacobson [1972]⁶ reported a partial association in the presence of other factors like presence of crowding and calculus while Sutcliffe [1968]⁷ reported a lack of association.

It is well documented that hormonal changes occurring during puberty and pregnancy. It may result in varying types of gingival enlargement. Hormonal changes can significantly alter the tissue response to local irritants and can significantly potentiate the effect of local irritants on gingival connective tissue.⁸ However; good oral hygiene measures can significantly minimize the effect of systemic factors. The clinical features are similar to chronic inflammatory gingival disease.⁹

Alterations in the size of gingiva favor plaque accumulation and interferes with routine oral hygiene measures, mastication, phonation, esthetic problems and psychological difficulties for the patient. Hence timely management of gingival enlargement is crucial. Various treatment modalities are available which include conventional surgical technique, electro surgery and/or lasers.¹⁰ Conventional gingivectomy procedures are a challenge for dentists who confront issues of patient cooperation and discomfort. It is well documented that laser soft tissue surgery has been well accepted by children. The following case report describes a laser-assisted gingivectomy procedure performed on a 13-year-old female.

II. Case Report

A 13-year-old female was referred to the department of periodontics, PMS College of dental science and research, Trivandrum, India with the chief complaint of unaesthetic swelling on her upper right gum since 2 years. Patient noticed a gradual increase in size of her gums and occasional bleeding while brushing. Her medical history and family history were non-contributory. She did not give any drug history that could have induced gingival enlargement.

On general examination patient was medium built and her height and weight were considered to be in normal limit. Routine blood investigations were performed and reported to be within normal limit. Extra oral examination revealed bilateral facial symmetry and the overlying skin showed no signs of inflammation. Patient had an open bite and incompetent lips, hence had a mouth breathing habit.

Intraoral examination revealed a generalized grade I gingival enlargement with diffuse grade III enlargement in relation to 15, 14, 13, 12 region [fig 1, 2, 3, 4] covering more than two third of the clinical crown on the facial aspect¹¹. It appears to be deep reddish pink in colour with physiologic pigmentation and was fibrotic in consistency. At isolated areas inflammatory changes were seen. Surface of the swelling had a peddled appearance and was non-tender [fig 3]. Oral hygiene status of the patient was fair and slight bleeding on probing was noticed. Pocket depths recorded were between 3 to 9 mm that characterizes more of pseudo-pocket. The

examination of occlusion revealed labioversion of anterior teeth. Orthopantomographic examination revealed normal radiographic appearance with no alveolar bone loss. Based on the above findings a provisional diagnosis of conditioned gingival enlargement in puberty modified by mouth breathing was given.

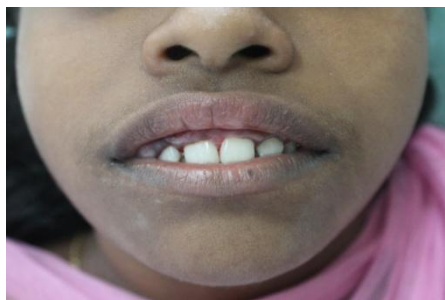

fig1

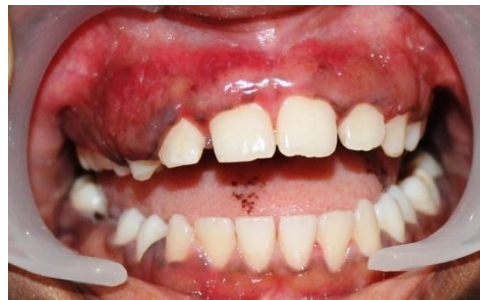

fig2

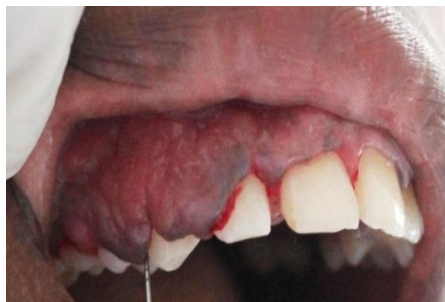

fig3

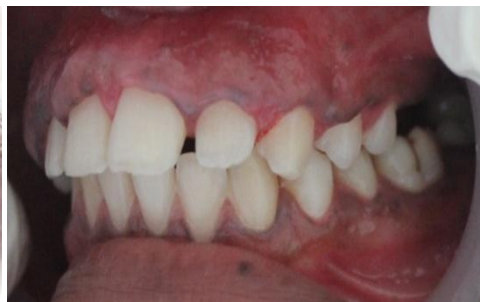

fig4

Histopathologic findings

During the procedure ,part of marginal and the interdental gingival tissue were excised from the facial aspect of the most posteriorly involved teeth and were send for histopathologic examination. Histologically the soft tissue section showed atropic parakeratinised stratified squamous epithelium and associated fibro vascular connective tissue. Pseudo epitheliomatous proliferation is noted in few areas. Connective tissue is moderately collagenous and cellular with numerous vascular spaces. Melanin incontinence and dense chronic inflammatory cell infiltrate composed predominantly of lymphocytes and plasma cells are within the connective tissue. Gingival hyperplasia occurs mainly due to an increase in the thickening of mature collagen bundles in the connective tissue stroma. ¹² Thus based on history, clinical, radiographic, hematologic and histopathological examination diagnosis was confirmed as conditioned gingival enlargement associated with puberty and modified by mouth breathing habit. (fig5)

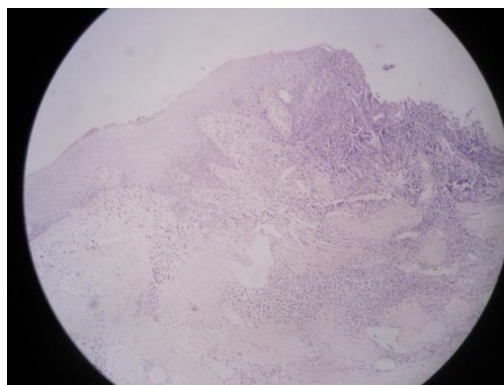


fig5

Case management

The patient was subjected to phase 1 therapy consisted of supragingival ((Satelec ,France)) and subgingival scaling ,root planning (Hu Friedy;Chicago ,USA) and polishing of all teeth . Oral hygiene instructions were given and patient was instructed to rinse with 0.2 % chlorhexidine mouthwash twice daily for 1 week. Patient was reevaluated after four weeks, there was marked reduction in gingival inflammation but the gingival enlargement was persistent and evident. Hence surgical intervention was necessary. Various surgical

treatment modalities including conventional surgical technique, electro surgery and lasers were explained to the patient. Since the patient was apprehensive, she opted for laser assisted gingivectomy.

The surgical site was anesthetized using precaine gel .A high volume suction device was used during the procedure. The laser headpiece (Picasso by AMD lasers, USA) was initiated using a 600 μ tip at 2.2W in pulse mode with 50% duty cycle to allow for thermal relaxation and patient comfort. In a sweeping motion the incision design was placed according to the gingival contour and architecture, keeping the laser tip perpendicular to the tissue and thereafter the tissue was undermined up to the level of gingival sulcus keeping the laser tip parallel to the long axis of the tooth. The bulk of tissue apical to gingival margin was reduced by sweeping motion of the lasers tip. (Fig , 6,7)

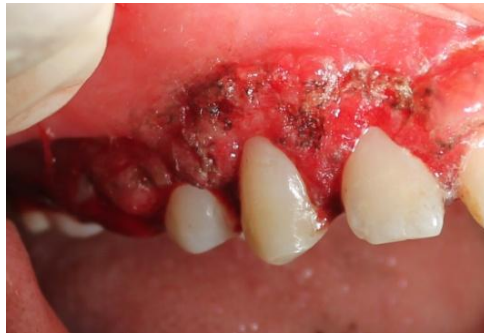

fig6

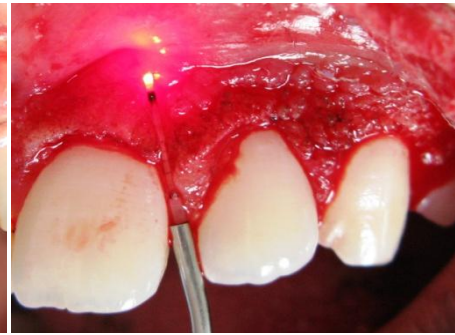


fig7

Patient was instructed to take analgesics for two days postoperatively if necessary and no periodontal dressings were required. Standard postoperative instructions were given and the patient was recalled on the next day, day 3, 7 and one month for the site examination. Postoperative healing was uneventful. (Fig 8,9,10) Patient is still under maintenance visit and no recurrence was reported. Patient is currently undergoing orthodontic treatment for the anterior open bite correction.

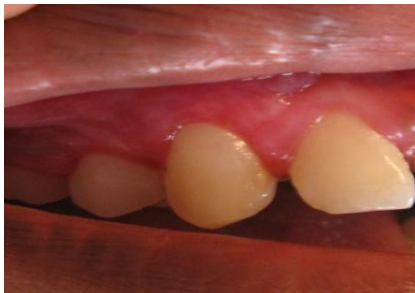

Fig 8

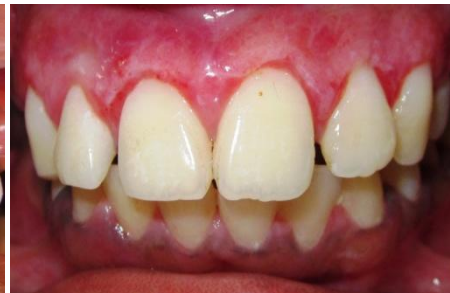

fig9

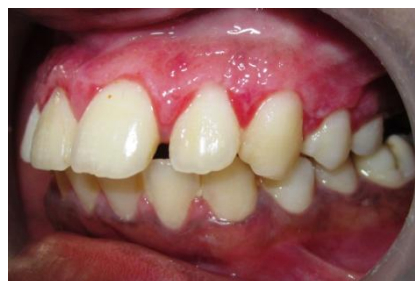

fig10

III. Discussion

Gingival enlargements are quite common and may be inflammatory, non inflammatory or a combination of both.¹³ Chronic inflammatory gingival enlargement is the result of prolonged exposure to dental plaque, improper restorations and mouth breathing habits. In mouth breathers maxillary anterior region is the most commonly involved site and reports suggests that irritation from surface dehydration is responsible for the gingival changes. However the exact cause is still to be elucidated.¹⁴ In our case the patient had open bite and mouth breathing habit and the enlargement was confined to the maxillary anterior region.

The enlargement associated with puberty has all the clinical features similar to chronic inflammatory gingival disease. Studies have reported that chronic inflammatory enlargement is an exaggerated response to

local plaque due to high amount of gonadotropic hormones .¹⁵ These hormones increases the permeability of blood vessels which will contribute to the pronounced gingival enlargement .Puberty does not alter healthy gingiva, it affects the severity of previously inflamed gingiva. Enlargement in puberty occurs both in male and female adolescences and often labial gingival are affected than lingual gingiva. These findings are similar to the findings in this case, were the patient is an adolescent and diffuse enlargement was confined to the labial gingiva. An increase in gingival inflammation without concomitant increase in plaque levels in adolescents has been reported.^{16, 17}. However few studies are reported negative correlation between pubertal onset and gingival condition in females^{18, 19}. Kornman and Loesch(1982)²⁰ reported that subgingival flora changes to a more anaerobic flora that substitute ovarian hormone for vitamin K growth factor and selective enhancement of P. Intermedia has been reported during this period. They substitute estradiol and progesterone for menadione an essential vitamin K growth factor for this bacteria²¹. Capnocytophaga.sp also increased in proportion during puberty and have been shown to correlate with increased gingival bleeding tendency.²² Hence in adolescents maintenance of oral hygiene is very important to reduce the incidence and severity of gingival inflammation and enlargement.

Diffuse gingival enlargement is found to be associated with syndromes like Cross syndrome, Rutherford syndrome, Ramen syndrome, Zimmermanlaband syndrome and juvenile hyaline syndrome²³. In our case all these syndromes were ruled out by taking proper history, clinical, histological and hematological examination. Based on all the above findings the case was diagnosed as conditioned gingival enlargement in puberty (pubertal gingival enlargement) modified by mouth breathing.

Pubertal gingival overgrowth harbor plaque and may interfere with oral hygiene measures. Hence to accomplish an esthetic and functional outcome surgical reduction of the overgrowth is necessary. Though conventional surgical technique is simple and cost effective, the associated bleeding limits its use. Compared to conventional surgical technique Electro surgery can achieve adequate hemostasis and can effectively excise gingival tissue .However the heat generated, can cause irreversible damage to the alveolar bone.²⁴ Recently, lasers have been used for periodontal therapy. The 810 nm diode laser is suited for soft tissue procedure since it is highly absorbed in hemoglobin and melanin. It can precisely cut, coagulate and ablate or vaporize the target tissue with less trauma, excellent hemostasis, clean surgical field and improved post operative healing .^{25, 26} However the laser wound is a very superficial wound and the thermal damage caused by irritation is only a few tenths of a millimeter in depth. The diode laser produce a blood less environment as well as a clean surgical field that helps in successful management of enlargement. Laser assisted gingivectomy was well tolerated by the patient and the patient was happy with the outcome.

IV. Conclusion

Gingival enlargement can be of varied reasons. Arriving to the correct diagnosis depends on clinical, radiographic and histopathologic examination supported by laboratory investigations. Control of gingival inflammation and maintenance of effective oral hygiene are key factors in managing gingival over growth. Lasers offer an excellent alternative to other treatment modalities and it should be used judiciously. Gingivectomy using lasers can yield a satisfactory clinical response. However follow-up is mandatory.

References

- [1]. Ragezi JA, Sciubba J (eds): Oral Pathology, Clinical-Pathological Correlations, 2nd edition. Philadelphia; WB Saunders. 1993; pp196-202.
- [2]. Hirshfield I: hypertrophic gingivitis :its clinical aspects, I Ann Dent Assoc 19:799,1932
- [3]. Gulati MS, Grewal N, Kaur A. A comparative study of effect of mouth breathing and normal breathing on gingival health in children. J. Ind Soc. Pedo. Prev Dent, 16:72-83
- [4]. Jacobson L 1973 mouth breathing: gingivitis J. periodontol. res, 8:269-277
- [5]. Alexander AG 1970 ,habitual mouth breathing and its effect on gingival health. parodontologie:49-5
- [6]. Jacobson L, Liander A, Rowson (1972) crowding and gingivitis: A comparison between mouth breathers and non mouth breathers. J. Dent. 1: 500-504
- [7]. Sutcliffe P: Chronic anterior gingivitis. An epidemiological study in school children. Br Dent J 1968; 125:47
- [8]. Daley TD, Nartey NO, Wysocki GP. Pregnancy tumor: an analysis. Oral Surg Oral Med Oral Pathol 1991; 72:196-199.
- [9]. Maier AW, Orban B. Gingivitis in Pregnancy. Oral Surg 1949; 2:234.
- [10]. Emmerson TG. Hereditary gingival hyperplasia. A family pedigree of four generations. Oral Surg Oral Med Oral Path 1965; 19:1-4.)
- [11]. Bookenkamp A, Bahuharst B, Beier C, Albers N, Offner G, Brondehl J. nifedipin aggravates cyclosporine a induced gingival hyperplasia. pediatr nephol 1994; 8:181-185
- [12]. Zachin SJ, Weisberger D. Hereditary gingival fibromatosis - report of a family. Oral Surg Oral Med Oral Pathol 1961; 14:825-35.
- [13]. R. Rajendran and B. Bhivaparthasundaram: shafers text book of oral pathology .5th ed Elsevier 2007, page 543-548
- [14]. Joseph P, Fiorellini, David M, Kim, and Satoshi O, Ishikawa. Gingival enlargement .in Newman , Takei, Carranza. Clinical periodontology, 9th ed, 374- 375.
- [15]. Mariotti A . Sex steroid hormones and cell dynamics the periodontium. Crit rev oral bio med 1994; 5:27-53
- [16]. Nakagawa s, Fujii H, Machida Y, Okuda K. A longitudinal study from prepuberty to Puberty of gingivitis. Correlation between the occurrence of Prevotella intermedia and sex hormones. J clin periodontal 1994; 21:658-665

- [17]. Nanba H,Nnomura Y. Kkinoshita.M, Shimizu H, Ono K,Goto H, Aral H ,Takigawa.M, Murayama.Y. Periodontal tissues and sex hormones. Effects of sex hormone on metabolisam of fibroblasts derived from periodontal ligament. Nippon shishubyoGakkaikaishi 1989;1:166-175
- [18]. Tiainen.L,AsikainenS,Saxen L, Puberty associated gingivitis.community dent oral epidemiol 1992;20:87-89 .)
- [19]. YangoverL,Ellen R. Clinical and microbiological examination of gingival disease in parapubescentfemales.j periodontal 1986;57:562-567)
- [20]. KornmanK S. Loesche WJ effects of estradiol and progesterone on bacteroidesmelaninogenicus and bacteroidesgingivalis.infect immune 1982;35:256-263
- [21]. KornmanK S. Loesche WJ effects of estradiol and progression on bacteroidesmelaninogenicus . J dent res 1979;58A:107
- [22]. MombelliA,Lang NP, Burgin W B et al:miracle changes associated with the develop: of puberty gingivitis, J periodontal Res 25:331,1990.
- [23]. Shekar:idiopathic gingival fibromatosis;Saudi dental journal ,2002;14(3):143-145
- [24]. Kalkwarf KL, Krejci RF, Edison AR, Reinhardt RA. Lateral heat production secondary to electrosurgical incisions. Oral Surg Oral Med Oral Pathol 1983; 55:344-8.
- [25]. PimatS. versatility of an 810 nm diode laser in dentistry :an over view .journal of laser and health academy vol:2007 no.4 1 -8
- [26]. RossmanJA ,Cobb.C.M. lasers in periodontal therapy. periodontol 2000;1995;150-164.