

“Comparison of the Surgical Methods in Combined Surgical - Orthodontic Correction of Impacted Teeth”

Dr. Rahamathulla Khan, Dr. Verdine Virginia Antony,
Dr. Nureldeen Elhammali

¹ (Head of Department, Department of Orthodontics & Dentofacial Orthopedics,
Sirte University, Libya.)

² (Head of Department, Department of Periodontics & Implantology,
Sirte University, Libya.)

³ (Head of Department, Department of Oral & Maxillofacial Surgery,
Sirte University, Libya.)

Abstract: *Impacted canines are a relatively common finding in dental practice. After the third molar, the maxillary canine is the most frequently impacted tooth, followed by the maxillary central and lateral incisors. The prevalence of impacted maxillary canines is reported to range from 1.5 to 4%. The maxillary impacted canine is more frequently located palatally (85%) than labially (15%). The orthodontic-surgical management of impacted canines requires accurate diagnosis and precise location of the impacted canine. There are different techniques to surgically expose the impacted teeth, they are – Gingivectomy technique, Apically positioned flap, closed eruption technique, Modified apically positioned flap, Double pedicle flap and Free gingival graft. Selection of the procedure is dependent on the positioning of the tooth in relation to the muco gingival junction and attached gingiva. In the present case series we describe three different techniques for uncovering the impacted teeth, which are closed eruption technique, apically positioned flap, and a modified apically repositioned flap. These procedures when selected diligently using sound selection criteria will create adequate width of attached gingiva, which minimizes or eliminates the future mucogingival problems.*

Keywords: *Closed eruption, Apically positioned flap, Modified apically repositioned flap, Mucogingival interceptive surgery.*

I. Introduction

Most permanent teeth erupt into occlusion uneventfully and replace their primary precursors. In some individuals, however, the permanent teeth may fail to erupt and become impacted within the alveolus. The causes of impaction may be due to retained primary tooth, diversion of eruption of the tooth bud, or idiopathic failure of eruption. Other causes for impaction can be attributed to the presence of supernumerary teeth, soft or hard tissue obstruction. In some cases the tooth may be impacted due to idiopathic rotation of the tooth during development.[1,2] .These impacted teeth can be surgically uncovered using different surgical techniques. During exposure of the impacted teeth care should be taken to preserve as much keratinized gingiva as possible. An adequate amount of keratinized gingival tissue under proper plaque control is a fundamental requirement for periodontal health. Lack of attached gingiva pose a potential risk for gingival recession in labially or buccally erupted teeth due to the possibility of accumulation of plaque and/or traumatic tooth brushing during subsequent orthodontic treatment [3]. The timing of orthodontic treatment, type of surgical procedure employed to uncover the impacted tooth, orthodontic mechanics necessary, vary depending on the tooth that is impacted.

II. Diagnosis Of The Impacted Teeth

The orthodontic-surgical management of impacted teeth requires accurate diagnosis and precise location of the impacted teeth and the surrounding structures. In labial impactions, this often can be done by palpation, however in palatal and middle alveolus impactions, use of periapical radiographs and occlusal radiographs plays a major role [4,5].

The panoramic radiograph is the basic radiograph for detecting impacted teeth because it provides an overall view of the maxilla, mandible, alveolar processes, dentition and nasal fossae.

Periapical films can also provide important information for the treatment of impacted teeth. By taking two or more periapical films of the same region with different angulations of the x-ray source and a long-cone technique, it is possible to determine tooth position employing the Clark's rule.

Occlusal radiographs are a useful supplement to other radiographic examinations, providing a third, horizontal dimension to assess the size of the maxilla. Occlusal radiograph can be used with an orthogonal technique, a lateral technique or a combination of both.

Computerized tomography (CT), or cone-beam computerized tomography (CBCT) play a major role in the planning of surgical exposure of impacted teeth, as well as improve clarity and facilitate communication between the dentist and the patient.

III. Surgical Techniques [6,7,8,9,10,11]

Four techniques can be employed to uncover impacted teeth. The type of impacted tooth and its location within the alveolus will dictate selecting the appropriate technique to uncover an impacted tooth.

Gingivectomy:

A simple excision of gingiva can be accomplished with a sharp blade. This technique is indicated when there is a wide zone of attached gingiva, bone removal is not needed, and one-half to two-thirds of the crown can be exposed, leaving at least a 3 mm gingival collar. The most common area where this technique may be employed is over the labially impacted maxillary canine and/or central incisor.

Apically Positioned Flap:

A split thickness flap is reflected from the area adjacent to the impacted tooth. Appropriate bone removal is accomplished, and the flap is sutured apically, exposing about two-thirds of the crown. This technique most often is employed on “simple” labially impacted teeth.

Closed Eruption Technique:

A crestal incision is made and buccal and/or lingual flaps are reflected. Appropriate bone removal is accomplished, and a bracket or chain is attached to the impacted tooth. The flaps are returned to their original location for complete closure. The chain passes under the flap, exits at the mid-crestal incision area, and is attached to the archwire. This technique is best used with high labially impacted teeth and teeth that are impacted in the mid-alveolar area. With appropriate orthodontic mechanics, the tooth can be erupted, mimicking its natural eruptive path through the mid-crestal area.

This article highlights in its case series, the different interceptive surgical procedures employed for uncovering impacted tooth emphasizing the effective technique to maintain keratinized tissue and preventing the ectopic permanent tooth from developing periodontal lesions.

3.1 Case 1:

A 24 year old female patient was referred from Department of Orthodontics to the department of Periodontics for surgical exposure of impacted maxillary left canine (Figure: 1.1, 1.2). Clinical examination did not reveal anything significant about the position of impacted tooth. Radiographic procedures using an occlusal view and object localization technique using periapical radiographs revealed palatally impacted canine.

Surgical procedure: Closed Eruption technique

A closed eruption technique was planned and was performed under local anesthesia. A mucoperiosteal flap was reflected palatally extending from left second premolar to the right canine for proper access. The prominence created by the tooth in the palatal bone was palpated and was used as the guideline for removal of bone covering the tooth in order to uncover the impacted tooth. The bone and the follicular connective tissue covering the tooth was then removed and the area debrided. Sufficient tooth structure was exposed for bonding the orthodontic button with the ligature wire tied to it. (Figure: 1.3).

The flap was returned to its original location for complete closure and the ligature was brought out of the mucosa, by piercing it just above the impacted tooth. This ligature wire, which was projecting out of the palatal mucosa, was connected to the orthodontic arch wire using a Ballista spring, three weeks later and activation was started. (Figure: 1.4). The third week post-operative examination revealed adequate healing of the tissues

3.2 Case 2:

A 22 year old female patient was referred from the Dept. of Orthodontics to the department of Periodontics for surgical uncovering of an impacted tooth. She had an unerupted upper left permanent canine, which was labially impacted (Figure: 2.1).

On examination upper left canine was unerupted, labially displaced, & was easily palpable beneath the gingiva & alveolar mucosa at the MGJ. The radiographs showed closed root apices and ectopic eruption of canine whose path of eruption was against the adjacent lateral incisor. The amount of space available between the lateral incisor and the premolar for the canine was optimal but was blocked due to aberrant eruption direction. A gingivectomy procedure could have led to loss of attached gingiva and therefore an apically positioned flap procedure was planned. The apically positioned flap would transform into the attached gingiva on complete eruption of the canine.

Surgical procedure: Apically positioned flap technique

The area was surgically exposed under local anesthesia, by placing two vertical releasing incisions mesial & distal to the unerupted canine extending beyond the mucogingival junction (MGJ). A crestal incision was given in the edentulous region connecting both the releasing incisions. A full thickness flap was then raised beyond the MGJ and then continued as a partial thickness flap so as to leave the periosteum covering the bone. The flap was then positioned apically covering the bone crest and 2mm of crown portion. The flap was sutured using a 3-0 silk suture. (Figure: 2.2). An orthodontic button bracket was bonded on the surgically exposed tooth under proper isolation (Figure: 2.3).

The patient was reviewed after a week. The healing appeared to be satisfactory. The orthodontist started the force application during the same appointment. The patient was scheduled for a review after one month. At one month follow up the canine had erupted halfway into the space between lateral incisor and premolar and showed about 3 to 4mm of keratinized mucosa. At the 3 month follow up the canine was alignment and showed a healthy keratinized gingiva of around 4 mm with a gingival sulcus of around 1.5mm (Figure: 2.4).

3.3 Case 3:

A 28 year old male patient was referred from the Department of Orthodontics to the department of Periodontics for surgical uncovering of multiple unerupted teeth (Figure: 3.1). On examination the crown of the maxillary right canine was seen piercing through the labial gingiva located midway between the mucogingival junction and the alveolar ridge. Clinically the position and location of central and lateral incisors could not be appreciated. Object localization technique using radiographs showed labially placed central and palatally placed lateral incisors. The left first premolar was also impacted and the radiographs revealed a buccal impaction.

Surgical procedure: Modified Apically repositioned flap:

A routine gingivectomy procedure for this case would have removed the entire attached gingiva leading to mucogingival problems. Therefore in this case the palatal mucosa and the mucosa adjacent to the edentulous ridge were incorporated into a double pedicle graft [10,11]. This case describes the incorporation of palatal mucosa and the adjacent mucosa of the edentulous ridge into a double pedicle graft [12] resulting in adequate keratinized tissue and gingival margin. An intrasulcular incision was given around the right upper first premolar extending from the disto-buccal line angle to mesio-palatal line angle. Further a crestal incision was planned which would incorporate sufficient palatal mucosa to reconstruct the attached gingival margin on the labial aspect of canine. The incision was started from the premolar region and continued superiorly into the attached gingiva, in a curved fashion. This incision extended till the mucogingival junction area, approximately 4 to 5 mm mesial to the canine. The gingiva which was entrapped at the canine cusp was released and elevated and was then moved to a position apical to the impacted tooth (Figure: 3.2). Sutures were placed (Figure: 3.3) and the patient was recalled after 1 week for suture removal & orthodontic button placement. Six weeks post-op examination showed a keratinized tissue of about 4 mm labial to canine (Figure: 3.4). This simple modification enabled us to incorporate the palatal mucosa and reconstruct the attached gingiva on the labial aspect of the canine, which compensated for the deficient labial mucosa on the canine. The modification was also necessary due to the presence of the adjacent edentulous area.

IV. Discussion

Mucogingival interceptive surgery appears to be an effective approach to provide the buccally erupting teeth with a satisfactory amount of keratinized tissue to withstand unfavorable effects due to inadequate oral hygiene habits during & after orthodontic treatment. Specific surgical techniques would depend on the clinical aspects related to the distance between the buccally erupting cusp of the permanent tooth & the deciduous tooth. Periodontal health & esthetics of those teeth showing an initial aberrant eruption are obtained by proper usage of interceptive procedures, which otherwise would be lost.

The selection of the cases for this study was based on the clinical and radiographic criteria to establish the position of the impacted teeth. Several uncovering procedures like simple gingivectomy (window approach) [7], apically positioned flap [8,9,10], double pedicle graft [9,10] and free gingival grafts [8,10] have been successfully used to treat submucosal impactions. However, these techniques have certain limitations:

- When APF is used for very high or laterally displaced impactions, accessory frenula can be created in the vertical incision area and orthodontic relapse has been observed in some patients. Gingivectomy and double pedicle grafts cannot be used in such situations.
- APF carries a greater risk of recession and uneven gingival margins this can cause unesthetic problems when the patient has high smile line.
- Mid-alveolar impactions are inaccessible without considerable labial bone removal.
- Impactions located near the nasal spine are impossible to leave uncovered.

Thus cases of mid alveolar, palatal and deep intraosseous impactions need to be managed using closed eruption [7,9] or tunnel traction techniques [2].

However, closed eruption technique carries two potential problems namely

- Debonding of the bracket could occur and when this happens, it requires a second surgery to uncover and rebonding the bracket on the impacted crown.
- If improper orthodontic methods are used, a mucogingival problem can be created in the form of inadequate attached gingiva when the tooth erupts through the mucosa or close to the MGJ.

These two problems can be prevented by using proper restorative and orthodontic techniques.

Invariably all the procedures have some inherent drawbacks in them, which can be avoided by judicious selection of the procedure depending on the location of the impacted tooth in relation to the MGJ and whether the tooth is placed labially, palatally or in mid alveolar regions.

In the present case series a closed eruption technique, Apically positioned flap and modified apically repositioned flap, were successfully used to create adequate amount of attached gingiva.

In the first case where the patient presented with palatally impacted canine, closed eruption technique was the technique chosen for the treatment, as all other procedures could not be performed. Adequate care was taken to overcome the problems of debonding and improper orthodontic mechanics associated with closed eruption techniques. During the surgical procedure, after bonding the orthodontic button a hemostat was used to check the adequacy of bonding. A Ballista spring was then placed during orthodontic force application to create proper tooth eruption direction. Orthodontic force activation was started few weeks after the surgical procedure.

In the second case, where the patient presented with a labially impacted canine, an apically positioned flap procedure was undertaken, as a gingivectomy procedure could have led to loss of attached gingiva. Following the flap elevation adequate care was taken that the remaining connective tissue was removed from the labial surface of the tooth. Further any bone that impeded the eruption of tooth should be removed & the flap properly adapted (however, no bone was covering the tooth in the present case). As recommended by many authors, bone was not to be removed from the cemento-enamel junction, as it is this area where the attached gingiva is required to gain attachment. Ideally, the flap also covered 2-3 mm of the crown due to which an optimal tissue attachment to radicular and cemental tissues was achieved. Three months post-operative, the apically positioned flap had transformed into the attached gingiva on completely erupted canine.

In the third case, multiple impacted teeth were present. Maxillary right central incisor, lateral incisor and canine were impacted. Object localization technique using radiographs showed labially placed central and palatally placed lateral incisors. All these teeth needed surgical exposure. A gingivectomy procedure could lead to removal of all the attached gingiva for the canine and result in an alveolar mucosal attachment. An apically repositioned flap could not be used, as the gingival tissue was perforated in one area by the impacted canine and the keratinized mucosa available above the perforation would be inadequate. Hence a modified apically repositioned flap for the present situation was planned and executed to success. [10,11]. The presence of edentulous ridge, deficient labial keratinized mucosa on the canine & multiple impacted teeth necessitated the use of a different & unique technique to create sufficient keratinized labial gingiva. Thus the modified technique successfully created 4 mm of keratinized tissue, labial to the impacted canine.

The surgical exposures of other impacted teeth were planned in the future appointments, but the incision, which was given for the double pedicle graft actually uncovered the crowns of lateral and central incisors also. Both the teeth did not have any bony covering, making the exposure easier. Orthodontic buttons were placed over all three teeth and activation of forces started at 6 weeks. The highly placed central incisor had no attached gingiva over the labial surface, but the direction of eruption would be in such a way that, it erupts through the crest of alveolar ridge (mimicking the eruption of natural teeth) & creating attached gingiva on its labial aspect.

This case series shows the use of three different surgical procedures for uncovering impacted teeth, which when used judiciously gives excellent results & helps in preventing future mucogingival problems.

V. Conclusions

All surgical procedures used in this case series produced optimal keratinized tissue on the labial surface. This case series shows that the mucogingival interceptive surgeries, when used judiciously and at appropriate time can be helpful in preventing future mucogingival problems. This requires a coordinated approach on the part of both the periodontist & the orthodontist, which would ultimately benefit the patient in maintaining a trouble free periodontium.

References

- [1]. Vermette ME, Kokich VG & Kennedy DB. Uncovering labially impacted teeth: apically positioned flap & closed eruption techniques. *Angle Orthod.* 1994; 65 (1): 23-34.
- [2]. Crescini A, Clauser C, Giorgetti R, Cortellini P, Prato GP. Tunnel traction of infraosseous impacted maxillary canines. A three-year periodontal follow up. *American journal of Orthodontics and Dentofacial Orthopedics* 1994; 105: 61-72.
- [3]. Kokich VG & Mathews DP. Surgical and orthodontic management of impacted teeth. *Dent Clin of N.Amer* 1993; 37 (2): 181-204
- [4]. Stafne EC, Gibilisco JA. Oral roentgenographic diagnosis. In: Stafne EC, Gibilisco JA, eds. *Oral Roentgenographic Diagnosis* 4. Philadelphia: B. Saunders Co., 1975; pp.40–50.
- [5]. Richards A. The buccal object rule. *Dental Radiography and Photography* 1980;3:53
- [6]. Wisth PJ, Norderval K, Boe OE. Comparison of the surgical methods in combined surgical-orthodontic correction of impacted maxillary canines. *Acta Odont Scand* 1986; 34: 52-57.
- [7]. Watchel HC. Session 11. In: Lang NP, Karring T, eds. *Proceedings of the 1st European Workshop on Periodontology Surgical-periodontal therapy* pp.159-171. London: Quintessence, 1994.
- [8]. Prato GP, Clauser C & Zuccati G. Pure mucogingival concerns of patients scheduled for orthodontics: A European view. *Decision making in Periodontology*, 2nd edi. St. Louis: CV Mosby; 1993; 96-97.
- [9]. Prato GP, Clauser C & Cortellini PP. Periodontal plastic and mucogingival surgery. *Periodontol* 2000 1995; 9:90-105.
- [10]. Prato GP, Baccetti T, Magnani C, Agudio G & Cortellini P. Mucogingival interceptive surgery of buccally-erupted premolars in patients scheduled for orthodontic treatment. I. A 7- year longitudinal study. *J periodontol* 2000; 71: 172-181.
- [11]. Prato GP, Baccetti T, Giorgetti R, Agudio G & Cortellini P. Mucogingival interceptive surgery of buccally-erupted premolars in patients scheduled for orthodontic treatment. II. Surgically treated versus nonsurgically treated cases. *J periodontol* 2000; 71: 182-187.
- [12]. Crean St J, Banu B & Coonar H. Modified apically repositioned flap in the treatment of unerupted maxillary central incisors. *Dent Update* 2000; 27: 137-139.

Case 1:

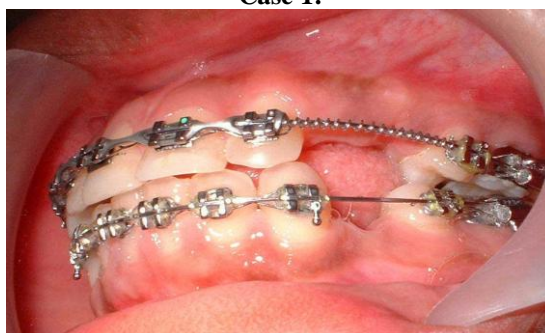

Figure 1.1: Pre-op (labial view), showing edentulous area in relation to upper left canine region

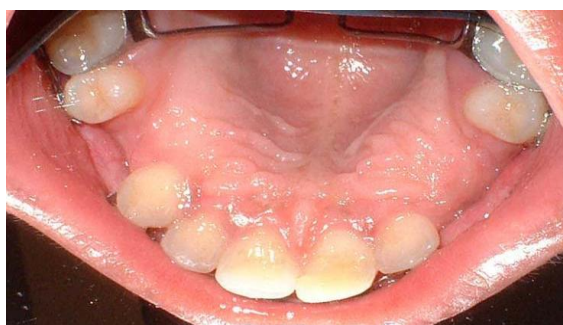

Figure 1.2: Pre-op (palatal view), showing edentulous area in relation to upper left canine region

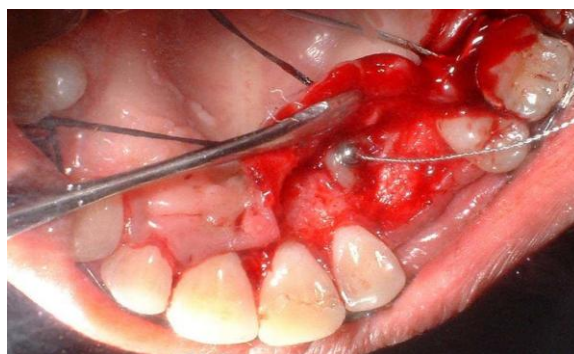

Figure 1.3 Surgical exposure of canine and bonding of orthodontic button with a ligature wire tied to it for closed eruption technique

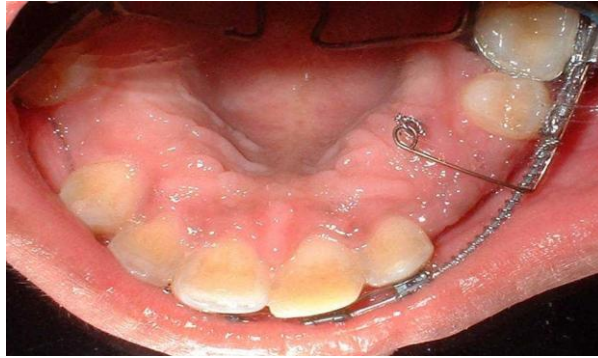

Figure 1.4: Post-op 3 weeks. Ballista spring connected to arch wire for eruption of canine

Case 2:

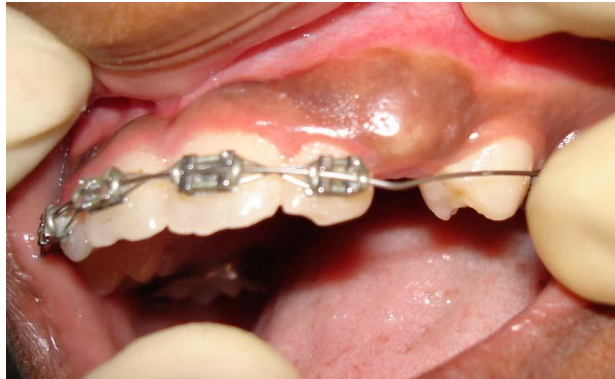

Figure 2.1 Pre-op, showing the edentulous area at upper left canine region & the prominence created by the labially impacted tooth

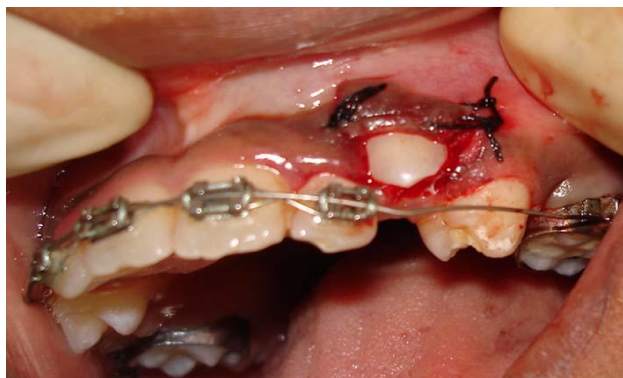

Figure 2.2: Flap apically positioned and sutured

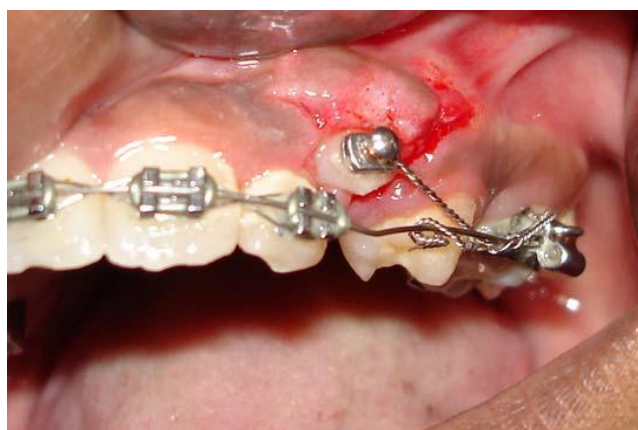

Figure 2.3: Post-op 1 week showing orthodontic button with a ligature wire

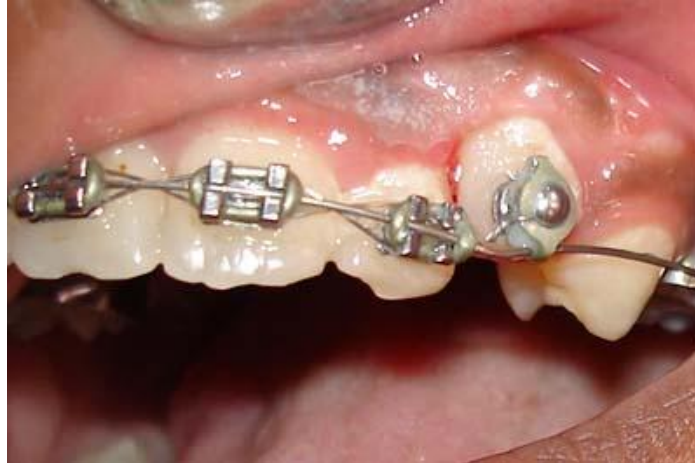

Figure 2.4: Post-op 3 months. Showing erupted canine and healthy keratinized gingiva

Case 3:

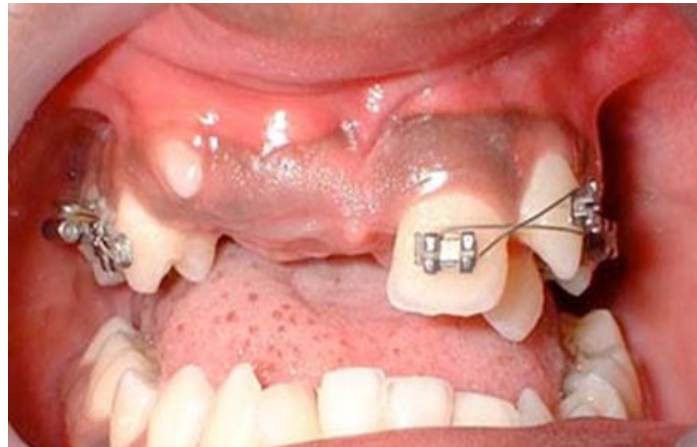


Figure 3.1 Pre-op, showing edentulous area extending from right upper canine to left central incisor

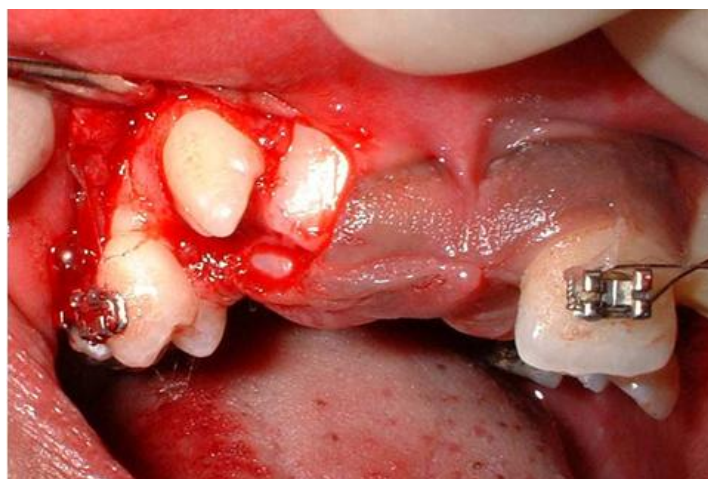


Figure 3.2 Gingiva reflected & positioned apically to the impacted tooth

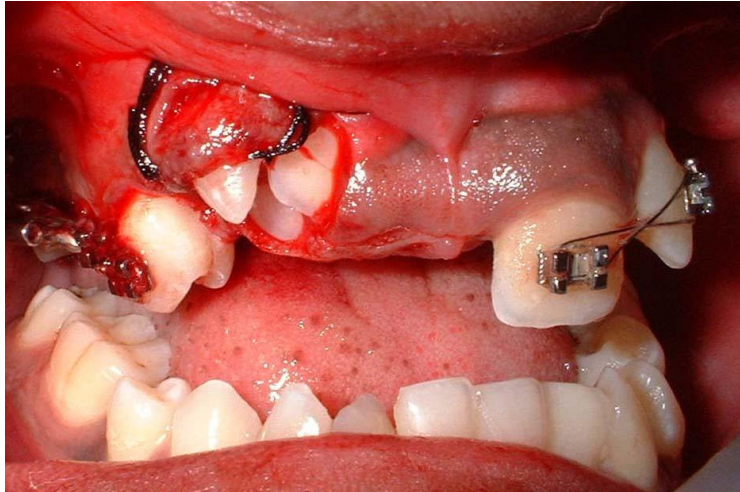


Figure 3.3: Modified apically repositioned flap suture

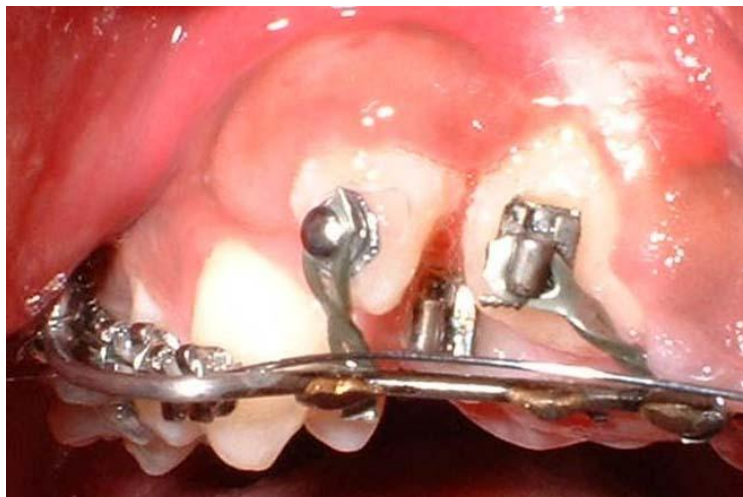

Figure 3.4: Post-op 6 weeks, showing presence of adequate keratinized tissue over canine.