

Mid Ramal Point (MRP) an Anatomical Landmark to Mandibular Foramen on Lateral Ramal Surface

M.K Mattoo¹, Jatinder Mohan² & Tarsem kumar³

^{1(a)}HOD and Professor of Department of Anatomy at National Dental College and Hospital Dera Bassi,

^{1(b)}Practitioner at Baltana Zirakpur & MDS from National Dental Coll And Hospital Dera Bassi (Pb). ²lecturer of Anatomy at Yamuna instt of Dental Sciences and Research, Yamuna Ngr Haryana INDIA.

Abstract: Mandible is the only movable bone in the facial skeleton. Mandibular abnormalities, its fractures are more common. In majority of cases they occur in the ramus of the mandible. The medial surface presents the mandibular foramen which contains neurovascular bundle leads into an inferior alveolar canal in the body of the mandible. Anteromedially the foremen is overlapped by a thin boney triangular lingula. The correction of mandibular deformities and treatment of ramal fractures and osteotomy procedures the mandibular ramus is approached from the external surface. So it is important to know exactly where the bone cut should made to prevent damage to neurovascular bundle, which may lead to permanent sensory loss and paralysis to muscles, mylohyoid and ant belly of digastrics. Various anatomical land marks have been proposed to guide the surgeons in locating the mandibular foremen. Caldwell and Letterman 1954 [1] made reference of a boney prominence or Antilingula present occasionally on the lateral surface of the ramus, coinciding the mandibular foremen on the medial surface. Alling (1961)[2] described a boney bulge on the lateral ramal surface coinciding mandibular foramen. Thoma (1961)[3] Described a small elevation on the surface of bone for the localization of the foremen. In present study on 50 dry mandibles done in the department of anatomy of national dental college concluded with Mid ramal point was formed by joining the four lines from the midpoint of anterior, posterior, superior, and inferior borders of the mandible. This point was marked on both surfaces of the mandibular rami which was measured in relation to mandibular foramen on gross study clinically and radiographically. It is also suggested that for oral surgeries during ramal osteotomies mid ramal point can be located by joining the 1) inferior point on the sigmoid notch and 2) anterior border of ramus just behind the third molar tooth (Midpoint of anterior border) with the 3) Midpoint of posterior border of the mandible. In the present study it was found that 76 out 100 mandibles Mid ramal point (MRP) coincided with the mandibular foremen where as in 24 rami (MRP) was found to be variable.

I. Introduction

Mandible is the only movable bone in the facial skeleton. Mandibular abnormalities, its fractures in vehicular accidents or direct violence are more common. In majority of cases they occur in the ramus of the mandible. Mandibular ramus is quadrilateral in shape and has two surfaces, four borders and two processes. The medial surface presents in the centre a foremen. This foremen called mandibular foremen. This Mandibular foramen contains neurovascular bundle formed by the inferior alveolar nerve and vessels. This foremen leads into a canal, inferior alveolar canal in the body of the mandible. Anteromedially the foremen is overlapped by a thin boney triangular lingula.

Ramus provide a large area for the attachment of the masseter muscle. As the understanding of surgical anatomy of mandibular ramus increased it lead to the advent of surgical ramal osteotomies. For the correction of mandibular deformities and treatment of ramal fractures.

At present access to ramus is exclusively via trans-oral approach. In osteotomy procedures the mandibular ramus is approached from the external surface. So it becomes important to know exactly where the bone cut should made to avoid transaction of the inferior alveolar neurovascular bundle, which lies on the medial side of the ramus which may lead to permanent sensory loss and paralysis to muscles, mylohyoid and ant belly of digastrics.

Various anatomical land marks have been proposed to guide the surgeons in locating the mandibular foremen. Caldwell and Letterman 1954 [1] made reference of a boney prominence or Antilingula present occasionally on the lateral surface of the ramus, coinciding the mandibular foremen on the medial surface. Alling (1961)[2] described a boney bulge on the lateral ramal surface coinciding mandibular foramen. Thoma (1961)[3] Described a small elevation on the surface of bone for the localisation of the foremen. Hall et. al(1975)[4] described a tubercle signifying the location of the foremen.

Grays Anatomy 38 Edition do not have any mention about these boney prominences. Gross study of the mandibles show lots of variations in relation to the position of lingula to antilingula or prominence on lateral surface of mandibular ramus[5].

The bony prominence or antilingula has been found to be variable in position in number of mandibles studied. These were not well marked in female and young mandibles, so it is with experience only the surgeons makeout the position of the mandibular foremen.

Therefore a new point, Mid-ramal point was found on the lateral ramal surface, representing the mandibular foremen on the medial side.

The purpose of the present study was to take midramal point as an alternative to the antilingula and other landmarks in relation to mandibular foremen in mandibular surgeries, which seems to be more reliable in locating the mandibular foremen. This point was formed by joining the four midpoints of the lines from, anterior, posterior, superior borders of the mandible. This point was marked on both surfaces of the mandible.

II. Material And Methods

In the present study 50 dried adult human (Males and Females) dentulous mandibles were collected from the Department of Human Anatomy of National Dental College and Sri Sukhmani Dental College Derabassi (Punjab) north India. Each mandible was assigned numbers from 1 to 50 with partially or fully erupted third molar tooth. The mental foramen is present midway between superior and inferior border of body of the mandible. Very young and broken mandibles were excluded from the study.

Material used: 1) 50 Dried Mandibles 2).Divider 3).Measuring scale 4). Temporary Black marker 5). Digital caliper 6). Panoramic X-Rays (Kodak) 7). Lead foil 8). Lead points 9). Glue 10). Scissors 11). X-ray viewing box 12). Wooden stand.

Methods: each mandible was assessed as follows; ramus was inspected and palpated with fingers for lateral ramal prominence points and lines of measurements

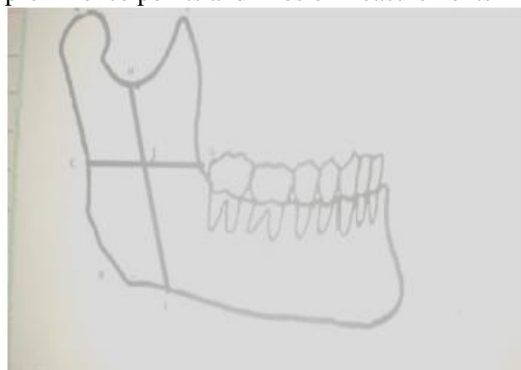
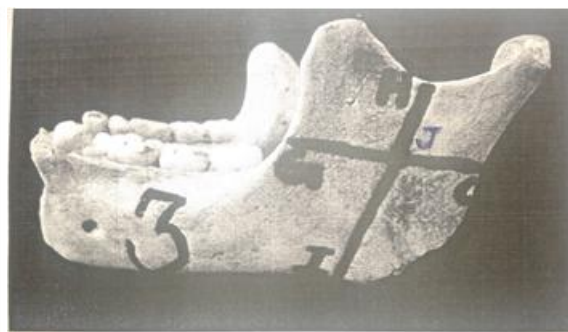
Fig 1-Points and positions on the lateral surface of ramus to locate midramal point



Photograph No.1. showing the marking on the lateral side of ramus. The point of intersection between the two lines is the midramal point.

Were used to locate the Midramal point.

These points were marked as follows: Point A- uppermost point of the condylar process.

Point B: most prominent point on the angle of the mandible.

Point C: Mid point of A and B on the posterior border Ramus.

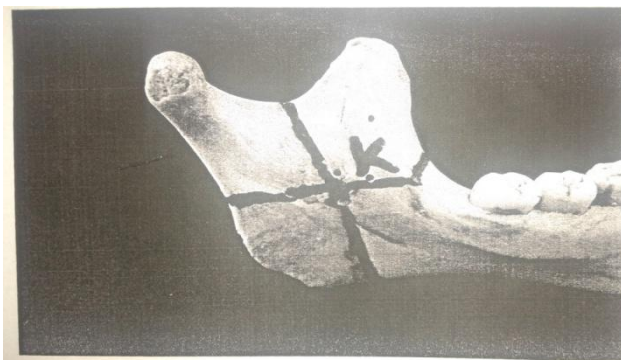
Point E: Most prominent uppermost point on the coronoid process.

Point G: A line drawn from point C to reach the posterior border of last molar tooth.

Point H: The most inferior point at the sigmoid notch on the superior border of Ramus.

Point I: A perpendicular from Point H parallel to posterior border which end at the lower border.

Point J: This point was obtained at the intersection of points H I and C G on the lateral surface of the ramus this point is called as (Mid Ramal Point). Similarly point K was marked on the medial surface of the ramus at the entrance of the mandibular foramen and inference drawn for radiographic analysis. Lead marker were cut into triangular shapes and glued to the points C, G, H and I. mid ramal point was marked at J with a square lead marker. A needle of 23 gauge was bent and placed into the mandibular canal with entrance worked by rolling the middle on at one end.



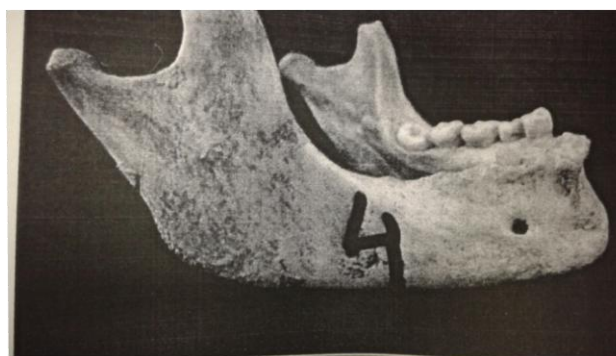
Photograph No.2 showing the medial surface of ramus. Point K is point of intersection between the two lines and represents the midramal point on the medial.

After marking all these points and needle is placed on custom wooden stand. Same stand was used to take all the X-Rays to help the error to minimum. Point J was marked and located on the x ray and its correlation with respect to Mandibular foramen was measured calculated and recorded. The difference between point J and point K with respect to Mandibular foramen were measured and recorded.

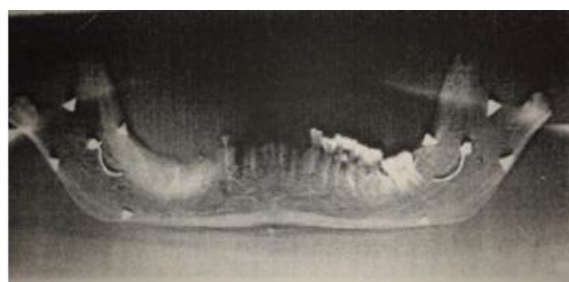
All the measurements were calculated and statistically analysed taking into consideration the elongation factor of 1.2 as calculated in the user manual of the OPG machine. Significant Correlation coefficients were obtained from all measurement of right and left rami.

Observations: The rami of all 50 mandibles were inspected and palpated on both the sides. The ramal prominence or rough ridge seemed to be not uniform in position and size.

In about 30 the ridge was faint or least marked. In 34 rami ridge was prominent extensive and also uneven which is covered almost 1/3 rd of the lateral surface of ramus and did not give impression of exact location of so called antilingula. The roughened surface seemed to be result of more frequent use of masseter muscle while chewing. In 36 rami there was a prominence on the lateral side of the mandible which was placed near the posterior border of the ramus. The position was also variable not having any constant position. So the distance of the lateral prominence (lingula) from anterior, posterior and superior borders could not be measured. The lateral ramal prominence was absent in 30% of mandible and prominent and extensive in 34% and in them posteriorly placed in 33% mandible.



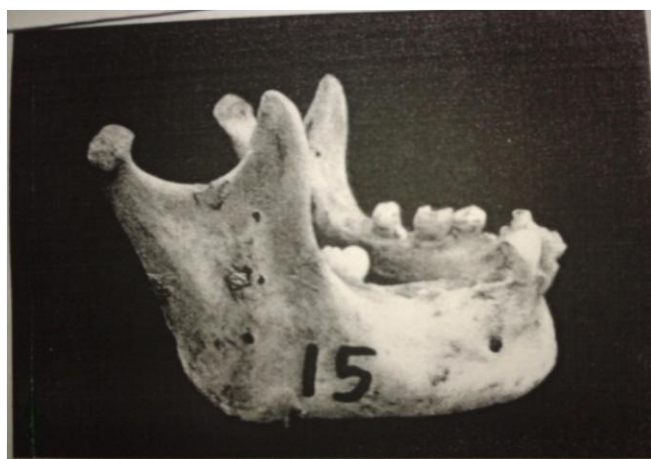
Photograph no.3. showing lead marker placed on points C,G,H and I to locate Midramal point.




Photograph no .3a. showing the panoramic X-ray of the mandible with lead marker placed. There is complete overlapping of the Mandibular foramen with Midramal point in the X-ray.

Mid Ramal Point (MRP) an Anatomical Landmark to Mandibular Foramen on Lateral Ramal Surface

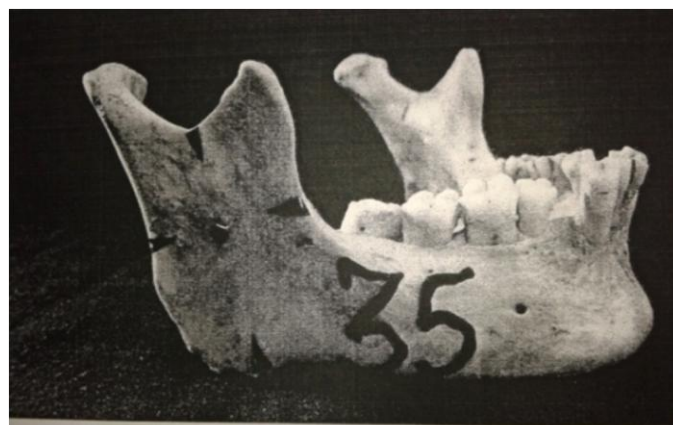During the radiographic assessment of measurement between point J and mandibular foremen (MF) the measurements between below 1mm could not be made because of the overlapping of the two markers points on radiograph. There were 24 rami showing variations between point J (Mid ramal point) and mandibular foramen. On gross assessment just a pin point mark was used to locate mid ramal point. Digital caliper device was used to measure the distance between point K and the entrance of mandibular foramen. Difference as presie as 0.5mm were measured using the digital caliper. Difference between the radiographic and gross assessment of point J (MRP) at lateral surface of the ramua and point K on medial surface, were made with mandibular foramen. It was found to be concordance with the elongation factor. In the rami or 24 mandibles mid ramal point (MRP) was as follows 10(Anterosuperior) 9(Anteroinferior) 1 (Posterosuperior) 2 (Posteroinferior) & 2 Superior and Anterior to the mandibular foramen. On percentage chart it was 47 .1%, 37.5%, 4.1%, 8.2%, 3.1 respectively



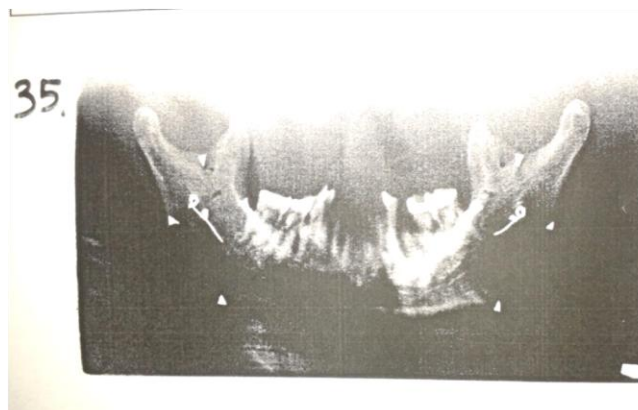
Photograph no 5 showing mandible no.15 with lead markers placed.



Photograph no.5 (b) showing panoramic radiograph of mandible no.15. the midramal point is placed anterosuperiorly with respect to Mandibular foramen bilaterally.



Photograph No.5 showing mandible no.35 lead markers are placed



Photograph No.5(A) showing panoramic radiograph Of mandible no.35. the mid Ramal point is located anteroinferiorly with respect to Mandibular foramen.

The mean average distance of mid ramal point with respect to mandibular foramen in superior and inferior direction was 4.3 and 3.3mm respectively, variations in posterior of J among 100 samples

Table no1. Position of point J in relation to Mandibular foramen (MF) in mandibles showing variations between.

Anterosuperiorly	Anteroinferiorly	Posterosuperiorly	Posteroinferiorly	Superiorly
Mand .no.3 (Bil)	Mand. No. 12(Bil)	Mand.no 41(R)	Mand.no. 36(Bil)	Mand no.5 (R)
Mand .no.7 (Bil)	Mand. No. 29 (L)			Mand no. 21(R)
Mand .no.15 (Bil)	Mand. No. 33 (R)			
Mand .no.17 (L)	Mand. No. 35 (Bil)			
Mand .no.27 (Bil)	Mand .no .44 (R)			
Mand .no.41 (L)	Mand.no.49 (Bil)			

In rest of the mandibles there were in complete concordance between point J and Mandibular foramen (MF).

Distribution percentage among the variation among the variation of point J (midramal) with respect to Mandibular foramen.

- A. Antereosuperiorly placed point J with respect to Mandibular foramen = $10/24 \times 100 = 41.7\%$
- B. Anteroinferiorly placed point J with respect to Mandibular foramen = $9/24 \times 100 = 37.5\%$
- C. Posterosuperiorly placed point J with respect to Mandibular foramen = $1/24 \times 100 = 4.1\%$
- D. Posteroinferiorly placed point J with respect to Mandibular foramen = $2/24 \times 100 = 8.2\%$

Mean variations of Midramal point with respect to Mandibular foramen

A. Mean average distance in superior direction

$$\frac{3 + 1 + 4 + 8 + 3 + 8 + 5 + 6 + 5 + 5 + 3 + 6 + 2 + 4 + 3 + 3}{16} = 4.3\text{mms}$$

B. Mean average distance in anterior direction

$$\frac{2 + 2 + 2 + 3 + 4 + 4 + 4 + 4 + 3 + 2 + 3 + 8 + 4 + 3 + 3 + 2 + 4 + 4 + 3}{19} = 3.3\text{mms}$$

The mean average distance of Midramal point with respect to Mandibular foramen in superior and anterior directions are 4.3mm and 3.3mm respectively.

III. Discussion

in 1976 Yates, Olson and Guralnik, in anatomical study examined 70 dried mandibles and found that only 44% of mandibles showed presence of antilingula or ramal prominences on the lateral surface. In rest of 56% of cases it was either absent or variable in relation to mandibular foramen. These studies are more or less in

Mid Ramal Point (MRP) an Anatomical Landmark to Mandibular Foramen on Lateral Ramal Surface

accordance with the present study done on 50 mandibles. In 1993 marton et al were able to identify the antilingula only in 42% of the mandibles. This number was similar to Yates et al. this was also in accordance with the present study where we were able to find this relationship only in 36% of specimen. In recent anatomical studies certain authors discredited the use of antilingula as landmark in ramal surgeries as there was lack of its predictable relation to the mandibular foramen.

After reviewing the literature it seems clear that the lateral ramal prominences or antilingula are not related to the mandibular foramen on the medial side of the ramus.

What could explain the variable presence of these prominences on the lateral ramal surface anatomically, it is suggested that the deep head of the masseter muscle attachment and the chewing habits which strengthened the muscle tone hence give firm attachment of the muscle to the bone. The reason why the features or prominences are more marked in male muscular mandibles than female and young ones.

To overcome the limitations of antilingula or lateral ramal prominence, there have been several attempts to find the alternative to these bony prominences in locating mandibular foramen. Among these the mid waist point on the lateral side of the ramus was by Martone(1993) for the locate of the mandibular foramen on the medial side. This was found to be only 46% accurate. This point was taken as mid way of the line from sigmoid notch to the base of the mandible.

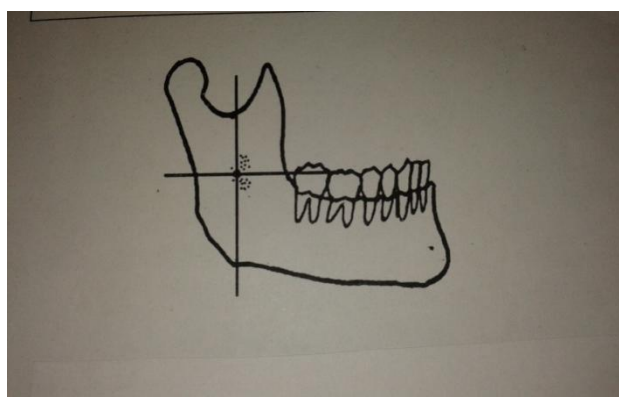
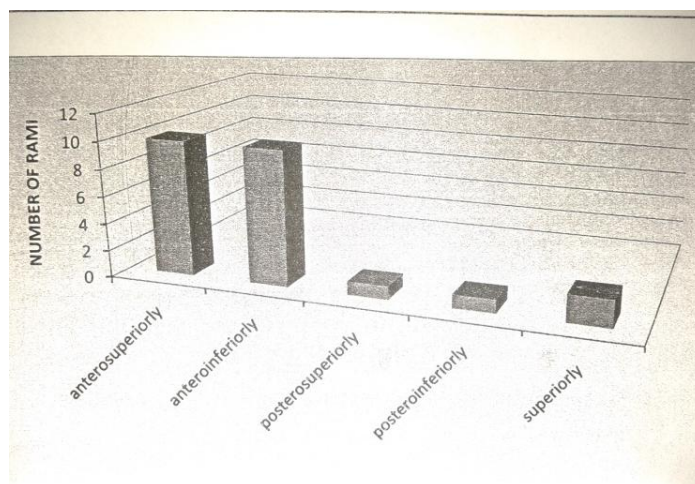


Fig no.2 dotted representation of the placement of MIDRAMAL point with respect to Mandibular foremen

Mid ramal point was formed by joining the four lines from the midpoint of anterior, posterior, superior, and inferior borders of the mandible. The point where all these lines meet was called as MID RAMAL POINT (MRP). THIS POINT Was marked on both surfaces of the mandibular rami which was measured in relation to mandibular foramen on gross study clinically and radiographically. It is also suggested that for oral surge eons during ramal osteotomies mid ramal point can be located by joining the 1) inferior point on the sigmoid notch and 2) anterior border of ramus just behind the third molar tooth (Mid point of anterior border) with the 3) Mid point of posterior border of the mandible.



Graph Bar showing variations in position of point J among 100 samples.

In the present study it was found that 76 out 100 mandibles Midramal point (MRP) coincided with the mandibular foremen where as in 24 rami (MRP) was found to be variable.

Taking into consideration all these observations and results, it is suggested the Osteotomy cut should be placed just posterior and superior to the mid ramal point to avoid injury to inferior alveolar vessels and nerves, entering the mandibular foramen. Therefore Mid ramal point provides most accurate landmark to locate the antilingula, lateral ramal prominence or mid waist point. the accuracy being 76% in MRP to 42% and 45% in antilingula and mid waist point respectively.

Summery and conclusion: the anatomical and surgical relationship of the mandibular foramen present on the medial ramal surface was studied in the present study. Earlier studies have been done on different land marks like antilingula ramal tuberosity, ramal tubercle mid waist point etc as a stable landmark for the location of mandibular foramen on the medial surface, to prevent damage to neurovascular bundle during surgical procedures.

In our study done on 50 human mandibles it was found the mid ramal point is the most accurate landmark compared to antilingula and mid waist point. The present study was carried on 50 dried human mandibles, taking the radiographs of mandible with lead marker placed on reference points and measurements were done using digital caliper device. After going through literature there have been different opinions about the different bony land marks on the lateral surface. In all these cases including where all depends upon the experience of surgeon to imagine and locate the mandibular foramen during ramal surgeries

So keeping these things in mind a new land mark Mid Ramal Point was found to during the study for locating the mandibular foramen. This point is located at the intersection of two lines one from deeper point on sigmoid notch going parallel to posterior border to meet the inferior border of the body of the mandible. Second line from the midpoint on anterior border or posterior to third molar tooth going back to meet the posterior border of the mandible.

This Midramal point coincides with the Mandibular foramen in 74% of cases, which was confirmed after taking panoramic X-Rays of the mandibles, few of the mandibles also showed minimal variations. So according to present study, Mid Ramal point (MRP) can be made as a permanent landmark for exact location of Mandibular foramen on lateral ramal surface.

Referances

- [1]. Alling CC : Mandibular Prognathism: J. oral Surgery;1996,14:3-22.
- [2]. Bell et al. Surgical correction of Dentofacial deformities. Philadelphia;1980:855-901.
- [3]. Cold Well and Latterman. Vertical Osteotomies in correction of prognathism;1954,12:185-202
- [4]. Gabriel AC. Some Anatomical features of Mandible. J. Anat;1958,92:580.
- [5]. Greys Anatomy: skull and mandible;31st edition:480-2.
- [6]. Martone et al. Dimorphic study of Surgical Anatomical landmarks of Mandible. Oral Surg Oral Med. Oral Path;1993,75(4):436-38.
- [7]. Thoma F. Position of Mandibular canal. J Oral Maxillofacial surg;1987,16:65-69.
- [8]. Yates Olson Guralnik. Antilingula as an Anatomical land mark. J. Oral surg;1976:705-9.